

Periodic Paralysis: An Uncommon Complication of Primary Aldosteronism

***Ricardo M. Costa de Freitas
Alexandre Sampaio Moura***

*Enfermaria de Clínica Médica
(RMCF) e Unidade de Pronto
Atendimento (ASM), Santa Casa
de Belo Horizonte, MG.*

*Recebido em 03/06/03
Revisado em 13/10/03
Aceito em 14/10/03*

ABSTRACT

Periodic paralysis is an uncommon complication of primary aldosteronism in the non-Asian population. We describe the case of a Brazilian woman who presented to the emergency room with proximal symmetric tetraparesis that was later diagnosed as primary aldosteronism. This case report shows that primary aldosteronism should be included in the differential diagnosis of periodic paralysis, especially among hypertensive patients. (**Arq Bras Endocrinol Metab 2003;47/6:744-747**)

Keywords: Primary aldosteronism; Symmetric tetraparesis; Periodic paralysis; Metabolic myopathy

RESUMO

Paralisia Periódica: Uma Complicação Incomum do Hiperaldosteronismo Primário.

A paralisia periódica é uma complicação rara do aldosteronismo primário na população não asiática. Nós relatamos o caso de uma mulher brasileira que se apresentou à unidade de emergência com tetraparesia proximal simétrica e recebeu posteriormente o diagnóstico de aldosteronismo primário. Este relato de caso mostra que o aldosteronismo primário deve ser incluído no diagnóstico diferencial da paralisia periódica, especialmente entre pacientes hipertensos. (**Arq Bras Endocrinol Metab 2003;47/6:744-747**)

Descritores: Aldosteronismo primário; Miopatia metabólica; Paralisia periódica; Tetraparesia simétrica

THIS CASE REPORT DESCRIBES a patient with an uncommon and potentially severe manifestation of primary aldosteronism that is the proximal symmetric tetraparesis due to a metabolic myopathy secondary to hypokalemia.

CASE PRESENTATION

A 36-year-old female born and living in Belo Horizonte, Minas Gerais, Brazil, presented to the emergency room of the Santa Casa Hospital in Belo Horizonte in February 2000 complaining of paresthesia in her upper and lower limbs for about a week, that worsened in the last 24 hours. She also had proximal muscle weakness and could barely climb stairs or perform simple movements like combing her hair. She had been diagnosed with arterial hypertension two weeks before admission and was taking hydrochlorothiazide 25mg/day. She denied other symptoms or previous hospitalizations and informed smoking five cigarettes/day and mild alcohol consumption.

Her physical examination showed no abnormalities except for a systolic heart murmur II/VI. Blood pressure was 150/100mmHg, the pulse rate 80bpm and the respiratory rate 8mpm.

Serum potassium levels were 2.0mEq/L, total creatine-kinase (total CK) was 36,540U/L (normal range [NR]: 26-165), AST was 1,522U/L (NR: 8-39), ALT was 461U/L (NR: 8-31), and aldolase was 330UI/L (NR: 3-7). Serum measurements of urea, creatinine, bilirubins, alkaline phosphatase, glucose, magnesium, calcium, chloride and sodium, as well as the complete blood cell count (CBC) were within normal limits.

Arterial blood gases showed metabolic alkalosis with partial compensatory respiratory acidosis (pH 7.47; pCO₂ 39mmHg; pO₂ 90mmHg; HCO₃ 29.3mEq/L; base excess +5.9 and satO₂ 97.5%). Urinalysis was normal including measurements of 24h-urine excretion of sodium and potassium, and creatinine clearance. The ECG revealed a sinus rhythm and presence of U waves. Echocardiogram and chest X-rays were normal.

Electromyography of upper limbs was normal and deltoid muscle biopsy showed necrotic areas and myofibrils degeneration without inflammatory evidence. These findings were consistent with the diagnosis of a primary myopathy (figure 1a).

The levels of plasma and 24h-urine aldosterone were increased with values of 23.3ng/dL (NR: 4-14ng/dL) and 26.2ug/24h (NR: 5-14ug/24h), respectively, and plasma renin activity was reduced to 0.1ng/mL/h (NR: 0.3-1.6ng/mL/h). An abdominal ultrasonography (US) showed a nodular, hypoechogenic image measuring 19mm with well-defined borders in the topography of the right adrenal gland (figure 2a). An adrenal CT revealed the presence of a small mass with soft tissue density with regular and well-defined borders, measuring about 2.0x1.1cm, with no contrast enhancement, located in the right adrenal. The left adrenal was normal (figure 2b).

After admission, the patient received IV potassium replacement and serum potassium levels stabilized between 2.0 and 3.5mEq/L. The symptoms relieved and the patient became asymptomatic after 3 days. Oral potassium replacement was substituted for the IV replacement and spironolactone 100mg/day was added. The total CK, aldolase and transaminases levels decreased progressively and became normal in 3 weeks. The patient was discharged asymptomatic with normal potassium levels and mild arterial hypertension using captopril 25mg TID, oral KCl 10mgTID, and spironolactone 100mg/day. After an 8-wk use of spironolactone, potassium levels remained normal and the patient underwent a right adrenalectomy. Patho-

logical findings revealed a 1.8cm nodule. Microscopical evaluation showed predominance of lipid-laden cortical cells with no areas of anaplasia, necrosis and neither capsule nor vessels invasion (figure 1b). The patient recovered well and both potassium and blood pressure levels stabilized within the normal ranges after progressive tapering of the medication in use.

DISCUSSION

Primary aldosteronism is seldom the cause of systemic arterial hypertension being responsible for about 2% of the total of cases in unselected patients (1). The aldosterone-producing adrenal adenoma (APA) is the main cause of primary aldosteronism (1) and should always be ruled out in hypokalemic hypertensive patients. The clinical manifestations of primary aldosteronism include arterial hypertension, muscle weakness, paresthesia, headache, polyuria and polydipsia (1,2). This case report describes an uncommon initial presentation of primary aldosteronism that is the symmetric proximal tetraparesis. The symptom probably resulted from severe hypokalemia that was possibly accentuated by the use of hydrochlorothiazide. Muscular weakness was totally reversed following interruption of the anti-hypertensive drugs and potassium replacement.

Most cases of the syndrome of hypokalemic paralysis is due to familial or primary hypokalemic periodic paralysis and sporadic cases are related with other conditions such as hyperthyroidism, renal disorders, barium poisoning, gastrointestinal potassium losses and endocrinopathies. The clinical investigation is helpful in identifying the cause of hypokalemic paralysis (3).

Proximal symmetric tetraparesis as a manifestation of primary aldosteronism has not been frequently reported in the literature and seems to be more common in Asia, especially in China and Taiwan, than elsewhere (1). According to Ma et al (4), Chinese patients with primary aldosteronism were notable for periodic paralysis as one of the dominant presenting symptoms. In their series of 50 cases, the mean age of the subjects was 40.2 years. The commonest symptom was muscle weakness (54%), followed by periodic paralysis (42%). There were no known precipitating events such as exercise or food intake. The limb muscles, especially those of the legs, were most commonly affected. In that study, it was not clear why those Chinese patients with primary aldosteronism had a serum potassium level lower than other ethnic groups. It did not appear to be related to the duration of hypertension before

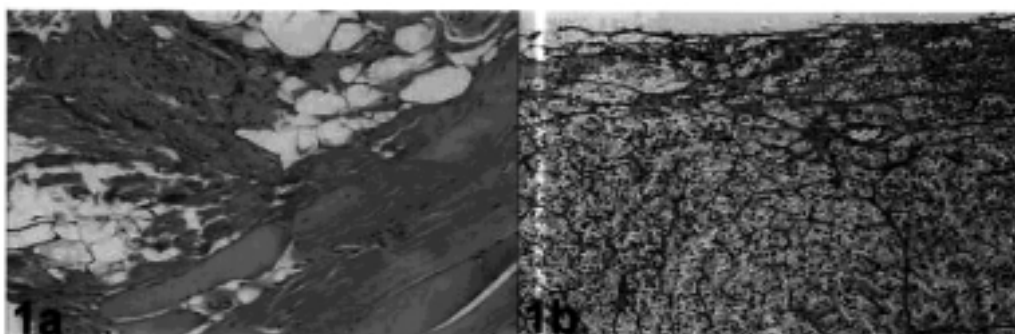


Figure 1. Microscopy evaluation of the deltoid muscle showing primary myopathy (1a) and excised adrenal tumor with findings consistent with an adenoma (1b) – see text for details.

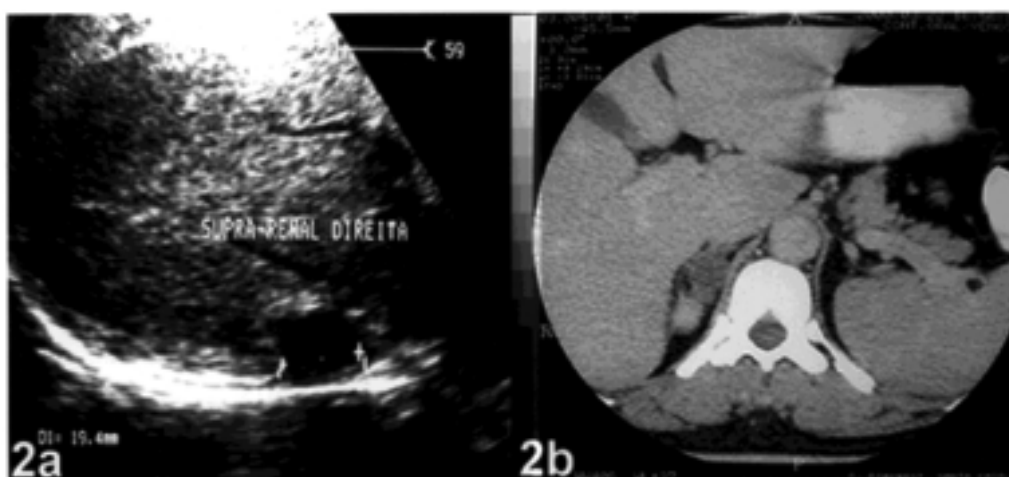


Figure 2. Abdominal US (2a) and CT scan (2b) of the right adrenal gland identifying the aldosterone-producing tumor.

the diagnosis of primary aldosteronism. No correlation was found between the severity of hypokalemia and the size of the adenoma or the level of urinary aldosterone excretion.

In Taiwan, Huang et al (5) showed that 21 (49%) out of 43 cases of primary aldosteronism presented with muscular paralysis as the initial symptom. They also showed that the serum potassium level of those with muscular paralysis was significantly lower than of those without it.

The differential diagnosis of primary aldosteronism includes APA, bilateral adrenal hyperplasia and less frequently glucocorticoid-suppressible hyperaldosteronism and adrenal carcinoma. Measurement of plasma 18-hydroxycorticosterone and assessment of changes in aldosterone levels after corticotropin administration or after changing from supine to erect position might be helpful in defining the specific etiology (6).

Imaging studies should be performed after the initial biochemical analysis. Over 20% of adrenal adenomas are less than 1cm in diameter and difficult to detect (7). Although US may reveal adrenal masses, CT scanning is the method of choice for the initial characterization of an adrenal mass with an overall sensitivity greater than 90% (2). A non-enhanced examination should be performed followed by a contrast-enhanced study if necessary (8). MR imaging has been considered a specific test for detection of adrenal adenomas, with sensitivity of 70%, specificity of 100% and accuracy of 85%, comparable to that reported with CT (9).

Adrenal cortical scintigraphy is rarely needed, given the improvements in CT technology, but it can be useful to determine whether the abnormality is unilateral or bilateral (10). Iodine-131 6-beta-iodomethyl-19-norcholesterol (NP-59) can be used to

detect aldosteronomas and other hyperfunctioning cortical tumors. It is still considered investigational by the U.S. Food and Drug Administration despite many years of safe use (8).

In summary, periodic paralysis seems to be a rare event among non-Asian patients with primary aldosteronism. However, this possibility must be raised in patients with hypertension associated to hypokalemia and those with severe hypertension (1,6). Appropriate biochemical and imaging studies need to be carried out to avoid misdiagnosis (11) and other causes of myopathies should be ruled out.

REFERENCES

1. Ganguly A. Primary aldosteronism. *N Engl J Med* **1998**;339:1828-34.
2. Bravo EL. Primary aldosteronism. *Endocrinol Metab Clin North Am* **1994**;23:271-82.
3. Ahlawat SK, Sachdev A. Hypokalaemic paralysis. *Postgrad Med J* **1999**;75/882:193-7.
4. Ma JTC, Wang C, Lam KSL, et al. Fifty cases of primary hyperaldosteronism in Hong Kong Chinese with a high frequency of periodic paralysis. Evaluation of techniques for tumour localization. *QJM New Series* **61** **1986**;235:1021-37.
5. Huang YY, Hsu BR, Tsai JS. Paralytic myopathy - a leading clinical presentation for primary aldosteronism in Taiwan. *J Clin Endocrinol Metab* **1996**;81:4038-41.
6. Stewart PM. Mineralocorticoid hypertension. *Lancet* **1999**;353:1341-6.
7. Dunnick NR, Leight GS, Robidoux MA, et al. CT in the diagnosis of primary aldosteronism: sensitivity in 29 patients. *Am J Roentgenol* **1993**;160:321-4.
8. Mayo-Smith WW, Boland GW, Noto RB, Lee MJ. State-of-the-art adrenal imaging. *Radiographics* **2001**;21:995-1012.
9. Sohaib SA, Peppercorn PD, Allan C, et al. Primary hyperaldosteronism (Conn Syndrome): MR imaging findings. *Radiology* **2000**;214:527-31.
10. Ikeda DM, Francis IR, Glazer GM, et al. The detection of adrenal tumors and hyperplasia in patients with primary aldosteronism: comparison of scintigraphy, CT and MR imaging. *Am J Roentgenol* **1989**;153:301-6.
11. Gordon RD, Stowasser M, Rutherford JC. Primary aldosteronism: are we diagnosing and operating on too few patients? *World J Surg* **2001**;25:941-7.

Endereço para correspondência:

Ricardo Miguel Costa de Freitas
Rua Santo Antônio do Monte, 386
30330-220 Belo Horizonte, MG