

Importance of ^{99m}Tc -sestaMIBI thyroid scan in a case of amiodarone-induced thyrotoxicosis

A importância da cintigrafia tiroidea com ^{99m}Tc -sestaMIBI num caso de tireotoxicose induzida pela amiodarona

Selma B. Souto^{1,2}, Helder Fernandes³, Maria João Matos^{1,2}, Daniel Carvalho Braga^{1,2}, Jorge Pereira³, Davide Carvalho^{1,2}

SUMMARY

Amiodarone (AM)-induced thyrotoxicosis (AIT) is a condition with uncertainties from the diagnostic and therapeutic standpoints. A 54-year old male was referred to the hospital due to thyrotoxicosis. He had history of atrial fibrillation medicated with AM. No history of pre-existing thyroid disease was present, thyroid palpation revealed no goiter, and there were no signs of Graves' ophthalmopathy. Thyroid autoantibodies and thyroid-stimulating hormone receptor antibodies (TRABs) were negative. Thyroid and Doppler ultrasounds were normal. ^{99m}Tc -sestaMIBI thyroid scan (STS) showed uptake with rapid washout. AM therapy was discontinued, and combined therapy was started. After a long course of glucocorticoid and thionamides, the patient became euthyroid. It is necessary to distinguish between the types of AIT to decide whether or not continue AM treatment; after that, the appropriate therapy should be selected. STS was very important in the diagnosis of the type of AIT. *Arq Bras Endocrinol Metab.* 2011;55(7):486-9

SUMÁRIO

A tireotoxicose induzida por amiodarona (AIT) é uma condição incerta do ponto de vista de diagnóstico e tratamento. Um homem de 54 anos de idade foi encaminhado ao hospital devido à tireotoxicose. Ele apresentou um histórico de fibrilação atrial medicada com amiodarona (AM). Não havia histórico de doença da tiroide preexistente, a palpação da tiroide não revelou bócio e não havia sinais de oftalmopatia de Graves. Os autoanticorpos contra a tiroide e anticorpos para os receptores de hormônio estimulante da tiroide (TRABs) foram negativos. Os resultados do ultrassom da tiroide e do exame de Doppler foram normais. A cintigrafia da tiroide com ^{99m}Tc -sestaMIBI mostrou captação com rápida eliminação. O tratamento com AM foi descontinuado, e se iniciou a terapia combinada. Após um longo tratamento com glicocorticoides e tionaminas, o paciente se tornou eutiroide. É necessário distinguir entre os tipos de AIT para se determinar a continuação ou interrupção do tratamento com AM. Depois disso, o tratamento apropriado deve ser selecionado. A STS é muito importante no diagnóstico do tipo de AIT. *Arq Bras Endocrinol Metab.* 2011;55(7):486-9

¹ Department of Endocrinology, Diabetes and Metabolism, Centro Hospitalar S. João, Porto, Portugal
² School of Medicine, University of Porto, Porto, Portugal
³ Department of Nuclear Medicine, Centro Hospitalar S. João, Porto, Portugal

Correspondence to:

Selma B. Souto
Department of Endocrinology, Diabetes and Metabolism, Centro Hospitalar S. João, Alameda Prof. Hernâni Monteiro, 4200-319 – Porto, Portugal
sbsouto.md@gmail.com

Received on June/12/2011
Accepted on Oct/24/2011

INTRODUCTION

Amiodarone (AM) is a benzofuranic iodine-rich antiarrhythmic agent (1). In 15%-20% of cases, treatment is complicated by thyroid dysfunction, either thyrotoxicosis or hypothyroidism (2). Amiodarone-induced thyrotoxicosis (AIT) is more frequent in iodine

deficient areas, whereas hypothyroidism is more frequent in iodine-sufficient areas (2).

AIT is a clinical condition with uncertainties from the diagnostic and therapeutic standpoints. It can be classified as Type 1, present in patients with pre-existing or latent thyroid disorders, such as diffuse or nodular

goiter or latent Graves' disease. This type of the disorder is caused by unregulated thyroid hormone synthesis, and it is treated with thionamides and potassium perchlorate. Type 2 usually occurs in patients with previous normal thyroid gland or small goiter, and it is caused by the release of preformed hormone by inflammatory destruction of the thyroid gland. It is treated with glucocorticoids. Type 3, the indeterminate or mixed type, is caused by both pathogenic mechanisms, and managed with combined therapy (2).

The distinction between the three types is crucial to characterize the disease from a pathophysiological standpoint, and to decide whether to suspend AM treatment. AIT type 2 is by far the most frequent form, possibly due to the avoidance of AM therapy, if feasible, in patients with pre-existing thyroid diseases (3).

Color flow Doppler ultrasound (CFD) is a noninvasive technique that shows intrathyroidal blood flow, and provides real-time information on thyroid morphology and hyperfunction (4). Bogazzi and cols. showed that CFD is a valuable tool for quick differentiation between the two types of AIT.

Piga and cols. have reported the usefulness of ^{99m}Tc -sestaMIBI thyroid scan (STS) in the differential diagnosis of AIT (5). ^{99m}Tc -sestaMIBI is a lipophilic monovalent cation with increased uptake in epithelial cells containing high number of mitochondria. Increased retention of MIBI is therefore employed to detect hyperfunctioning parathyroid tissue, and may be observed in benign or malignant thyroid tumors. Increased MIBI retention has also been described in hyperfunctioning thyroid tissue, and this phenomenon is believed to be the consequence of the increased number of mitochondria in hypermetabolic cells. On the other hand, MIBI accumulation is reduced or absent in apoptotic or necrotic processes involving collapse of mitochondrial membrane potential. The authors found a clear MIBI diffuse retention in AIT type 1, no significant uptake in AIT type 2; and faint, persistent uptake, with rapid washout (within 10 minutes) in AIT type 3.

We describe the importance of STS in the differential diagnosis of the type of AIT in a patient that became euthyroid after a long course of glucocorticoid and thionamide therapy.

CASE REPORT

A 54-year old male was referred to our department due to thyrotoxicosis [TSH - 0.152 $\mu\text{UI}/\text{mL}$ (0.35-

4.94); FT₄ - 1.94 ng/mL (0.70-1.48)]. The patient had a 4-year history of atrial fibrillation medicated with oral AM 200 mg/day. He also had coronary disease (myocardial infarction 5 years earlier), hypertension, dyslipidemia and sleep apnea; he was under therapy with rosuvastatin 10 mg id, isosorbide mononitrate 60 mg id, amlodipine besylate 5 mg id, perindopril 5 mg id, aspirin 100 mg id, and warfarin. He had no history of previous thyroid disease. He complained of palpitations and had a few episodes of tachycardic atrial fibrillation in the previous 3-4 weeks, without other symptoms of thyrotoxicosis. Neither iodine-containing contrast agents, nor other drugs containing iodine had been recently administered. His thyroid palpation was unremarkable. He had no signs of Graves' ophthalmopathy or dermopathy. His family history was negative for thyroid diseases.

In the first visit, thyroid function tests were repeated: FT₃: 4.19 ng/mL (1.71-3.71), FT₄: 2.17 ng/mL (0.70-1.48), and TSH: 0.005 $\mu\text{UI}/\text{mL}$ (0.35-4.94). Thyroid autoantibodies and TRABs were negative. Thyroid ultrasound revealed normal-sized thyroid gland ([right lobe: 16 x 17 x 40 mm (WxAPxL); left lobe: 16 x 15 x 41 mm (WxAPxL)], and absent vascularization in the CFD (pattern 0). By that time, all the tests performed were point out to AIT type 2. A STS scan was performed, and showed uptake with rapid washout, consistent with AIT type 3, or mixed form (Figure 1).

AM therapy was discontinued, and prednisone (40 mg/day) and metimazole (15 mg/day) treatment was started (Table 1). Thyroid function tests were repeated fifteen days after that, and the patient had an increase in FT₃ and FT₄, whereas TSH was still suppressed. The dose of metimazole was increased to 40 mg/day. FT₃ and FT₄ returned to normal ranges four months after that, and the patient had no episodes of atrial fibrillation. After six months of combined therapy (metimazole 40 mg/d and prednisone 40 mg/d), the patient became euthyroid; metimazole was discontinued, and prednisone was withdrawn. One year after the initial therapy, the patient remained euthyroid and was negative for thyroid antibodies; however goiter was revealed on physical examination, and the thyroid ultrasound showed nodular goiter [right lobe: 22 x 25 x 54 mm (WxAPxL); left lobe: 23 x 23 x 55 mm (WxAPxL); isthmus 4 mm], with two nodules of 5 and 9 mm in diameter.

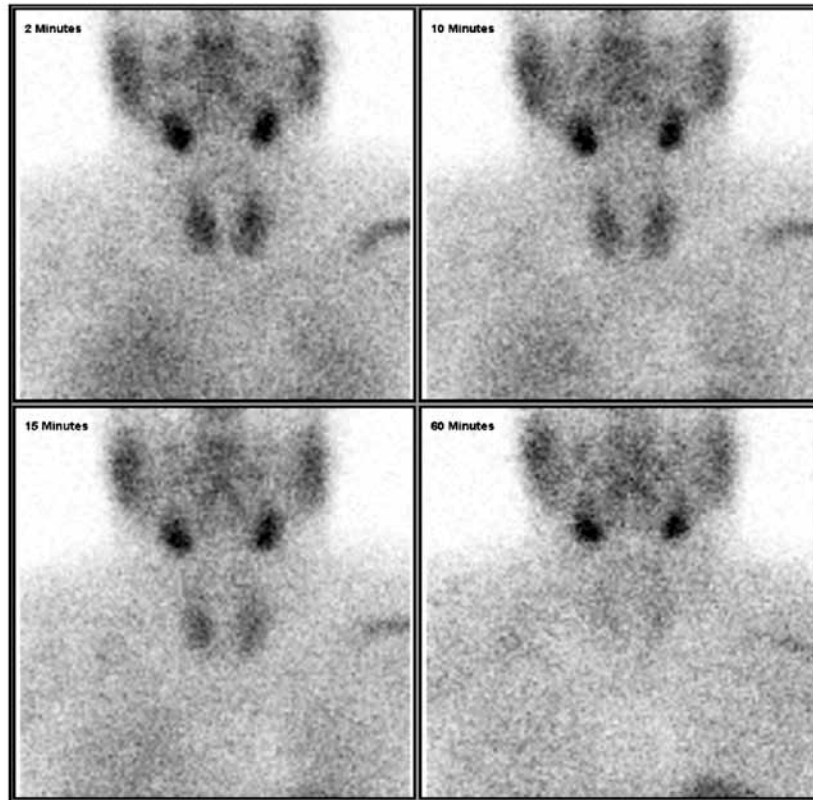


Figure 1. ^{99m}Tc -sestaMIBI thyroid scan: uptake with rapid washout.

Table 1. Parameters of thyroid function, treatment and clinical evolution

	0	15 days	2 months	4 months	6 months	8 months	1 year
FT ₃ (ng/mL) (1.71-3.71)	4.19	4.67	3.90	2.18	2.99	3.15	3.20
FT ₄ (ng/mL) (0.70-1.48)	2.17	2.41	2.27	1.12	1.07	0.91	1.18
TSH (μUI/mL) (0.35-4.94)	0.005	0.002	0.003	0.16	2.78	3.67	1.23
Change in therapy							
MMI (mg)	30	40	40	30	15	0	0
PDN (mg)	40	40	40	20	10	0	0
Symptoms/signs	AF	AF	AF	-	-	-	-

MMI: metimazole; PDN: prednisone; AF: atrial fibrillation.

DISCUSSION

In patients with AIT, some of the classical symptoms of thyrotoxicosis may be masked because of AM beta-blocking activity, and because AM metabolites may block binding of T₃ to its nuclear receptor (6,7).

AIT may develop during AM therapy or even several months after drug withdrawal (6). This is because AM and its metabolites (mainly desethylAM) have a long half-life (up to 100 days) and are stored in various tissues, particularly in fat, from which they are slowly released. Accordingly, drug withdrawal might not in-

fluence the response to medical therapy in the short term, and mild cases of AIT type 2 may remit without treatment or AM withdrawal (3). The severity of the underlying cardiac disease makes discontinuation of AM treatment unattractive in many cases, because of the increased risk of worsening cardiac arrhythmias.

In the case reported here, STS was very important in the differential diagnosis of AIT. The majority of the tests performed pointed out to AIT type 2, except STS. Treatment that was initially determined was combined therapy with a high dose of glucocorticoid (prednisone

40 mg/day), and a low dose of metimazole (15 mg/day). Rapid response to therapy (within 1-2 weeks) indicates destructive thyroiditis, and thionamides may be withdrawn (8). However, after 2 weeks, an increase in free thyroid hormones was observed, and the dose of metimazole was increased to 40 mg/day, with gradual clinical and biochemical improvement. This response to therapy also suggests mixed type AIT, as shown in STS.

Thyroid ultrasound performed one year after AIT diagnosis revealed nodular goiter. The patient may possibly have already had changes in thyroid morphology by the time of diagnosis, although interpretations of thyroid US and CFD in AIT require an experienced sonographer.

In patients who are not taking AM, radioiodine uptake (RIU) is the primary test used to distinguish between destructive thyroiditis and hyperthyroidism associated with *de novo* synthesis of thyroid hormone. However, daily ingestion of 6 g or more of bioavailable iodine, together with AM, results in sufficiently high serum levels of iodine for complete tracer uptake. Therefore, the majority of patients have less than 1% uptake (9). In one European study, a significant percentage of patients with AIT type I had measurable or even elevated uptake (10).

With respect to AIT therapy, total thyroidectomy may be required in patients resistant to other treatments (3). To obtain a transient control of thyrotoxicosis before surgery, short course iopanoic acid, in association with antithyroid drugs, can be used (11). RAI has a marginal role in the management of AIT, because of low RIU values, either due to the iodine load or the destructive process (6).

CONCLUSION

In the case reported here, STS was very important in the differential diagnosis of AIT and in the therapy chosen. It is, however, a very expensive exam, and pre-

viously studied only in small populations. Larger studies are needed to propose STS as an effective tool for differential diagnosis of AIT.

Acknowledgements: the authors would like to thank Prof. Piga from the University of Cagliari for his help in reviewing the STS images.

Disclosure: no potential conflict of interest relevant to this article was reported.

REFERENCES

1. Reiffel JA, Estes NA, Waldo AL, et al. A consensus report on antiarrhythmic drug use. *Clin Cardiol.* 1994;17:103-16.
2. Bogazzi F, Bartalena L, Gasperi M, Braverman LE, Martino E. The various effects of amiodarone on thyroid function. *Thyroid.* 2001;11:511-9.
3. Bogazzi F, Bartalena L, Martino E. Approach to the patient with amiodarone-induced thyrotoxicosis. *J Clin Endocrinol Metab.* 2010;95:2529-35.
4. Bogazzi F, Bartalena L, Brogioni S, Mazzeo S, Vitti P, Burelli A, et al. Color flow Doppler sonography rapidly differentiates type I and type II amiodarone induced thyrotoxicosis. *Thyroid.* 1997;7(4):541-5.
5. Piga M, Cocco MC, Serra A, Boi F, Loy M, Mariotti S. The usefulness of 99mTc-sestaMIBI thyroid scan in the differential diagnosis and management of amiodarone-induced thyrotoxicosis. *Eur J Endocrinol.* 2008;159:423-9.
6. Martino E, Bartalena L, Bogazzi F, Braverman LE. The effects of amiodarone on the thyroid. *Endocr Rev.* 2001;22:240-54.
7. van Beeren HC, Bakker O, Wiersinga WM. Structure-function relationship of the inhibition of the 3,5,3'-triiodothyronine binding to the alpha1- and beta1-thyroid hormone receptor by amiodarone analogs. *Endocrinology.* 1996;137:2807-14.
8. Franklyn JA, Gammage MD. Treatment of amiodarone-associated thyrotoxicosis. *Nat Clin Pract Endocrinol Metab.* 2007;3:662-6.
9. Daniels GH. Amiodarone induced thyrotoxicosis. *J Clin Endocrinol Metab.* 2001;86:3-8.
10. Martino E, Bartalena L, Mariotti S, Aghini-Lombardi F, Ceccarelli C, Lippi F, et al. Radioactive iodine thyroid uptake in patients with amiodarone-iodine-induced thyroid dysfunction. *Acta Endocrinol (Copenh).* 1988;119:167-73.
11. Bogazzi F, Miccoli P, Berti P, Cosci C, Brogioni S, Aghini-Lombardi F. Preparation with iopanoic acid rapidly controls thyrotoxicosis in patients with amiodarone induced thyrotoxicosis before thyroidectomy. *Surgery.* 2002;132:1114-7.