

An uncommon case of Marine-Lenhart syndrome

Um caso incomum de síndrome de Marine-Lenhart

Giuseppe Giuffrida¹, Salvatore Giovinazzo¹, Rosaria Certo¹, Teresa Manuela Vicchio¹, Sergio Baldari², Alfredo Campenni², Rosaria Maddalena Ruggeri¹

SUMMARY

The term Marine-Lenhart syndrome describes the association between Graves' disease and autonomously functioning thyroid nodules (AFTN), such as toxic adenoma or toxic multinodular goiter. The two diseases may coexist or may be present at different moments in the same patient. In the literature, there are many reports on the development of Graves' disease after radioiodine treatment for AFTN, but very little information may be found on the occurrence of AFTN after radioiodine therapy for Graves' disease. We describe here the case of a female patient with Graves' disease who was successfully treated with radioiodine for Graves' disease, returning to normal thyroid function. Three years later, biochemical analysis and ultrasound examination identified a thyroid nodule that progressively increased in size. The ^{99m}Tc-pertechnetate scintigraphy showed avid uptake in the right lobe, which corresponded to a nodular lesion consistent with AFTN. *Arq Bras Endocrinol Metab.* 2014;58(4):398-401

SUMÁRIO

O termo "síndrome de Marine-Lenhart" descreve a associação da doença de Graves e nódulos tireoidianos de funcionamento autônomo (AFTN), como no adenoma tóxico ou bócio multinodular tóxico. As duas doenças podem coexistir ou podem estar presentes em diferentes momentos no mesmo paciente. Na literatura, existem muitos relatos sobre o desenvolvimento da doença de Graves após radioiodoterapia para AFTN, mas muito poucos dados podem ser encontrados em relação ao aparecimento de AFTN após radioiodoterapia para doença de Graves. Descrevemos o caso de uma paciente do sexo feminino com doença de Graves que realizou com sucesso o tratamento com iodo radioativo, com a normalização da função da tireoide. Três anos depois, uma análise bioquímica e um exame de ultrassonografia identificaram o aparecimento de um nódulo na tireoide que progressivamente aumentou de tamanho. A cintilografia com ^{99m}Tc-pertechnetato revelou uma captação ávida no lóbulo direito, correspondente à lesão nodular, consistente com uma AFTN. *Arq Bras Endocrinol Metab.* 2014;58(4):398-401

¹ Department of Clinical and Experimental Medicine, Unit of Endocrinology, University of Messina, Italy

² Department of Biomedical Sciences and of Morphological and Functional Images, Unit of Nuclear Medicine, University of Messina, Italy

Correspondence to:

Rosaria Maddalena Ruggeri
Dipartimento di Medicina Clinica e Sperimentale, UOC di Endocrinologia Padiglione H, 4 piano, Policlinico Universitario "G. Martino"
98125 - Messina, Italy
mruggeri@unime.it

Received on Dec/10/2013
Accepted on Mar/3/2014

DOI: 10.1590/0004-2730000003173

INTRODUCTION

Graves' disease and autonomously-functioning thyroid nodules (AFTN) both cause thyrotoxicosis by different pathophysiological mechanisms (1,2). The coexistence of both diseases has been termed "Marine-Lenhart syndrome". Since the first description in 1911 by Marine and Lenhart (3), the presence of focal autonomy in patients with Graves' disease has been reported by numerous authors, and with different presentations (4-14), with an overall prevalence of such association ranging from 2.7% to 4.1% (4). Mo-

reover, during the last years, several papers have been published on the development of Graves' disease shortly after radioiodine therapy for AFTNs (15-18). The incidence of this event is significantly higher, especially in patients with elevated serum thyroid peroxidase antibodies (TPO-Ab) levels at baseline (15,16), as well as in patients TPOAb-negative at baseline who became TPOAb-positive after treatment (17,18).

Here, we report an unusual case of Marine-Lenhart syndrome, in which an AFTN developed after radioiodine therapy for Graves' disease.

CASE REPORT

A 42-year-old woman came to our outpatient clinic in December 2008 because of fatigue, palpitations, tremors, nervousness and irritability, insomnia, oligo-amorrhea, sweating, and weight loss for three months. Graves' disease was diagnosed based on clinical symptoms/signs, a TSH level of < 0.001 mIU/L (normal values, 0.27-4.2) with elevated free triiodothyronine (FT3, 17.39 pg/mL, n.v. 2-4.4) and free thyroxine (FT4, 38.3 pmol/L; n.v. 12-22), and positivity for TSH receptor antibodies (TRAb, 19 IU/L, n.v. < 1.5), as well as thyroid peroxidase antibodies (TPOAb, 158 U/L; n.v. < 35). Thyroid ultrasound (US) examination showed a diffuse enlargement of the gland, associated with hypoechogenicity and increased vascularity. The ^{131}I thyroid scan revealed an enlarged gland with diffuse increased uptake of radioiodine at 6 and 24 hours (Figure 1). Therapy with methimazole (MMI, 30 mg/day) was started, and the patient was referred for radioactive iodine treatment (RIT) in March 2009. Within six weeks from RIT, her thyroid function tests normalized with TSH of 1.64 mIU/L and FT4 of 16 pm/L. TPO-Ab were 364 UI/L. Six months later, thyroid US examination showed a 7-mm hypoechoic nodule with regular margins and an increased intranodular blood flow in color-Doppler in the upper portion of the right lobe. Over the next 18 months, the nodule increased in size up to a maximum diameter of 12 mm (Figure 2). Changes in serum TSH levels during the follow-up after radioiodine treatment are shown in figure 3. In the last evaluation, serum TSH was low-normal (0.67 mIU/L) with normal levels of FT3 and FT4. TRAb were negative. $^{99\text{m}}\text{Tc}$ -Pertechnetate scintigraphy revealed an avid tracer uptake in the right lobe, corresponding to the nodular lesion demonstrated by US, consistently with an AFTN (Figure 4). Thus, our patient developed an AFTN three years after the onset of hyperthyroidism due to Graves' disease that was successfully treated with radioiodine. Looking at the pertinent literature (15-18), we present our case as a variant of classic Marine-Lenhart syndrome. When the "hot" nodule was discovered, there was no diffuse increase in radiotracer uptake by the gland and TRAb were negative, because hyperthyroidism due to Graves' disease – diagnosed three years before – was successfully cured by radioiodine. On the other hand, the two diseases developed in the same individual and there was a close temporal relationship between radioiodine treatment of Graves' disease and the occurrence of the "hot" thyroid nodule.

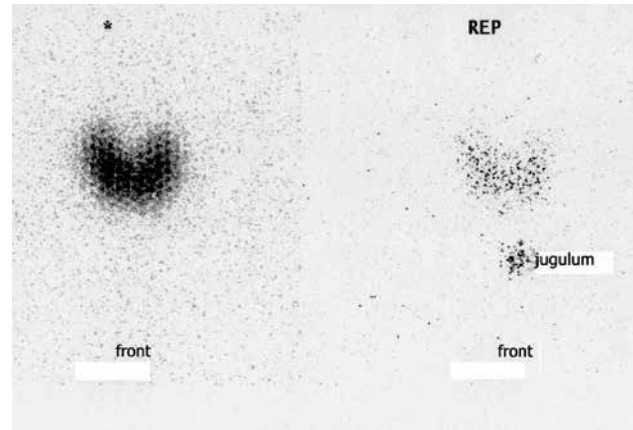


Figure 1. The ^{131}I thyroid scan revealed an enlarged gland with diffuse, increased uptake of radioiodine at 6 (left panel) and 24 (right panel) hours.

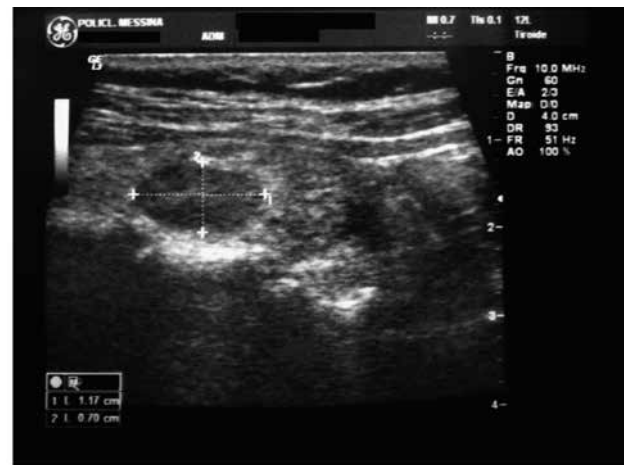

Figure 2. Ultrasonographic appearance of a hypoechoic nodule with regular margins in the upper portion of the right lobe: over 18 months, it increased in size from 7 mm originally to a maximum diameter of about 12 mm.

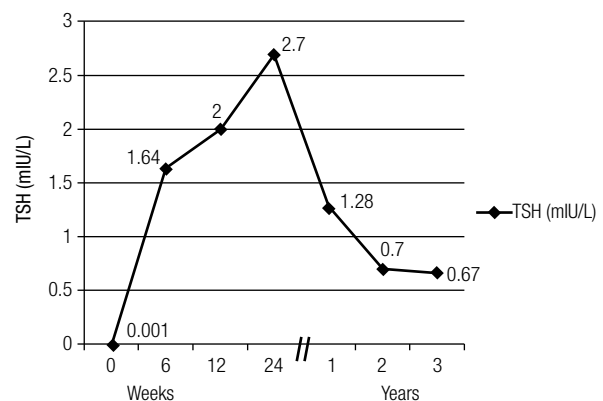


Figure 3. Serum TSH levels during the three-year long follow-up after radioiodine treatment.

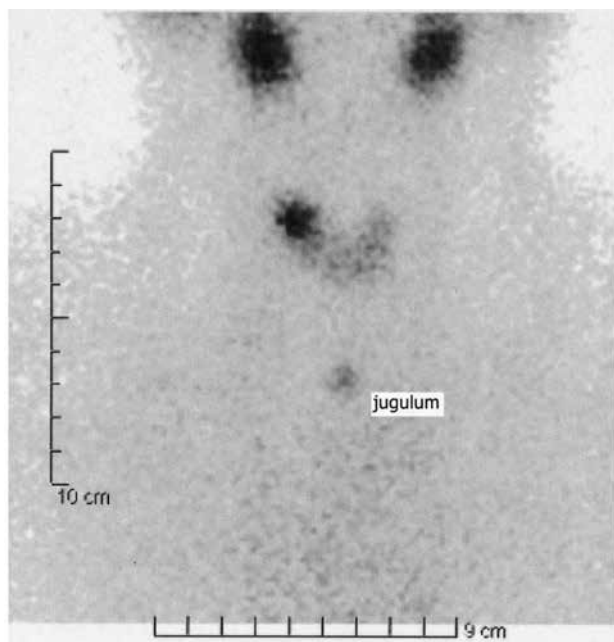


Figure 4. ^{99m}Tc -Pertechnetate thyroid scintigraphy revealed an avid tracer uptake in the right lobe, corresponding to the nodular lesion demonstrated by the US consistent with an AFTN.

DISCUSSION

Coexistence of Graves' disease and AFTN was first described by Marine and Lenhart, in a study about thyroid histopathology and iodine content in exophthalmic goiter (3). Additional reports followed, and most of these articles describe only one or few patients (4-14). The overall prevalence of such association was reported between 2.7% to 4.1% (4). Different mechanisms are implicated in the pathogenesis of Graves' disease and in the nodular formation of thyroid tissue with functional autonomy. Graves' disease is caused by an autoimmune process that involves the whole thyroid gland and is characterized by the presence of stimulating TSH receptor antibodies (1). AFTNs are clonal in origin and virtually independent from TSH for growth and function (2). When a thyroid nodule is recorded in the context of Graves' disease, it is assumed to be scintigraphically "cold". As it emerges from some data in the literature, a nodular variant of Graves' disease can be defined as Marine-Lenhart syndrome when the following criteria are met: (i) the thyroid scan shows an enlarged gland and one or more poorly functioning nodules; (ii) the nodule is TSH-dependent and the peri-nodular tissue is TSH-independent; (iii) after endogenous or exogenous TSH stimulation, the re-

turn of function can be demonstrated in the nodule; and (iv) the nodule is histologically benign (4). In this case, if one or more autonomous nodules are present in the context of Graves' disease, they are suppressed by the over-activity of the remaining gland and, therefore, there is no radioiodine uptake. Once the most part of the gland has been treated with oral medication or radioiodine and, as a consequence, has become progressively less active, the nodules increase their activity in a TSH-dependent way (11). In a unifying pathogenetic hypothesis, it has also been proposed that autoimmunity, such as presence, intrinsic function and concentration of TRAb may influence the preferential development of diffuse or nodular follicular hyperplasia (19), and further enhance nodules activity (20). But several authors believe that Marine-Lenhart syndrome may be due to different pathological mechanisms that occur independently of each other in the same patients, without any relationship between TRAb positivity, and nodular growth and/or function (21). Therefore, the diagnosis of Marine-Lenhart syndrome remains difficult to be determined, and the simultaneous occurrence of the two diseases is still matter of debate (21,22). As it occurred in some case reports (7,8,22), there has been also controversy regarding how to diagnose Marine-Lenhart syndrome, depending on which imaging techniques have been used to identify the thyroid nodule. In fact, although palpation is highly suggestive, it needs confirmation by ultrasonography, in order to exclude an asymmetrical enlargement of one lobe that may give the false sensation of a nodular lesion (23). Moreover, although there is ultrasound detection, it is necessary to determine nodule uptake in a thyroid scan. In most cases, a ^{99m}Tc -pertechnetate thyroid scan enables the identification of focal abnormal uptake of the tracer, corresponding to the AFTN, even in the context of a diffuse, intense uptake by the gland (7-14).

Besides the coexistence of thyroid autonomy (Plummer's disease) and Graves' disease, which is sometimes questionable (21,22), it is also possible that the two diseases may occur in the same patient years apart. There is literature on the risk that Graves-like hyperthyroidism may develop after radioiodine treatment in patients with elevated serum TPO-Ab levels at baseline (15,16), as well as in TPOAb-negative patients at baseline who became TPOAb-positive after treatment (17,18). Therefore, it could be hypothesized that, in a subject genetically susceptible to thyroid autoimmunity, follicular cell damage caused by radioiodine

could trigger an autoimmune response against TSH receptors, thus explaining the occurrence of Graves' disease after radioiodine therapy (15-18). Unlike most cases reported in the literature, our particular case of Marine-Lenhart syndrome shows the appearance of an AFTN as a consequence of Graves' disease treatment with radioiodine. First, Waldherr and cols. described a 46-year-old woman who developed AFTNs within 13 years of radioiodine treatment for Graves' disease, with strongly positive thyroid antibodies. The authors suggested that the autonomous nodules were a consequence of Graves' disease treatment with radioiodine (6). Similarly, our patient developed an AFTN three years after the onset of a hyperthyroidism due to Graves' disease successfully treated with radioiodine. A ^{99m}Tc thyroid scan showed an area of increased focal uptake in the right lobe, corresponding to the palpable nodule, and the existence of the nodule was confirmed by thyroid ultrasonography. The nodule developed in the context of the thyroid gland few months after the radioiodine treatment had been performed, as TSH level started to rise.

In conclusion, the possibility of an association between autoimmune thyroid diseases, namely Graves' disease, and AFTN emerges from several data in the literature (4,24). The most intriguing and interesting aspect of this association is represented not so much by the co-existence of the two diseases, often not easy to ascertain, as by the possibility that they can develop in the same patient over a lifetime. Clinicians should be aware of such a possibility, especially in those patients who are candidate to radioiodine treatment.

Statement of authorship: each author gave a substantial contribution to the paper, and approved the final version to be published.

Funding: this study was not supported by any grant.

Disclosure: no potential conflict of interest relevant to this article was reported.

REFERENCES

- Kahaly GJ, Bartalena L, Hegedüs L. The American Thyroid Association/American Association of Clinical Endocrinologists guidelines for hyperthyroidism and other causes of thyrotoxicosis: an European perspective. *Thyroid*. 2011;21:585-91.
- Krohn K, Paschke R. Progress in understanding the etiology of thyroid autonomy. *J Clin Endocrinol Metab*. 2001;86:3336-45.
- Marine D, Lenhart CH. Pathological anatomy of exophthalmic goiter. *Arch Intern Med*. 1911;8:265-316.
- Charkes ND. Graves' disease with functioning nodules (Marine-Lenhart syndrome). *J Nucl Med*. 1972;13:885-92.
- Nishikawa M, Yoshimura M, Yoshikawa N, Toyoda N, Yonemoto T, Ogawa Y, et al. Coexistence of an autonomously functioning thyroid nodule in a patient with Graves' disease: an unusual presentation of Marine-Lenhart syndrome. *Endocr J*. 1997;44(4):571-4.
- Waldherr C, Otte A, Haldemann A, Müller-Brand J. Marine-Lenhart syndrome: a case observation upon 18 years. *Nuklearmedizin*. 1999;38(8):345-8.
- Braga-Basaria M, Basaria S. Marine-Lenhart syndrome. *Thyroid*. 2003;13:991.
- El-Kaissi S, Kotowicz MA, Goodear M, Wall JR. An unusual case of Marine-Lenhart syndrome. *Thyroid*. 2003;13:993-4.
- Paunkovic N, Paunkovic J. Associated Graves' disease and Plummer disease. *Hellenic J Nucl Med*. 2003;6:44-7.
- Cakir M. Marine-Lenhart syndrome. *J Natl Med Assoc*. 2005;97:1036-8.
- Chatzopoulos D, Iakovou I, Moralidis E. Images in thyroidology: Marine-Lenhart syndrome and radioiodine-131 treatment. *Thyroid*. 2007;17:373-4.
- Brahma A, Beadsmoore C, Dhatariya K. The oldest case of Marine-Lenhart syndrome? *JRSM Short Rep*. 2012;3:21.
- Damle N, Mishra R. Identifying Marine-Lenhart syndrome on a ^{99m}Tc -pertechnetate thyroid scan. *Indian J Endocrinol Metab*. 2013;17(2):366.
- Scherer T, Wohlschlaeger-Krenn E, Bayerle-Eder M, Passler C, Reiner-Concin A, Krebs M, et al. A case of simultaneous occurrence of Marine-Lenhart syndrome and a papillary thyroid microcarcinoma. *BMC Endocrine Disorders*. 2013;13:16.
- Chiovato L, Santini F, Vitti P, Bendinelli G, Pinchera A. Appearance of thyroid stimulating antibody and Graves' disease after radioiodine therapy for toxic nodular goiter. *Clin Endocrinol (Oxf)*. 1994;40:803-6.
- Schmidt M, Gorbauch E, Dietlein M, Faust M, Stützer H, Eschner W, et al. Incidence of postradioiodine immunogenic hyperthyroidism/Graves' disease in relation to a temporary increase in thyrotropin receptor antibodies after radioiodine therapy for autonomous thyroid disease. *Thyroid*. 2006;16:281-8.
- Boddenberg B, Voth E, Schicha H. Immunogenic hyperthyroidism following radioiodine ablation of a focal autonomy. *Nuklearmedizin*. 1993;32:18-22.
- Custro N, Ganci A, Scafidi V. Relapses of hyperthyroidism in patients treated with radioiodine for nodular toxic goiter: relation to thyroid autoimmunity. *J Endocrinol Invest*. 2003;26:106-10.
- Studer H, Huber G, Derwahl M, Frey P. Die Umwandlung von Basedowstrumen in Knotenkroepfe. *Schweiz Med Wochenschr*. 1989;119:203-8.
- Poertl S, Kirner J, Saller B, Mann K, Hoermann R. T3-release from autonomously functioning thyroid nodules in vitro. *Exp Clin Endocrinol Diabetes*. 1998;106:489-93.
- Biersack HJ, Biermann K. The Marine-Lenhart syndrome revisited. *Wien Klin Wochenschr*. 2011;123:459-62.
- Cakir M. Diagnosis of Marine-Lenhart syndrome. Letter to the Editor. *Thyroid*. 2004;14:555.
- Wiest PW, Hartshorne MF, Inskip PD, Crooks LA, Vela BS, Telepak RJ, et al. Thyroid palpation versus high-resolution thyroid ultrasonography in the detection of nodules. *J Ultrasound Med*. 1998;17:487-96.
- Ruggeri RM, Campenni A, Sindoni A, Baldari S, Trimarchi F, Benavenga S. Association of autonomously functioning thyroid nodules with Hashimoto's thyroiditis: study on a large series of patients. *Exp Clin Endocrinol Diabetes*. 2011;119:621-7.