








Retrospective and spatial study of pathological diagnoses of canine and feline cryptococcosis in municipalities in the State of São Paulo

[*Estudo retrospectivo e espacial de diagnósticos anatomopatológicos da criptococose canina e felina em municípios do estado de São Paulo*]

M.F. Toscano¹ , G.F. Machado² , D.B. Rozza² , M. Marinho² , F. Sueiro³ 

¹Graduate, Faculdade de Medicina Veterinária de Araçatuba, FMVA – UNESP, Araçatuba, SP, Brasil

²Faculdade de Medicina Veterinária de Araçatuba, FMVA–UNESP, Araçatuba, SP, Brasil

³Practitioner, Campinas, SP, Brasil

ABSTRACT

Cryptococcosis is a systemic mycosis caused by the genus *Cryptococcus* that affects humans and animals. The present study aimed to describe the epidemiological and anatomopathological profiles, occurrence, and distribution of the infection by *Cryptococcus* spp. in 30 dogs and 110 cats residing in the State of São Paulo, from 2014 to 2020. The study evaluated the results from 140 necropsies and histopathology and cytopathology tests provided by Veterinary Pathology services. A higher occurrence of positive diagnosis was observed in females of both cats and dogs, adults, and mixed breeds of both species. The main diagnostic method used was histopathology, with a predominance of integumentary lesions in dogs and cats (skin pattern), with no significant difference between species and lesion location ($p \leq 0.827$). The time-spatial distribution showed a significant increase in the diagnoses in dogs and cats over the seven years, the identification of areas with a higher rate of diagnosis of cryptococcosis such as Campinas and São José do Rio Preto, and the positive correlation of a diagnosis with climatic data. Retrospective studies of anatomopathological data help to identify suspected cases of cryptococcosis and demonstrate the importance of monitoring and surveillance of cryptococcosis.

Keywords: *Cryptococcus*, veterinary pathology, maps

RESUMO

A criptococose é uma micose sistêmica causada pelo gênero *Cryptococcus*, que acomete humanos e animais. O presente trabalho teve por objetivo descrever o perfil epidemiológico e anatomopatológico, a ocorrência e a distribuição da infecção em 30 cães e 110 gatos residentes no estado de São Paulo, no período de 2014 a 2020. O estudo avaliou 140 registros de necropsia e de exames histopatológicos e citopatológicos fornecidos por serviços de patologia veterinária. Os resultados apontaram maior positividade em fêmeas felinas e caninas, adultos e sem raça definida. O principal método de diagnóstico empregado foi o histopatológico, com predomínio de lesões tegumentares em cães e gatos (padrão cutâneo), não havendo diferença significativa entre espécie e localização da lesão ($P \leq 0,827$). A distribuição tempo-espacial demonstrou o aumento significativo de diagnósticos positivos em cães e gatos ao longo dos sete anos, a identificação de áreas com maior número de diagnósticos positivos, como Campinas e São José do Rio Preto, e a correlação positiva com os dados climáticos dos municípios. Estudos retrospectivos de dados anatomopatológicos auxiliam na identificação de casos suspeitos e demonstram a importância do monitoramento e da vigilância da criptococose.

Palavras-chave: *Cryptococcus*, patologia veterinária, mapa

INTRODUCTION

Cryptococcosis is a systemic fungal infection of subacute to chronic evolution caused by fungi of the genus *Cryptococcus*. The *Cryptococcus*

neoformans/Cryptococcus gattii species complex comprises the pathogenic and clinically relevant species for dogs and cats. *Cryptococcus* spp. can often be isolated from a variety of environmental sources, such as soil, fruits, bird droppings, and decaying vegetables (Pennisi *et al.*, 2013).

Infection occurs from the inhalation of yeasts or basidiospores present in the environment that can reach several organs by hematogenous dissemination (Lappin, 2015). Regarding the occurrence of cryptococcosis in animals, the infection in dogs is still considered sporadic. In contrast, a higher incidence is reported in felines in several countries (Mcgill *et al.*, 2009).

The clinical signs in domestic animals comprise four isolated or combined clinical syndromes: respiratory, neurological, ocular, and cutaneous. Sneezing, coughing, hyporexia, skin lesions, lymphadenomegaly, and neurological manifestations are described (Müller and Nishizawa, 2017). Cryptococcosis is the most common cause of granulomatous rhinitis in cats. In dogs, clinical signs and lesions are most related to the central nervous system and eyes (Pereira, 2013).

Retrospective studies from different databases are important tools for analyzing descriptions of the epidemiological, clinical, and laboratory characteristics of cryptococcosis (Mcgill *et al.*, 2009). These studies added to the recognition of spatial distribution and assisted in defining the pattern of occurrence of the infection in specific regions, through health mapping and georeferencing (Duncan, 2005). However, reports of geoprocessing of cryptococcosis in Brazil, besides being scarce, are restricted to the occurrence in humans (Barata *et al.*, 2020).

The present study aims to describe the epidemiological and pathological profile of cryptococcosis in dogs and cats, as well as its occurrence and spatial distribution in the municipalities of the State of São Paulo, from the retrospective analyses of commercial veterinary pathology laboratory records.

MATERIAL AND METHODS

This study comprises a retrospective study of data on the results of necropsies and histopathological and cytopathological tests of dogs and cats diagnosed with cryptococcosis in the State of São Paulo, from 2014 to 2020. Information was collected from 140 records of canine and feline cryptococcosis from four commercial veterinary pathology laboratories located in the municipalities of Araçatuba (2) and

Campinas (2), both located in the State of São Paulo.

Analyses of the epidemiological and pathological profiles of cryptococcosis in dogs and cats were carried out by tabulating and investigating the variables: species, sex, age, breed, the body system affected, lesion patterns (macroscopic and microscopic), diagnostic method, and complementary tests.

Moreover, the temporal and spatial distribution of the disease in municipalities of the State of São Paulo was evaluated, to determine the areas of occurrence and concentration of cryptococcosis, using the method of geoprocessing in health. The addresses contained in the animal records were georeferenced and converted into geographic coordinate points from Google My Maps. Then, the coordinates of each point were inserted into the vector format of the geospatial data, known as a layer or shapefile, resulting in digital meshes. The spatial data were grouped and divided into seven vector layers, one for each year studied (2014 to 2020).

Subsequently, the georeferenced data were submitted to geoprocessing using the QGIS software version 3.12, a freeware based on the Geographic Information System (GIS). The vectorial layers with annual locations of cryptococcosis diagnoses were added to the shapefile of the State of São Paulo, which was obtained from the website of the Brazilian Institute of Geography and Statistics (IBGE, 2021), allowing the preparation of maps of cryptococcosis occurrence.

The QGIS tools also allowed the creation of heat maps, by the Kernel method, to visualize the spatial distribution regarding the concentration of cases by density strata for the municipalities, through the intensity of colors.

The distribution of cases was also compared with the climatic data (air temperature and humidity), according to the information and vectorial layers previously extracted from the Brazilian Institute of Geography and Statistics (IBGE) site. The climatic conditions were classified according to temperature into mild mesothermal climate (average annual temperature between 10°C and 15°C), median mesothermal (average temperature below 10°C), hot (average

temperature above 18°C in all months of the year), and sub-hot (average temperature between 15°C and 18°C for at least one month of the year). Regarding the classification according to air humidity, which is defined by the amount of rainfall, the climate was divided into semi-arid (6 to 8 months of drought), semi-humid (4 to 5 months of drought), super-humid (no drought), and humid (1 to 3 months of drought).

The variables (animal species and body system affected by cryptococcosis) were tested by the Chi-square test (Pearson's Test of Independence) at a significance level of 5% using the software RStudio, version 1.2.1335.

This study was approved by the Ethics Committee on Animal Use (CEUA) of the Faculdade de Medicina Veterinária de Araçatuba, UNESP (Process No. 0115/2021).

RESULTS

In the period between 2014 and 2020, four commercial veterinary pathology laboratories completed 140 diagnoses of cryptococcosis in 110 cats and 30 dogs, using samples from 42

municipalities in the State of São Paulo. Using laboratory records or referral forms, it was possible to elucidate the epidemiological profile of cryptococcosis diagnosis according to the variables of sex and age (Table 1). It was not possible to identify the age range of 28 animals.

Regarding the breeds of cats and dogs, 89.1% and 33.3% were mixed-breed (SRD), respectively. Purebred cats were identified as Siamese (5), Turkish Angora (1), and Persian (1). Purebred dogs were identified as German Shepherds (4), Labrador (2), Pit Bull (2), and one dog of each of the following breeds: Bulldog, Cocker Spaniel, Fox Paulistinha, Poodle, Pinscher, Pug, Rottweiler, Schnauzer, and Weimaraner.

The temporal analysis of the records from 2014 to 2020 demonstrated a significant increase in the number of canine and feline cryptococcosis diagnoses performed by the four commercial veterinary pathology laboratories in the State of São Paulo. The frequency observed in 2019 represents 5.5 times the number of cases reported in 2014.

Table 1. Epidemiological profile of dogs and cats with laboratory diagnosis of cryptococcosis, in the state of São Paulo, between 2014 and 2020

	Total		Feline		Canine	
	(N)	(%)	(N)	(%)	(N)	(%)
Sex						
Male	56	40	44	40	12	40
Female	67	47.9	49	44.5	18	60
Unclassified	17	12.1	17	15.5	0	0
Age						
0 – 1 year	19	13.6	13	11.8	6	20
2 – 7 years	65	46.4	51	46.4	14	46.7
> 8 years	28	20	21	19.1	7	23.3

The laboratory records allowed the classification of the diagnostic tests into histopathology (biopsy or surgical specimen), cytopathology, and necropsy followed by histopathology. The diagnoses of cryptococcosis in dogs and cats were mostly elucidated by histopathology, through the analyses of biopsies and surgical specimens. As for the association with other diagnostic methods, in only 11 cases the histochemical technique using Schiff's Periodic Acid (SPA) staining was used. Four feline records described the use of fungal culture for

the identification and differentiation of the species of the *C. neoformans/C. gattii* species complex (Table 2).

Table 2 also describes the body systems of dogs and cats affected by cryptococcosis. Canine and feline cryptococcosis showed a predilection for cutaneous tissue (integumentary system) in 40% of the reports, with lesions on the face (nasal plane), limbs, or trunk. Tissues and organs most affected by cryptococcosis are described as follows: respiratory system (the nasal cavity and

lungs); digestive system (the oral cavity and intestine); and lymphatic system (submandibular lymph nodes). There was no association between the system affected and the animal species evaluated ($p \leq 0.827$).

Regarding the nine cases with multisystemic manifestations, involvement of the urinary and cardiovascular systems was described as associated or not with cutaneous, respiratory, or lymphatic lesions. In three cats there was fungal proliferation in the brain and cerebellum concomitantly with the respiratory and lymphatic systems.

Macroscopic records reported the presence of ulcerated nodules and plaque lesions or irregular tissue fragments, of varying sizes and coloration, with a predominantly friable to gelatinous appearance. Microscopy (histopathology or cytopathology) tests identified lymphocytes, macrophages, multinucleated giant cells, and a few neutrophils, associated with round to ovoid yeast-like structures with a basophilic center and surrounded by a thick gelatinous halo, compatible with the *Cryptococcus* genus. Thus, the changes were classified as granulomatous or pyogranulomatous inflammations of fungal etiology.

Table 2. Records of examinations and pathological profile of dogs and cats with laboratory diagnosis of cryptococcosis, in the State of São Paulo, between 2014 and 2020

	Total		Feline		Canine	
	(n)	(%)	(n)	(%)	(n)	(%)
Exam						
Histopathology	93	66.4	73	66.4	20	66.7
Cytopathology	43	30.7	35	31.8	8	26.7
Necropsy	4	2.9	2	1.8	2	6.7
System						
Tegumentary	56	40	47	42.7	9	30
Respiratory	16	11.4	12	10.9	4	13.3
Digestive	6	4.3	5	4.5	1	3.3
Lymphatic	9	6.4	6	5.5	3	10
Systemic	9	6.4	7	6.4	2	6.7
Unclassified	44	31.4	33	30	11	36.7
Complementary tests						
Absent	125	89.3	97	88.2	28	93.3
SPA ¹	11	7.9	9	8.2	2	6.7
Fungal culture	4	2.8	4	3.6	0	0,0

¹SPA: Schiff's Periodic Acid

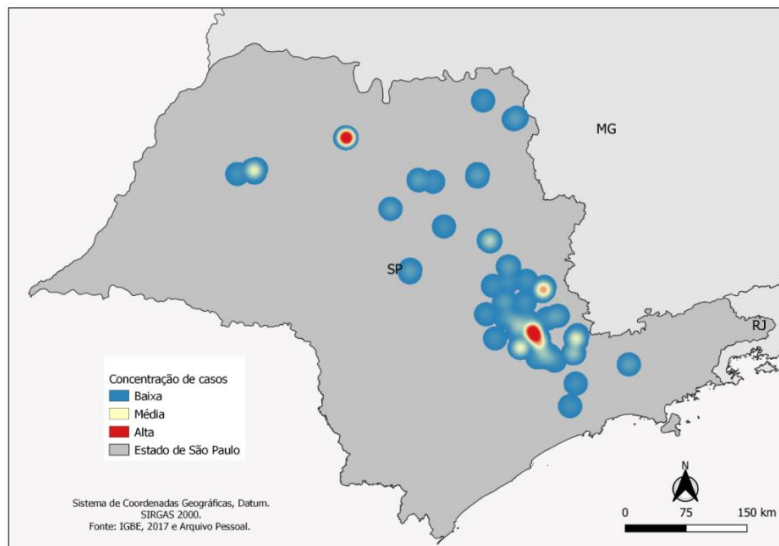
The evaluation of the spatial distribution allowed the distribution of the 140 cases recorded among 42 municipalities in the state of São Paulo.

Using the Kernel method, it was possible to elaborate the heat map for the stratification of the areas of concentration of the diagnosis of fungal infection, which was classified as low concentration (1 to 6 cases), medium concentration (7 to 13 cases), and high concentration (above 14 cases). Thus, the municipalities of the state of São Paulo with the higher, medium, and low concentrations of diagnoses were, respectively, São José do Rio Preto and Campinas; Araçatuba, Mogi Mirim,

and the Campinas metropolitan region; and the remaining municipalities of the state of São Paulo State (Fig. 1).

The time-space distribution of canine and feline cryptococcosis allowed us to identify that between 2014 and 2017, most cases were restricted to the East Paulista region, with the highest number of positive diagnoses in the metropolitan region of Campinas. In 2018, positive diagnoses were also recorded in the Northern region (such as Ribeirão Preto and Franca) and Northwestern Paulista (Araçatuba and São José do Rio Preto) municipalities.

Retrospective and spatial...

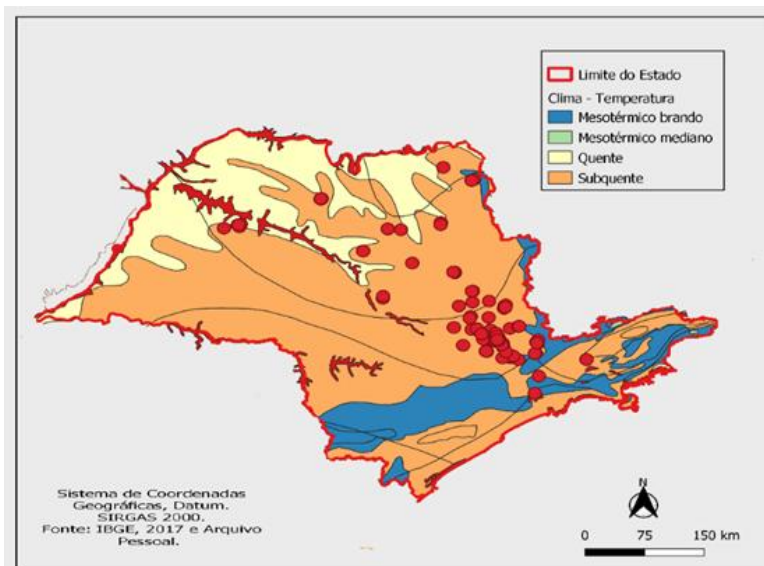


Legend: Blue market points indicate low case concentration. In yellow, medium concentration, and red, high concentration of cases.

Figure 1. Heat map for the stratification of the concentration of positive diagnosis of canine and feline cryptococcosis in the state of São Paulo, between 2014 and 2020.

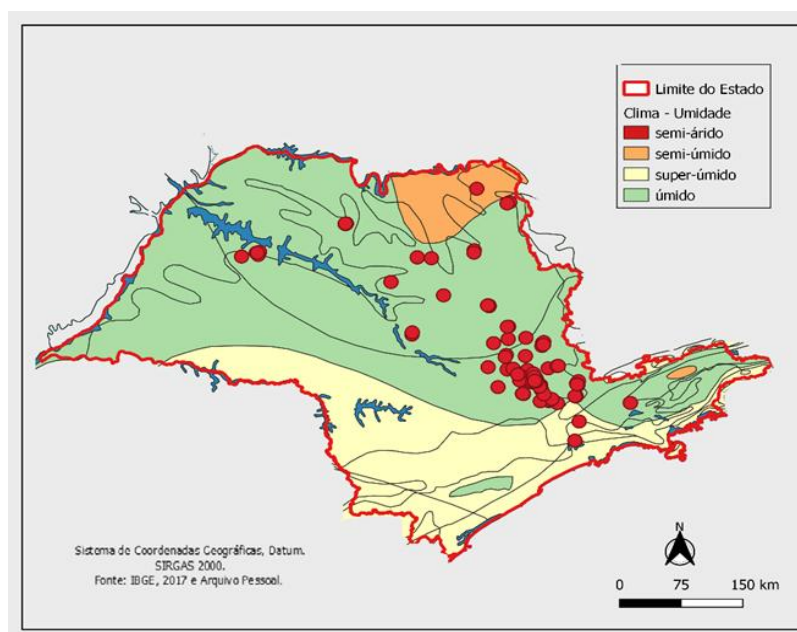
The analysis of the distribution of positive diagnoses compared to the climatic data of the regions of the State of São Paulo, according to the air temperature and humidity, allowed us to elucidate the predominance of the occurrence of

canine and feline cryptococcosis in municipalities located in warm areas, with high average annual temperatures, and humid or semi-humid areas, with short or absent dry periods (Fig. 2 and 3).



Legend: Dots in red indicate diagnosed cases. The areas of the State of São Paulo in light yellow represent a warm climate. Orange and blue colors indicate a sub-hot and mild mesothermal climates, respectively.

Figure 2. Spatial distribution of positive diagnosis of canine and feline cryptococcosis cases according to the climatic data and mean air temperature in the municipalities of São Paulo.



Legend: Red dots indicate diagnosed cases. The areas of the State of São Paulo in orange represent a semi-humid climate. In light yellow, they indicate a super-humid climate, and in green, humid climate.

Figure 3. Spatial distribution of positive diagnosis of canine and feline cryptococcosis according to climatic data and mean air humidity in the municipalities of the state of São Paulo.

DISCUSSION

Different studies have isolated or described the species of the *Cryptococcus neoformans*/*Cryptococcus gattii* species complex in clinical (human and animal) and environmental samples in different municipalities of São Paulo State (Bruchi *et al.*, 2009; Araújo Júnior, 2015; Martins *et al.*, 2017). However, no studies describing the occurrence and distribution of cryptococcosis in domestic animals were identified covering compilations of anatomopathological diagnosis records in forty-two (42) cities of São Paulo.

Similar to what was observed in this retrospective study, cryptococcosis occurs more frequently in cats when compared to other domestic animals (McGill *et al.*, 2009; Canavari *et al.*, 2017). This difference in epidemiological pattern suggests a greater probability of infection by *Cryptococcus* in cats, which can be justified by the different habits of the species, as cats generally have greater access to the street and contact with trees, organic matter, and bird droppings (Pereira, 2013).

McGill *et al.* (2009) reported that 53.6% of the 57 dogs studied with cryptococcosis were female and the mean age of the population was 2.5 years, considered as young adults. The 72 cats reported in the same study were also mostly females but with a mean age of 7.5 years. The results presented regarding the sex of domestic animals diagnosed in the state of São Paulo corroborate the data described above. As for the age of the animals, both canines and felines were predominantly adults, from 2 to 7 years old (Coelho *et al.*, 2009). Researchers have not confirmed explanations for the likely predilection of infection in female dogs and cats.

Cryptococcosis is typically reported in dogs of large breeds, including German Shepherds, Pitt Bull, and Labrador (Coutinho and Pereira, 2003), as seen in this data survey. The higher frequency in large dogs may be influenced by breeding in open environments, such as backyards and gardens, and guarding activities, unlike small breeds that preferentially live indoors (Pereira, 2013). In contrast, the predominance of records of cryptococcosis in dogs and cats without a defined breed in the municipalities of São Paulo can be explained by the results of censuses

conducted in Brazil, where most domestic animals are mixed breeds (Censo..., 2016). According to Coelho *et al.* (2009), Siamese cats are more prone to develop cryptococcosis, a fact that may be associated with a genetic predisposition.

Although data on the clinical history of the animals was not available, it should be noted that fungal infections, mainly caused by *C. neoformans*, preferentially affect immunosuppressed individuals (Müller and Nishizawa, 2017). Hoarders conditions, with consequent inadequate hygienic-sanitary conditions, result in a variety of infectious diseases, including systemic mycoses (Tommaso, 2017).

Access to the street or routine walks could also justify the appearance of lesions of fungal etiology in the animals studied. In Araçatuba, Araújo Júnior (2015) isolated yeasts of the genus *Cryptococcus* in tree trunks and hollows present in city squares and parks. These sites represent important environmental microfoci because they have a high flow of people and domestic animals, which may explain the average concentration of cases of dogs and cats in the city of Araçatuba, identified by this study.

A retrospective study of the main fungal morbidities in domestic cats, including cryptococcosis, was reported in Santa Catarina (Castro *et al.*, 2017).

Studies indicate that most cases of canine cryptococcosis are related to alterations in the central nervous system, different from the results found in the 30 dogs evaluated in this study. Lester and colleagues (2004) reported that of 15 cases of infection in dogs, 60% showed neurological signs. Feline meningitis or meningoencephalitis associated with *Cryptococcus* infection identified in three reports of this study was also described by Coelho *et al.* (2009). The absence of neurological alterations in canines and the low occurrence in felines from this study may be justified by two factors: the type of casuistry of the four veterinary pathology laboratories, which receive mostly requests for histopathological and cytopathological analysis of dermatological lesions of dogs and cats; the absence of descriptions of the animals' clinical histories in the requests sent to the laboratories,

making it difficult to associate the positive diagnoses with systemic and neurological manifestations. Another result of this study that does not corroborate with the current literature (Herculano *et al.*, 2020) was the high identification of dermatological lesions in dogs, even though the cutaneous form of cryptococcosis is considered uncommon for the species. Thus, our study highlights the need to include cryptococcosis in the differential diagnosis of dermatopathies in dogs.

In contrast, the dermatological pattern is described in 56 cats from the state of São Paulo. It is characterized mainly by the formation of nodules in the skin and subcutaneous tissue over the cartilage of the nasal plane, leading to the "clown nose" aspect (Coutinho and Pereira, 2003). Predilections for different anatomical sites for each species are evidenced in the literature. The cutaneous pattern of cryptococcosis in the dogs and cats studied could be justified by the casuistry of the laboratories, types of samples forwarded, and collection methods (Pennisi *et al.*, 2013).

Macroscopic and microscopic changes in the cardiovascular, digestive, lymphatic, or multisystems of dogs and cats have also been reported in retrospective studies (McGill *et al.*, 2009).

Dogs and cats in this study showed a higher frequency of macroscopic and microscopic lesions in the integumentary system, followed by the respiratory, digestive, lymphatic, and multiple systems, with the respiratory tract being the likely portal of entry of the infectious agent. However, the results of the positive diagnosis data between cats and dogs and between body systems were statistically non-significant.

Due to the predominance of samples collected by incisional biopsies or aspiration biopsy puncture (ABP) and the sparse descriptions of clinical history and signs in requisitions forwarded to Veterinary Pathologists, it was not possible to identify the injured system or tissue in 44 records. Otherwise, lesions were polypoid or diffuse nodules, single or multiple, ulcerated, with gelatinous appearance and viscous to mucoid exudate, similar to the ones described in the literature (Zachary and McGavin, 2013).

The temporal and time-space analyses from 2014 to 2020 pointed out an increase in the number of diagnoses of canine and feline cryptococcosis in the 42 municipalities evaluated and a dispersion of reports from the East to the North and Northwest of the state of São Paulo, starting in 2018. However, it would not be possible to effectively draw a comparison with other veterinary databases, due to the scarcity of official data on cryptococcosis in domestic animals, as it is not a disease of compulsory notification (Santos, 2018). On the other hand, this increase can be justified by the increase in the sending of biological samples for diagnosis and expansion in the casuistry of the Animal Pathology laboratories, located in Campinas and Araçatuba.

Cryptococcus neoformans/C. gattii species complex have already been isolated from clinical and environmental samples in the municipalities with high and medium concentrations of cases, which are also geographically close to the laboratories included in this study (Bruchi *et al.*, 2009; Araújo Júnior, 2015). In the region of São José do Rio Preto, *Cryptococcus* spp. have been isolated only in environmental and clinical samples from human patients, for genotyping and antifungal resistance evaluation (Barboza, 2011).

This study demonstrated the occurrence of cryptococcosis diagnosis in dogs and cats and its possible association with climatic factors in the state of São Paulo. It is known that pathogenic species of the genus *Cryptococcus* can grow at high temperatures and humidity. The colonies generally grow after 48 to 72 hours of incubation, at temperatures between 28-32°C (Ramos, 2015). Thus, the cases diagnosed by Veterinary Pathology services have been described preferentially in municipalities with hot or sub-hot and humid climates. Cities with climatic conditions of high average temperatures but little shade do not favor the occurrence of cryptococcosis (Baltazar and Ribeiro, 2008). Thus, cities with tropical climates, average annual temperature near 19°C, and high rainfall are ideal for the growth of yeast (Destro, 2016). It is noteworthy that the seasons of the year can also influence fungal growth, as observed by Araújo Júnior (2015), between the months of November and December, a period of higher humidity in the city of Araçatuba-SP.

CONCLUSION

The diagnosis of cryptococcosis in dogs and cats from São Paulo State in the period from 2014 to 2020 presented a high concentration of cases in Campinas and São José do Rio Preto, locations where environmental conditions such as temperature and air humidity are favorable for fungal growth. Moreover, there has been an increase in the number of cases diagnosed in dogs and cats in recent years, which demonstrates the importance of monitoring and surveillance of cryptococcosis.

ACKNOWLEDGEMENTS

This study was financed in part by the Coordenação de Aperfeiçoamento de Pessoal de Nível Superior – Brasil (CAPES).

REFERENCES

- ARAÚJO JÚNIOR, E.C. *Cryptococcus*: environmental isolation and biochemical characterization. *Arq. Bras. Med. Vet. Zootec.*, v.67, p.1003-1008, 2015.
- BALTAZAR, L.M.; RIBEIRO, M.A. Primeiro isolamento ambiental de *Cryptococcus gattii* no Estado do Espírito Santo. *Rev. Soc. Bras. Med. Trop.*, v.41, p.449-453, 2008.
- BARATA, R.S.; VIEIRA, C.M.; OLIVEIRA, R.A.C; GUEDES, J.A.; GONÇALVES, N.V. A meningite criptocócica: análise espacial, epidemiologia e fatores de risco no estado do Pará, amazônia oriental brasileira. *Hygeia Rev. Bras. Geografia Méd. Saúde*, v.16, p.74-83, 2020.
- BARBOZA, L.S. *Estudo microbiológico: amostragem de Cryptococcus sp em São José do Rio Preto/SP*. 2011. 85f. Dissertação (Mestrado em Microbiologia) - Instituto de Biociências, Universidade Estadual Paulista “Júlio de Mesquita Filho”, São José do Rio Preto, SP.
- BRUCHI, W.; NICOLUTTI, R.; CARMONA CASTRO, R. Levantamento prospectivo da ocorrência de *Cryptococcus neoformans* nas narinas de gatos portadores ou não de doenças respiratórias atendidos no Hospital Veterinário e Fazenda Escola da Faculdade Comunitária de Campinas–Unidade 3 e Região de Campinas. *Anuário Prod. Iniciação Cient. Discente*, v.11, p.253-262, 2009.

- CANAVARI, I.C.; VARGAS, G.H.; TINUCCI-COSTA, M.; CAMPLESI, A.C. Criptococose: revisão de literatura. *Rev. Electr. Vet.*, v.18, p.1-5, 2017.
- CASTRO, N.B.; ROLIM, V.; FERREIRO, L.; DRIEMEIER, D. Doenças micóticas em gatos no Rio Grande do Sul. *Pesqui. Vet. Bras.*, v.37, p.1313-1321, 2017.
- CENSO canino: as 20 raças de cachorro mais populares do Brasil. 2016. Available in: <https://love.doghero.com.br/censo/censo-canino-2016-20-racas-de-cachorro-mais-populares-brasil/>. Accessed in: 20 Oct. 2021
- COELHO, H.E.; MOURA, L.R.; ORPINELLI, S.R.T; KOCK, G.P.; MACHADO, F.M.R.; JÚNIOR, A.F. *Cryptococcus* neoformans associado à meningite felina em Uberaba, MG: relato de caso. *Vet. Not.*, v.15, n.1, 2009.
- COUTINHO, S.D.A.; PEREIRA, A.P.C. Criptococose em cães e gatos–revisão. *Clín. Vet.*, v.45, p.24-32, 2003.
- DESTRO, M. Isolamento ambiental e caracterização bioquímica de *Cryptococcus*. *Arq. Bras. Med. Vet. Zootec.*, v.67, p.1003-1008, 2016.
- DUNCAN, C. Sub-clinical infection and asymptomatic carriage of *Cryptococcus gattii* in dogs and cats during an outbreak of cryptococcosis. *Med. Mycol.*, v.43, p.511-516, 2005.
- GEOCIÊNCIAS: informacoes ambientais e climatologia. Rio de Janeiro: IBGE, 2021.
- Available in: <https://www.ibge.gov.br/geociencias/informacoes-ambientais/climatologia/15817-clima.html?=&t=oque-e>. Accessed in: 25 Oct. 2021.
- HERCULANO, L.F.S.; GALINDO, V.R.; CAVALCANTE NETO, T.S. Criptococose cutânea canina: relato de caso. *Med. Vet.*, v.14, p.268-276, 2020.
- LAPPIN, M. Doenças infecciosas. In: NELSON, R.W.; COUTO, C.G. *Medicina interna de pequenos animais*. 5.ed. Rio de Janeiro: Elsevier, 2015. 1512p.
- LESTER, S.J.; KOWALEWICH, N.J.; BARTLETT, K.H. *et al.* Clinicopathologic features of an unusual outbreak of cryptococcosis in dogs, cats, ferrets, and a bird: 38 cases (January to July 2003). *J. Am. Vet. Med. Assoc.*, v.225, p.1716-1722, 2004.
- MARTINS, M.A.; SANTOS, D.C.S; ARAÚJO, M.R.; REGINA, S. Criptococose: atualização e análise de dados laboratoriais sobre a frequência de *Cryptococcus gattii* no Estado de São Paulo numa série temporal de 11 anos. *Bol. Epidemiol. Paulista*, v.14, p.1-10, 2017.
- MCGILL, S.; MALIK, R.; SAUL, N. *et al.* Cryptococcosis in domestic animals in Western Australia: a retrospective study from 1995-2006. *Med. Mycol.*, v.47, p.625-639, 2009.
- MÜLLER, M.; NISHIZAWA, M. A criptococose e sua importância na medicina veterinária. *Rev. Educ. Cont. Med. Vet. Zootec., CRMV-SP*, v.15, p.24-29, 2017.
- PENNISI, M.G.; HARTMANN, K.; LLORET, A. Cryptococcosis in cats: ABCD guidelines on prevention and management. *J. Feline Med. Surg.*, v.15, p.611-618, 2013.
- PEREIRA, M.F. Aspectos clínicos e anatomopatológicos da criptococose nasal com disseminação sistêmica em cão: relato de caso. *Med. Vet.*, v.7, p.7-15, 2013.
- RAMOS, K. *Variação fenotípica e genotípica de isolados do complexo de espécies Cryptococcus neoformans/gattii*: revisão de literatura. 2015. 59f. Monografia (Trabalho de conclusão de curso) – Centro de Ciências Biológicas, Universidade Federal de Santa Catarina, SC.
- SANTOS, F.B. *Estudo ambiental, caracterização molecular e estratégia de vigilância dos agentes da criptococose na microrregião do Rio Negro no estado do Amazonas*. 2018, 138f. Tese (Doutorado em Medicina Tropical) - Instituto Oswaldo Cruz, Fundação Oswaldo Cruz, Rio de Janeiro, RJ.
- TOMMASO, V.G. *Análise de denúncias de excesso de cães e gatos no município de São Paulo no período de 2006 a 2015*. 2017. Dissertação (Mestrado em Epidemiologia) – Faculdade em Saúde Pública, Universidade de São Paulo, SP.
- ZACHARY, J.F; MCGAVIN, M.D. *Bases da patologia em veterinária*. 5.ed. Rio de Janeiro: Elsevier, 2013. 1344p.