



## Omentum as non-strangled inguino scrotal hernia content in stallion: case report

[Omento como conteúdo de hérnia inguino-escrotal não estrangulada em garanhão: relato de caso]

G.C. Góss<sup>1</sup>, M.S. Azevedo<sup>2</sup>, C.A. Duarte<sup>2</sup>, F.D. Mozzaquatro<sup>2</sup>, G.D. Pradella<sup>1</sup>,  
P.M. Taschetto<sup>1</sup>, G.F. Heckler<sup>3</sup>, E.S. Severo<sup>3</sup>

<sup>1</sup>Aluno de pós-graduação - Universidade Federal do Pampa - Uruguaiiana, RS

<sup>2</sup>Universidade Federal do Pampa - Uruguaiiana, RS

<sup>3</sup>Aluno de graduação - Universidade Federal do Pampa - Uruguaiiana, RS

### ABSTRACT

Non-strangulated acquired hernias in stallions are rare, especially when the herniated content is not intestinal loops. Thus, the aim of the current study is to describe a case of acquired non-strangulated inguinoscrotal hernia in a stallion, whose herniated content was the omentum. The patient was a Criollo stallion with history of rhabdomyolysis, laminitis and bilateral scrotal volume increase observed in the left scrotal region. The animal presented pain in both thoracic limbs, abnormal blood test, especially hypoproteinemia, and mild pain during palpation in the left inguinal ring region. Hydrocele secondary to hypoproteinemia was suspected. After admission, the animal showed signs of acute abdomen, which were clinically reversed. With this, the animal was subjected to ultrasound examination of the scrotal region, whose findings suggested non-strangulated inguinal hernia, although the content could not be identified. Surgical treatment was chosen in order to identify the herniated content and remove the left testicle. Access to the affected scrotum was performed, in which the presence of fluid and a portion of the omentum was observed surrounding the testis and adhering to it. The animal was discharged after he recovered from the surgery and from laminitis. During the breeding season, the stallion remained with a herd of mares for natural mating. After 15 months of surgery, the animal was reassessed and showed no active signs of inflammatory and degenerative processes in the remaining testis. On this occasion, a pregnancy diagnosis was also performed, and all the mares were pregnant. It is concluded that the presence of omentum as a herniated content does not represent a surgical emergency but can make the reproductive prognosis reserved. In addition, removal of the affected testicle can benefit the spermatogenesis of the remaining testicle.

Keywords: acquired hernia, equine, testicular degeneration, treatment

### RESUMO

*As hérnias adquiridas não estranguladas em garanhões são raras, principalmente quando o conteúdo herniado não é de alças intestinais. Assim, o objetivo deste trabalho foi descrever um caso de hérnia inguino escrotal adquirida e não estrangulada em garanhão, cujo conteúdo herniado era composto pelo omento. Foi atendido um garanhão da raça Crioula com histórico de rabdomiólise, laminite e aumento de volume escrotal bilateral, evidenciado na região escrotal esquerda. O animal apresentava dor nos membros torácicos, alterações na avaliação sanguínea, destacando-se a hipoproteinemia, e demonstrava dor leve à palpação na região do anel inguinal esquerdo. Suspeitou-se de hidrocele secundária a hipoproteinemia. Após a internação, o animal apresentou sinais de abdômen agudo, revertidos clinicamente. Com isso, realizou-se ultrassonografia da região escrotal, cujos achados sugeriram hérnia inguinal não estrangulada, sem que o conteúdo pudesse ser identificado. Optou-se pelo tratamento cirúrgico, com o intuito de identificação do conteúdo herniado e remoção do testículo esquerdo. Foi realizado acesso à bolsa escrotal afetada, na qual se observou presença de líquido e de uma porção do omento envolvendo o testículo e aderido a ele. O animal recebeu alta após restabelecimento da cirurgia e da laminite. Na propriedade, durante temporada reprodutiva, o garanhão permaneceu com uma manada de éguas para realização de monta natural. Passados 15 meses da cirurgia, o animal foi reavaliado e não demonstrou sinais ativos de processo inflamatório e degenerativos no testículo remanescente. Nessa ocasião, também foi realizado diagnóstico de gestação e todas as éguas encontravam-se prenhes. Conclui-se que a presença de omento como conteúdo herniado não representa uma emergência cirúrgica, mas pode tornar*

*o prognóstico reprodutivo reservado. Ainda, a remoção do testículo afetado pode trazer benefícios à espermatogênese do remanescente.*

*Palavras-chave: hérnia adquirida, equino, degeneração testicular, tratamento*

## INTRODUCTION

Acquired inguinoscrotal hernias in stallions are diagnosed in approximately 3% (Kovac *et al.*, 2018) to 7% (Van der Velden, 1988) of horses with colic syndrome. In these cases, the herniated content is often composed of small intestine segments and is ischemic (Van der Velden, 1988; Kovac *et al.*, 2018). On the other hand, acquired non-strangulated hernias are not often diagnosed (Bach and Ricketts, 1974). The herniation of other intestinal loops or other organs is rarely reported; the reported cases mainly refer to young animals (Ivens *et al.*, 2009; Robinson and Carmalt, 2009; Cousty *et al.*, 2010) or to horses who were recently exposed to orchiectomy procedures (Schumacher, 2006; Ivens *et al.*, 2009).

One of the clinical signs observed in animals presenting this condition lies on increased scrotal volume (Stick, 2006; Kovac *et al.*, 2018), which is also observed in several pathologies involving the testes and the epididymis (Claes and Stout, 2015). When the diagnosis of inguinoscrotal hernia is confirmed, treatment is usually surgical (Van der Velden, 1988; Wilderjans *et al.*, 2009; Kovac *et al.*, 2018), and consists of opening the tunica vaginalis to evaluate the viability of the herniated content, with orchiectomy being often indicated in these cases (Wilderjans *et al.*, 2009). The aim of this paper is to describe a case of acquired non-strangulated scrotal-inguinal hernia in a stallion, whose herniated content was the omentum.

## CASUISTRY

The patient was a 6-year-old criollo stallion, weighing 450kg. The horse was referred to the veterinary hospital due to the occurrence of laminitis that was being treated on the owner's property, but without success. Initially, the clinical history of the horse was not well clarified, and during the hospitalization, the horse owner revealed that approximately 60 days before hospitalization the animal was examined by a veterinarian at the farm and was diagnosed with rhabdomyolysis. After receiving treatment for this condition, the animal presented with acute

laminitis and was treated, on the property, with dimethyl sulfoxide, gentamicin, potassium penicillin, phenylbutazone, acetyl salicylic acid, isoxsuprine and flunixin meglumine between the onset of signs laminitis and admission to the veterinary hospital. However, the stallion did not show satisfactory evolution in the treatment of laminitis; besides, he presented increased left scrotal volume for 20 days, thus opting for referral to the veterinary hospital.

During the examination at the veterinary hospital the animal remained in typical laminitic stance and had difficulty getting around. There was also increased bilateral scrotal volume, although it was more evident on the left side (Figure 1A), which showed moderate hypothermia at palpation, as well as significant hydrocele and mild pain, with painful response only close to the inguinal ring. In addition, the left testicle presented flaccid consistency and decreased size. The right side presented hydrocele and mild hypothermia, although there was not pain observed. However, the right testis showed normal size and consistency.

General physical examination revealed tachycardia (60 bpm), tachypnea (40 mpm), and increased digital pulse in both thoracic limbs; these findings were attributed to laminitis. Blood and biochemical test were also conducted; results showed severe hypoproteinemia (4.95g/dL), hyperfibrinogenemia (0.6g/dL) and thrombocytosis (254,000/ $\mu$ L), as well as elevated urea (64mg/dL) and creatinine (1.46mg/dL) levels. Laminitis management was based on the use of ethylene-vinyl acetate (EVA) insoles, soft stall rest and on bulky feed. In addition, treatment included firocoxib (0.4mg/kg - orally administered (OA) and ketamine (0.04mg /kg - subcutaneously administered (SC)), which were used as analgesics; isoxsuprine (0.8mg/kg - OA), which was used as peripheral vasodilator; pentoxifylline (7.5mg/kg - OA), which was used as red cell modulator; and omeprazole (4mg/kg - OA), which was used as a gastric protector. The therapy was enough to keep the animal clinically stable and to improve the laminitis signs.

### *Omentum as non-strangled...*

The blood count was repeated 3 days after the therapy; results showed persistent hypoproteinemia (5g/dL) and thrombocytosis (243,000/ $\mu$ L), whereas other parameters returned to physiological values inherent to the species. At this moment, the horse presented moderate pain episodes, suggesting abdominal origin. Specific evaluation of the digestive system did not show

changes in auscultation. During the paracentesis procedure the presence of abdominal liquid was not observed. However, the animal demonstrated signs of pain during the palpation of the left scrotal sac. For this reason, continuous intravenous lidocaine (0.05mg/kg/min) infusion was administered, after bolus application (5mg/kg).

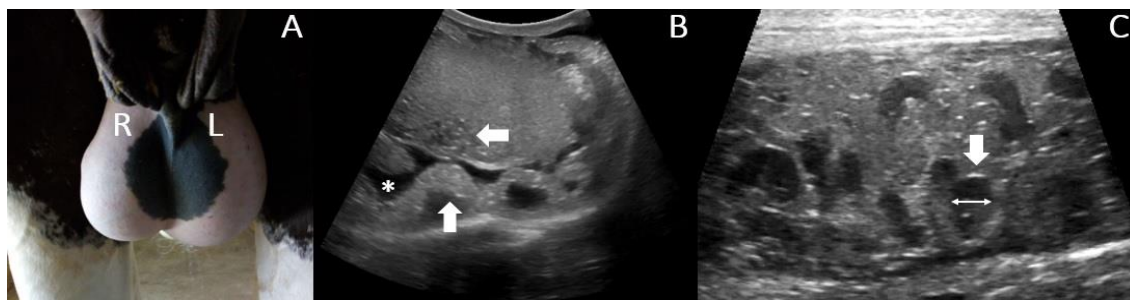


Figure 1. External evaluation and ultrasound imaging of the scrotal region of a 6-year-old Criollo stallion. A: Photograph showing the bilateral scrotal volume increase, with emphasis on the increased volume on the left side (L) in comparison to the right side (R). B: Ultrasound image of the left testis, where the echographic pattern of parenchyma is heterogeneous (horizontal arrow). Also note the accumulation of anechoic fluid (asterisk) and echogenic structure surrounding the testis (vertical arrow). C: Ultrasound image of left pampiniform plexus demonstrating the dilatation (double arrow) and increasing of blood vessel wall thickness (vertical arrow), beyond loss of normal blood vessel arrangement.

Ultrasound evaluation was performed in the scrotal region and it was observed that the parenchyma of the left testis had low echogenicity and heterogeneous pattern, which suggested testicular degeneration. Also, the tail of the epididymis was not visualized in its physiological position, which raised the suspicion of testicular displacement. In addition, there was a hyperechoic structure involving the testis and adhered to it in certain points; however, this structure could not be identified in the ultrasound imaging (Figure 1B). Thus, there was suspicion that the hyperechoic structure was the testicular ligament or that the horse had an inguinoscrotal hernia, whose content could be the omentum. Ultrasound exam of the pampiniform plexus revealed vessel engorgement and moderate anechoic fluid accumulation in the scrotum, which suggested the incidence of varicocele (Figure 1C) and hydrocele, respectively. A color Doppler evaluation was also carried out and did not show signs of ischemia in the testis, although a small degree of blood stasis was observed in the pampiniform plexus.

There was a small amount of anechoic fluid on the right side, as well as characteristics suggesting early testicular degeneration process and slight

loss of homogeneity in the parenchyma pattern. In addition, it was possible seeing an image suggesting the onset of varicocele, with loss of vascular arrangement. Conservative treatment was based on the ultrasound findings, since there was no sign of ischemia of the testicular region and the animal recovered from severe laminitis concomitant with hypoproteinemia. The blood count was repeated after 7 days of hospitalization; results showed persistent thrombocytosis (266,000/ $\mu$ L) and hypoproteinemia (5.4g/dL). Similar results were observed in the evaluation conducted after 14 days of hospitalization; however, protein levels were close to the physiological value (6g/dL). Laminitis was also stabilized, which allowed providing therapeutic shoeing to the animal, who only received firocoxib (0.4mg/kg) as analgesic. However, the stallion had three other pain episodes, which were treated in a similar way to the first one; however, the pain intensity gradually increased.

Due to the worsening of pain episodes, which were probably associated with the hernia, surgical intervention was performed with the purpose of removing the left testis and preserve the right one, as well as to identify the structure observed in the left scrotal region during the ultrasound

examination. The anesthetic protocol consisted of using xylazine (1mg/kg/IV) as a pre-anesthetic medication, induction with ketamine (2mg/kg/IV) in association with midazolam (0.05mg/kg/IV), and anesthesia maintenance with “triple drip” (50mg/ml of guaiaicolglyceryl ether in association with 0.5mg/ml of xylazine and 2mg/ml of ketamine).

In sequence, the animal was placed in left lateral recumbency to allow making a left scrotal incision (approximately 8 centimeters) parallel to the median raphe. The incision was initially made on the skin, and it was followed by the subcutaneous layer, tunica vaginalis and tunica albuginea,

taking care to avoid injuring the underlying structures. The presence of omentum (Figure 2A) and of a large amount of fluid was evidenced at the time when the tunica albuginea was opened. All the scrotal contents were examined; the herniated content involved the testis and was adhered to it at one point (Figure 2B), although there was no sign of ischemia. The testis was flaccid and decreased in size. Then, the animal was subjected to orchietomy on the left testis and, subsequently, to resection of the herniated omentum. Finally, the left inguinal ring was examined and showed no changes.

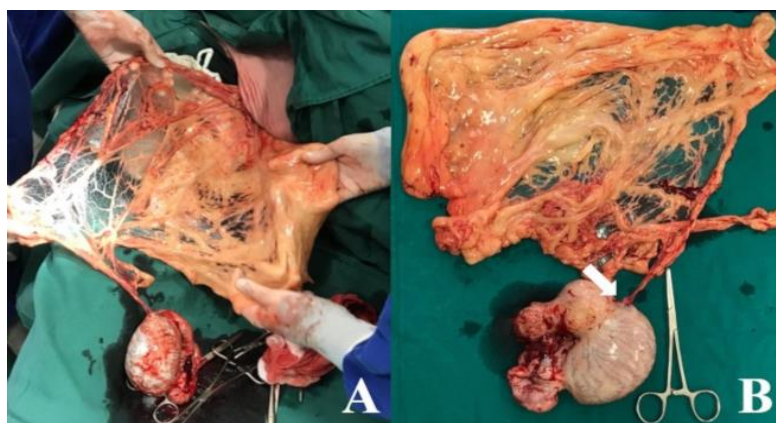

Figure 2. Intraoperative findings during unilateral orchietomy procedure in a Criollo stallion diagnosed with non-strangulated inguinoscrotal hernia. A: Exposure of the herniated content presenting the omentum in the scrotal region. B: Herniated content after omentum excision and left orchietomy. Note the decreased testis size and the adhesion point between the omentum and the testis (white arrow).

The postoperative period consisted in the administration of flunixin meglumine (1.1mg/kg, IV, SID, for 3 days) and ceftiofur (2mg/kg, intramuscularly delivered, SID, for 5 days) and cryotherapy at the incision site for 4 days. Due to edema formation in the scrotal region, the animal was treated with 30-minute cold hosing for 7 days additionally to soft ground walking. After the surgical procedure, samples of the orchietomized testis were subjected to histopathological evaluation. Results showed testicular degeneration, focally extensive interstitial fibrosis, arteritis, reduced lumen in the seminiferous tubules, as well as germinal cell layer disorganization in the testis-omentum adhesion region.

The reproductive management during the hospitalization was based in serial semen collection and ultrasound evaluation of right

testis. The first semen collection and evaluation were conducted 45 days after surgery due to the incidence of laminitis. It was performed with artificial vagina, by placing the animal in quadrupedal position, without mating. The animal presented good libido; 100ml of semen were collected with creamy white color and 5% progressive motility. The sperm concentration was  $116.5 \times 10^6/\text{ml}$  and presented only 4% of living spermatozoa. Therefore, sperm morphology was not evaluated, and the animal was subjected to food supplementation, which mainly comprised vitamins A, B and E, selenium, folic acid, copper, zinc, omega 3 and 6. So, 90 days after the first seminal evaluation, a new semen collection and evaluation was performed based on the mating method and on the artificial vagina. The artificial vagina enabled collecting 30 ml of semen, which showed milky white color and 15% progressive motility. Sperm concentration

was  $121 \times 10^6/\text{ml}$  and presented 11% living spermatozoa. At this time, sperm morphology was also analyzed; results showed 52.7% defects, in total: 45.5% of major defects and 9.2% of minor defects.

The animal was discharged 30 days after the second sperm collection. At the farm, he continued receiving therapeutic shoeing and was kept in soft paddock, whose size increased depending on the animal's adaptation process. During the breeding season in the Southern Hemisphere (from October 1, 2018 to March 30, 2019), the horse owner made the option for setting a herd with 12 mares for the stallion. The animals remained in paddock with easy access to abundant water and pasture. Fifteen (15) months after surgery, and 10 months after the previous andrological evaluation, the stallion was reevaluated based on andrological examination. Testicular palpation was performed; the testicle

presented physiological positioning and fibroelastic consistency.

The right testis was subjected to ultrasound examination; despite the microlithiasis areas, the Figure 3 shows the stabilization of the testicular degenerative process and spermatic cord inflammation, comparing the hospitalization period and the last evaluation. The left scrotal region was well healed, although it presented a small amount of anechoic fluid. On the same occasion, 100% of the mares covered by the stallion were examined and all of them were pregnant. Regarding the laminitis, the horse did not present lameness or pain when he remained in quadrupedal position; his hoof presented a healthy aspect, without stress lines. In Table 1 there is a summary of the details of the clinical case presented.

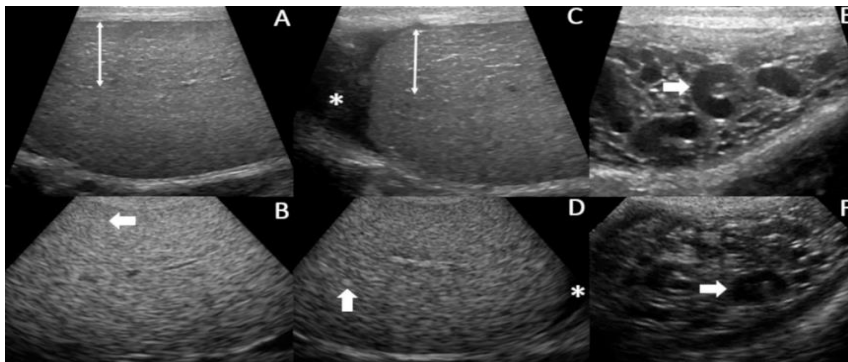


Figure 3. Ultrasonographic images of the right testicle of a Criollo stallion, comparing the imaging findings and demonstrating the clinical evolution between the period of hospitalization of the animal and 15 months after the initial evaluation. A;C: Right testis during hospitalization period. Note the area of multiple stretch marks (double arrow) suggestive of blood stasis secondary to varicocele and presence of moderate anechoic liquid (asterisk) like a hydrocele. B;D: Right testis in the evaluation after discharge of hospital. The white arrows show the microlithiasis area. An asterisk evidence the hydrocele regression. E: Right spermatic cord during hospitalization time evidencing the dilatation of blood vessels and loss of normal blood vessel arrangement. F: Right spermatic cord during the evaluation at the farm. Note that the inflammation did not progress.

## DISCUSSION

Stallions are often diagnosed with inguinoscrotal hernias (Kovac *et al.*, 2018). The incidence of acquired hernias can be attributed to recent events that may cause increased abdominal pressure, such as mating, strenuous exercising and traumas (Southwood, 2013). Thus, it is possible to assume that, in the present case, the muscle tension caused by the pain resulting from the rhabdomyolysis and

laminitis processes may have contributed to protrusion of the omentum to the scrotum.

One of the clinical signs observed in this condition lies on the enlargement of the scrotal volume (Claes and Stout, 2015; Kovac *et al.*, 2018), which is very unspecific, since it is also observed in many of the affections involving the testes and the epididymis (Claes and Stout, 2015). In addition, the affected animals often show signs of acute abdominal pain (Kovac *et al.*, 2018). In this case,

the horse only presented increased scrotal volume; he did not have history or showed signs of abdominal pain at hospitalization time. Thus, the first diagnostic suspicion lied on hydrocele secondary to the prolonged use of phenylbutazone. It happened because

hypoproteinemia, which stood out among the blood evaluation findings, can be observed during treatments based on this drug (Reed *et al.*, 2006) and it is considered one of the causes of hydrocele (Edwards, 2008).

Table 1. Main clinical signs, imaging findings, andrological changes and treatments on the Criollo stallion with non-strangled inguinoscrotal hernia since the first evaluation on the farm to post hospital discharge findings

	Time (days)	Historical/Clinical signs	Blood tests	Imaging findings	Andrological exam	Diagnostic/Treatment
Pre-hospitalization	Around 60 days	Rhabdomyolysis and laminitis ↑ Scrotal volume	-	-	-	NSAIDs e antibiotics <sup>1</sup>
Pre surgical	D0 - D18	Locomotion difficulty ↑ Scrotal volume (↑↑ left antimere) Moderate pain on palpation of inguinal ring ↓ Left testicular size Suggestive abdominal pain episodes (mild to moderate)	Hypoproteinemia Hyperfibrinogenemia Trombocytosis	Left testis parenchyma changes Bilateral hydrocele Not identified hyperechoic structure involving the left testis	-	Laminitis (analgesics, peripheral vasodilator, gastric protector, hoof care) Non strangled inguinal-scrotal hernia (continuous lidocaine infusion for pain episodes)
Surgical	D19	Same as pre surgical	Mild hypoproteinemia	Equal as pre surgical	-	Non strangled inguinal-scrotal hernia (left unilateral orchiectomy and removal of herniated omentum)
	D20 – D65	Laminitis stabilization Post-surgical scrotal edema	Hypoproteinemia	-	Good libido 5% of PM <sup>2</sup> 4% of live sperm 116.5 x 10 <sup>6</sup> sperm/ml	Laminitis (same as above) Post-surgical care
Post-surgical	D66 - D155	Laminitis stabilization	-	-	Good libido 15% of PM <sup>2</sup> 11% of live sperm 45.5% major defects 9.2% minor defects	Laminitis (same as above) Testicular changes (vitamins A, B and E, selenium, folic acid, copper, zinc, omega 3 and 6) Therapeutic shoeing
	D156 – D185	Laminitis stabilization Hospital discharge	-	-	-	
Post-discharge	10 months after discharge	Keep on soft paddock	-	Small microlithiasis areas on the right testis	100% of pregnancy rates Physiological consistency and positioning of the right testis	-

<sup>1</sup> Treatment performed by the farm veterinarian; <sup>2</sup> MP = progressive motility

Signs of abdominal pain were only observed a few days after hospitalization; they were controlled through continuous lidocaine infusion, since this drug has analgesic effect on horses presenting visceral pain, without having undesirable effects on their motility (Robertson *et al.*, 2005). Hydrocele persistence, in association with pain events, suggested the incidence of non-strangulated hernia, despite the improved hypoproteinemia. In this case it was possible to consider the occurrence of peritonitis due to the recurrent episodes of pain, yet the clinical

evaluation was not suggestive of this disease, because commonly the affected horses presenting inappetence, pyrexia (Browning, 2014) and productive paracentesis (Bach and Ricketts, 1974). Thus, ultrasound evaluation was the complementary method chosen to assist in the definitive diagnosis; the B mode was used to investigate the presence or absence of intestinal loops in the scrotum (Claes and Stout, 2015), and the color Doppler was used to investigate whether the vascularization of the testis had been

compromised (Pozor and McDonell, 2004; Claes and Stout, 2015).

The imaging findings suggested left inguinoscrotal hernia, as well as that the intestinal loops were not the content of it; however, it was not possible to identify the observed structure in the ultrasound examination. Besides these findings, there were also changes in the pattern of the testicular parenchyma on the left side, which is physiologically homogeneous (Cardilli *et al.*, 2010). This aspect, in association with the palpation of the region, suggested the incidence of left testicular degeneration. Thus, left unilateral orchiectomy was performed in order to reverse the right testicular degeneration and to identify the hernial content observed in the ultrasound imaging. The orchiectomy enabled such identification and allowed seeing that the hernial content was a portion of the omentum, although it is atypical, since segments of the small intestine are the hernial content in most cases (Kovac *et al.*, 2018). Other intestinal loops can be found in the hernial sac; among them, one finds the large colon (Ivens *et al.*, 2009; Robinson and Carmalt, 2009), in addition to other organs such as the bladder (Cousty *et al.*, 2010). However, in these cases, the horses were small-sized breed foals, whereas the animal in the present case report was an adult Criollo stallion.

Nevertheless, it is relatively common to find herniated omentum in male horses after the orchiectomy procedure (Schumacher, 2006), unlike the horse in the present case, who did not undergo such surgical procedure prior to hospitalization. In this report, the herniated omentum was resected and the animal presented favorable prognosis, which corroborated with the treatment described for omental hernia cases, as well as for the prognosis involving this affection (Searle *et al.*, 1999; Schumacher, 2006). Another relevant matter in cases of inguinal hernias is the decision to reduce the inguinal ring, which must be done in all cases of changes in such ring (Van der Velden, 1988; Wilderjans *et al.*, 2009); the present case did not present such changes, so that suture was not performed.

The surgical treatment was also focused on reversing the initial testicular degeneration process observed in the right testis. The adopted surgical technique is often used in animals presenting one of the testes affected (Shoemaker

*et al.*, 2004). A possible disadvantage of such technique is the deleterious action of post-surgical thermal stress on the remaining testis (Schumacher *et al.*, 1988). The present report observed scrotal edema formation during the postoperative period, and it was reversed through postoperative care. Nevertheless, the inflammatory process can be associated with unfavorable results of the first seminal evaluation.

It is known that spermatogenesis can become normal as soon as the thermal injury period ends (Blanchard *et al.*, 2000); however, it is a time-consuming process, which presents gradual seminal viability improvement and tends to show slight changes in the first 60 days (McCormick *et al.*, 2012). This condition could be observed in the evaluated horse, who presented reproductive improvement based on the comparison between two seminal evaluations. In addition, good results at the end of the breeding season suggested that spermatogenesis was effectively recovered.

## CONCLUSIONS

The incidence of omentum as content of non-strangulated inguinoscrotal hernias showed favorable prognosis regarding the stallion's life and it did not represent an emergency surgery case. However, local inflammatory processes can lead to poor reproductive prognosis. Thus, the removal of both the herniated content and inflammatory factors produced by the affected testis may have benefited the reproductive function of the stallion, although it requires prolonged recovery time.

## ACKNOWLEDGMENTS

This study was financed in part by the Coordenação de Aperfeiçoamento de Pessoal de Nível Superior - Brasil (CAPES) - Finance Code 001.

## REFERENCES

- BACH, L.G.; RICKETTS, S.W. Paracentesis as an aid to the diagnosis of abdominal disease in the horse. *Equine Vet. J.*, v.6, p.116-121, 1974.
- BLANCHARD, T.; VARNER, D.; JOHNSON, L. *et al.* Testicular and hormonal changes in stallions with thermally induced testicular degeneration. *J. Reprod. Fertil.*, v.56, p.51-59, 2000.



- BROWNING, A. Diagnosis and management of peritonitis in horses. *In Practice*, v.27, p.70-75, 2014.
- CARDILLI, D.J.; TONIOLLO, G.H.; PASTORE, A.A. *et al.* Padrão ultrassonográfico do parênquima, mediastino e túnicas testiculares em bovinos jovens da raça nelore. *Ciênc. Anim. Bras.*, v.11, p.899-905, 2010.
- CLAES, A.N.J.; STOUT, T.A.E. The diagnostic challenge of scrotal enlargement in the stallion. *Equine Vet. Educ.*, v.27, p.116-118, 2015.
- COUSTY, M.; TRICAUD, C.; PICANDET, V.; GEFFROY, O. Inguinal rupture with herniation of the urinary bladder through the scrotal fascia in a Shetland pony foal. *Equine Vet. Educ.*, v.22, p.3-6, 2010.
- EDWARDS, J.F. Pathologic conditions of the stallion reproductive tract. *Anim. Reprod. Sci.*, v.107, p.197-207, 2008.
- IVENS, P.A.S.; PIERCY, R.J.; ELIASHAR, E. Inguinal herniation of the large colon in a cobgelding four weeks after castration. *Vet. Rec.*, v.165, p.380-381, 2009.
- KOVAC, M.; ALIEV, R.; IPPOLITOVA, T.; TAMBUR Z. Equine acquired inguinal herniation – diagnosis and treatment in 62 cases. *Vet. Glasnik*, v.72, p.22-34, 2018.
- MCCORMICK, J.D.; VALDEZ, R.; RAKESTRAW, P.C. *et al.* Effect of surgical technique for unilateral orchiectomy on subsequent testicular function in Miniature Horse stallions. *Equine Vet. J.*, v.43, p.100-104, 2012.
- POZOR, M.A.; MCDONELL, S.M. Color Doppler ultrasound evaluation of testicular blood flow in stallions. *Theriogenology*, v.61, p.799-810, 2004.
- REED, S.K.; MESSER, N.T.; TESSMAN, R.K.; KEEGAN, K.G. Effects of phenylbutazone alone or in combination with flunixin meglumine on blood protein concentrations in horses. *Am. J. Vet. Res.*, v.67, p.398-402, 2006.
- ROBERTSON, S.A.; SANCHEZ, L.C.; MERRIT, A.M.; DOHERTY, T.J. Effect of systemic lidocaine on visceral and somatic nociception in conscious horses. *Equine Vet. J.*, v.37, p.122-27, 2005.
- ROBINSON, E.; CARMALT, J.L. Inguinal herniation of the ascending colon in a 6-month-old Standardbred Colt. *Vet. Surg.*, v.38, p.1012-13, 2009.
- SCHUMACHER, J. Testis. In: AUER, J.A.; STICK, J.A. (Eds.). *Equine surgery*. Philadelphia: Saunders Elsevier, 2006. p.775-810.
- SCHUMACHER, J.; SCHUMACHER, J.; SPANO, J.S. Effects of castration on peritoneal fluid in the horse. *J. Vet. Intern. Med.*, v.2, p.22-25, 1988.
- SEARLE, D.; DART, A.J.; DART, C.M.; HODGSON, D.R. Equine castration: review of anatomy, approaches, techniques and complications in normal, cryptorchid and monorchid horses. *Aust. Vet. J.*, v.77, p.428-444, 1999.
- SHOEMAKER, R.; BAILEY, J.; JANZEN, E.; WILSON, D.G. Routine castration in 568 draught colts: incidence of evisceration and omental herniation. *Equine Vet. J.*, v.36, p.336-340, 2004.
- SOUTHWOOD, L.L. Special considerations. In: \_\_\_\_\_. (Ed.) *Practicalguide to equine colic*. New York: Wiley-Blackwell, 2013. p.278-291.
- STICK, J.A. Abdominal hernias. In: AUER, J.A.; STICK, J.A. (Eds.). *Equine surgery*. Philadelphia: Saunders Elsevier, 2006. p.491-499.
- VAN DER VELDEN, M.A. Surgical treatment of acquired inguinal hernia in the horse: a review of 51 cases. *Equine Vet. J.*, v.20, p.173-177, 1988.
- WILDERJANS, H.; SIMON, O.; BOUSSAW B. Manual closed non-surgical reduction of strangulated inguinal hernias in stallions. In: CONGRESS OF WORLD EQUINE VETERINARY ASSOCIATION, 11., 2009, Guarujá. *Proceedings...* Guarujá: [s.n.], 2009. p.1-7. (Abstract).