

Communnication

[Comunicação]

Occurrence *Angiostrongylus vasorum* (Baillet, 1866) (Nematoda, Angiostrongylidae) in *Cerdocyon thous* Linnaeus, 1766 (Carnivora, Canidae) in Minas Gerais State Brazil

[Ocorrência de *Angiostrongylus vasorum* (Baillet, 1866) (Nematoda, Angiostrongylidae) em *Cerdocyon thous* (Linnaeus, 1766) (Carnivora, Canidae) no Estado de Minas Gerais]

F.H. Duarte^{1,3}, F.M. Vieira^{2*}, G.L. Louzada², E.C.A. Bessa¹, S. Souzalima²,

¹Aluno de pós-graduação - ICB-UFJF – Juiz de Fora, MG

²Departamento de Zoologia – ICB – UFJF

36036-330 - Juiz de Fora, MG

³Bolsista da FAPEMIG

Angiostrongylus vasorum (Baillet, 1866) Kamensky, 1905 (Nematoda, Angiostrongylidae), commonly named the French heartworm, is a worldwide parasite of the pulmonary arteries and right ventricle, atrium and auricle of both domestic and wild canids (Bessa et al., 2000).

In Brazil, reports of domestic canids naturally infected by *A. vasorum* have been made by Gonçalves (1961) in Rio Grande do Sul, Langenegger et al. (1962) in Rio de Janeiro, Giovanonni et al. (1985) in Paraná and Lima et al. (1985) in Minas Gerais. In wild Brazilian canids, this nematode has been reported parasitizing the lungs of *Dusicyon vetulus* (Lund, 1842) in Minas Gerais (Lima et al., 1994) and the right ventricle and pulmonary arteries of *Cerdocyon thous* Linnaeus, 1766, in Rio de Janeiro (Travassos, 1927).

Among the studies on helminthofauna in *C. thous* (Ruas et al., 2003; Satos et al., 2003, 2004), the only report of *A. vasorum* was made by Travassos (1927).

The objective of the present study is to report the occurrence of *A. vasorum* in *C. thous* in Minas Gerais State and also provides data on the ecology of *A. vasorum* in these hosts.

Necropsies were performed in six *C. thous* killed by cars in the municipality of Juiz de Fora, MG.

The specimens were collected between 2000 and 2004. The hearts and lungs were weighed and, then, dissected on plastic trays containing 0.85% physiologic solution. Then, the nematodes were fixed in AFA (ethyl alcohol 70° GL, 93 parts; formalin 37%, five parts; glacial acetic acid, two parts) for 48 hours and placed in 70% ethyl alcohol with 5% glycerin. For species identification, the specimens were clarified in Lactophenol and mounted according to Amato et al. (1991). They were identified according to Kinsella (1971), Ubelaker (1986) and Bessa et al. (2000). The ecological analyses were carried out according to Bush et al. (1997) and Zuben (1997).

In the present study, *A. vasorum* was found in the lungs and right atrium of *C. thous*, with a prevalence of 50%, mean abundance 4±4.47, mean intensity 8±3.00 and sex ratio (male/female) 1:1.19. The *A. vasorum* infrapopulations presented an aggregated spatial distribution pattern (ID=5.70 and K=0.355) and the population components were composed of 24 specimens.

The *A. vasorum* specimens found had a whitened coloration when recently collected. The cuticle was fine and transparent, beneath it the helicoidal shape of the genital organs could be seen wrapped around the digestive tube. The anterior extremity was rounded with a buccal aperture

Recebido em 11 de julho de 2006

Aceito em 18 de abril de 2007

*Corresponding author (autor para correspondência)

E-mail: fmatosvieira@gmail.com

surrounded by three pairs of cephalic pupillae (Fig. 1B). They had a small buccal cavity (Fig. 1B) and the esophagus was claviform (Fig. 1A). The excretory pore was located near to esophagus-intestinal junction (Fig. 1A). The female was larger and more robust than the male and the vulva was near the tail, which was short and had a rounded posterior extremity, with a cuticular expansion in the form of a sheath that protruded (Fig. 1C). The males had a small but distinct copulatory bursa, with two symmetric lateral lobes (Fig. 1E). The ventral rays originated from a common trunk and diverged at the extremities. The ventro-ventral ray was slightly smaller than the ventro-lateral one. The lateral rays also originated from a common

trunk; the anterior lateral ray diverged near the base and the medial and posterior lateral rays continued fused until the final third, where they diverged. The lateral dorsal rays originated separately from the medial dorsal, which was shorter and thicker and had two well-defined digits (Fig. 1D). The spicules (Fig. 1E) were long with transversal striations. These descriptions agreed with those of Kinsella (1971), Ubelaker (1986) and Bessa et al. (2000).

This is the first report of the presence of *A. vasorum* in *C. thous* in Minas Gerais State, the first occurrence of this nematode in either domestic or wild animals in Juiz de Fora county.

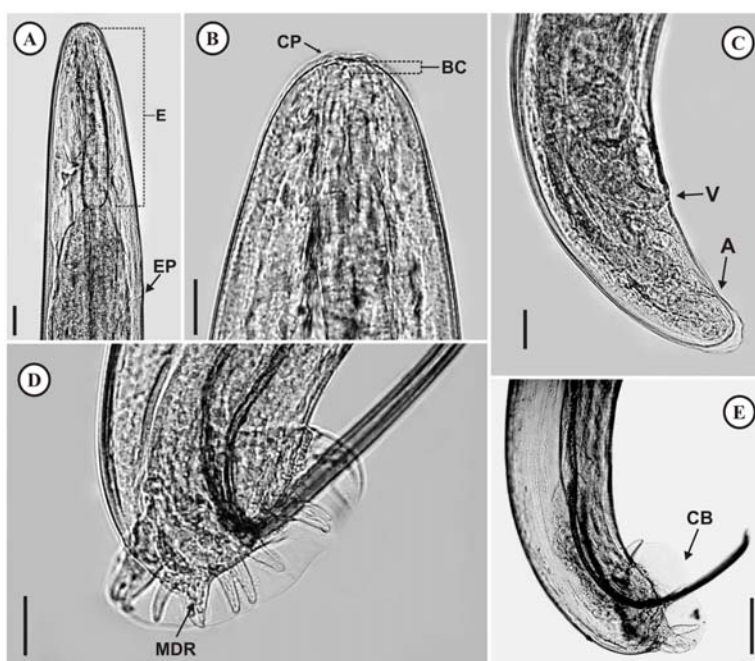


Figure 1. *Angiostrongylus vasorum*. A) Anterior region (scale: 40 μ m); B) anterior extremity (scale: 30 μ m); C) female posterior region (scale: 70 μ m); D) male copulatory bursa (scale: 20 μ m); E) male posterior region (scale: 40 μ m) (A: anus; CB: copulatory bursa; CP: cephalic pupillae; E: esophagus; EP: excretory pore; V: vulva; MDR: medial dorsal ray).

RESUMO

Registrou-se a ocorrência de *A. vasorum* em *C. thous* no Estado de Minas Gerais, e estudaram-se aspectos de sua ecologia nessa população de hospedeiros. A partir da necropsia de seis espécimes, observou-se a presença de *A. vasorum* nos pulmões e átrio direito de *C. thous*. No total foram coletados 24 espécimes de *A. vasorum*, com prevalência de 50%, abundância média de 4 \pm 4,47, intensidade média de 8 \pm 3,00 e razão sexual (machos/fêmeas) de 1:1,19. As infrapopulações de *A. vasorum* apresentaram padrão de distribuição espacial agregado (ID=5,70 e K=0,355). Este é o primeiro registro de *A. vasorum* em *C. thous* no estado, descrito no município de Juiz de Fora.

Palavras-chave: *Angiostrongylus vasorum*, Nematoda, *Angiostrongylidae*, *Cerdocyon thous*, *Canidae*

REFERENCES

- AMATO, J.F.R.; BOEGER, W.; AMATO, S.B. *Protocolos para laboratório: coleta e processamento de parasitos de pescado*. Rio de Janeiro: Imprensa Universitária, UFRRJ, 1991. 81p.
- BESSA, E.C.A.; LIMA, W.S.; DAEMON, E. et al. Desenvolvimento biológico de *Angiostrongylus vasorum* (Baillet) Kamensky (Nematoda, Angiostrongylidae) em *Subulina octona* Bruguière (Mollusca, Subulinidae) em condições de laboratório. *Rev. Bras. Zool.*, v.17, p.29-42, 2000.
- BUSH, A.O.; LAFFERTY, K.D.; LOTE, J.M. et al. Parasitology meets ecology own terms: MARGOLIS et al. *Revisited*. *J. Parasitol.*, v.83, p.575-583, 1997.
- GIOVANONNI, M.; FERNANDES, B.F.; KAVINSKY, L.C. Angiostrongilose do cão. *Arq. Biol. Tecnol.*, v.28, p.601-604, 1985.
- GONÇALVES, P.C. *Angiostrongylus vasorum* (Baillet, 1866) novo parasito do cão no Rio Grande do Sul (Brasil) – Nematoda, Metastrongyloidea. *Rev. Fac. Agron. Vet.*, v.4, p.35-40, 1961.
- KINSELLA, J.M. *Angiostrongylus schmidtii* sp. n. (Nematoda: Metastrongyloidea) from the rice rat, *Oryzomys palustris*, in Florida, with a key the species of *Angiostrongylus* Kamensky, 1905. *J. Parasitol.*, v.57, p.494-497, 1971.
- LANGENEGGER, J.; LANGENEGGER, A.M.; DACORSO FILHO, P. et al. Ocorrência da infestação por *Angiostrongylus vasorum* em cães do Rio de Janeiro. In: CONGRESSO BRASILEIRO DE VETERINARIA, 8., 1962, Belo Horizonte. *Anais...* Belo Horizonte, 1962. p.246-247. (Resumo).
- LIMA, W.S.; COSTA, H.M.A.; GUIMARÃES, M.P. et al. *Angiostrongylus vasorum* (Baillet, 1866) (Nematoda, Protostrongylidae) em cães de Minas Gerais, Brasil. *Mem. Inst. Oswaldo Cruz*, v.80, p.233-235, 1985.
- LIMA, W.S.; GUIMARÃES, M.P.; LEMOS, I.S. Occurrence of *Angiostrongylus vasorum* in the lungs of the Brazilian fox *Dusicyon vetulus*. *J. Helminthol.*, v.68, p.87, 1994.
- RUAS, J.L.; SOARES, M.P.; FARIAS, N.A.R. et al. Infecção por *Capillaria hepatica* em carnívoros silvestres (*Lycalopes gymnocercus* e *Cerdocyon thous*) na região sul do Rio Grande do Sul. *Arq. Inst. Biol.*, v.70, p.147-150, 2003.
- SANTOS, K.R.; CATENACCI, L.S.; PESTELLI, M.M. et al. First report of *Diphyllobothrium mansoni* (Cestoda, Diphyllobothridae) infecting *Cerdocyon thous* (Mammalia, Canidae) in Brazil. *Arq. Bras. Med. Vet. Zootec.*, v.56, p.796-798, 2004.
- SANTOS, K.R.; CATENACCI, L.S.; PESTELLI, M.M.; et al. First report of *Ancylostoma buckleyi* Le Roux and Biocca, 1957 (Nematoda: Ancylostomatidae) infecting *Cerdocyon thous* Linnaeus, 1766 (Mammalia: Canidae) from Brazil. *Rev. Bras. Parasitol. Vet.*, v.12, p.179-181, 2003.
- TRAVASSOS, L. Novos nematódeos. *Bol. Biol.*, v.6, p.52-61, 1927.
- UBELAKER, J.E. Systematics of species referred to the genus *Angiostrongylus*. *J. Parasitol.*, v.72, p.237-244, 1986.
- ZUBEN, C.J.V. Implicações da agregação espacial de parasitas para a dinâmica populacional na interação hospedeiro-parasita. *Rev. Saúde Publ.*, v.31, p.523-530, 1997.