

# Benign familial fleck retina: multimodal imaging including optical coherence tomography angiography

## *Benign familial fleck retina: estudo multimodal incluindo OCT angiography*

JOSE MAURICIO BOTTO DE BARROS GARCIA<sup>1</sup>, DAVID LEONARDO CRUVINEL ISAAC<sup>1</sup>, TAINARA SARDEIRO<sup>1</sup>, ÉRIKA AQUINO<sup>1</sup>, MARCOS AVILA<sup>1</sup>

### ABSTRACT

This report presents multimodal imaging of a 27-year-old woman diagnosed with benign familial fleck retina (OMIM 228980), an uncommon disorder. Fundus photographs revealed retinal flecks that affected her post-equatorial retina but spared the macular area. Fundus autofluorescence and infrared imaging demonstrated a symmetrical pattern of yellow-white fleck lesions that affected both eyes. Her full-field electroretinogram and electrooculogram were normal. An optical coherence tomography B-scan was performed for both eyes, revealing increased thickness of the retinal pigmented epithelium leading to multiple small pigmented epithelium detachments. The outer retina remained intact in both eyes. Spectral-domain optical coherence tomography angiography with split-spectrum amplitude decorrelation algorithm and 3 × 3 mm structural en face optical coherence tomography did not show macular lesions. Benign familial fleck retina belongs to a heterogenous group of so-called flecked retina syndromes, and should be considered in patients with yellowish-white retinal lesions without involvement of the macula.

**Keywords:** Eye diseases, hereditary/genetics; Eye diseases, hereditary/diagnosis; Retinal diseases/diagnosis; Retinal diseases/genetics; Tomography, optical coherence

### RESUMO

O objetivo do presente relato é demonstrar um estudo multimodal de um paciente com diagnóstico de Benign Familiar Fleck Retina (BFFR) (OMIM 228980), uma alteração retiniana muito rara. Retinografia colorida demonstrou "flecks" na retina posterior ao equador, poupando mácula. Tanto autofluorescência quanto imagem "infravermelho," nota-se padrão simétrico de lesões amareladas em ambos os olhos. Eletroretinograma padrão de campo total e EOG não evidenciaram alterações. SD OCT B-scan demonstrou pequenos e múltiplos descolamentos do epitélio pigmentado (EPR), com retina externa intacta em ambos os olhos. Angiografia por OCT com "split-spectrum amplitude decorrelation algorithm" e "structural" "en face" OCT 3 × 3 mm não apontaram anormalidades na mácula. BFFR pertence ao heterogêneo grupo chamado "flecked retina syndromes," devendo ser considerada em pacientes com flecks retinianos poupando mácula.

**Descritores:** Oftalmopatias hereditárias/diagnóstico; Oftalmopatias hereditárias/genética; Doenças retinianas/diagnóstico; Doenças retinianas/genética; Tomografia de coerência óptica

### INTRODUCTION

Benign familial fleck retina (BFFR) (OMIM 228980) is a congenital abnormality characterized by multifocal yellowish retinal infiltrates involving the post-equatorial retina<sup>(1,2)</sup>. Aish and Dajani introduced this term in 1980 to distinguish the condition from similar disorders with distinctive clinical presentations, including fundus albipunctatus, fundus flavimaculatus, and others<sup>(2-5)</sup>. Most of these are associated with an altered electroretinogram (ERG) and abnormal perimetry, with peripheral constriction to the central field<sup>(3)</sup>. In contrast, the ERG is normal in BFFR, and the patient has no symptoms<sup>(2)</sup>.

The flecks are located at the level of the retinal pigment epithelium (RPE), extending to the far periphery but sparing the macula<sup>(6,7)</sup>. Here we report a young patient diagnosed with BFFR.

### CASE REPORT

A 27-year-old woman was referred for a regular ophthalmic examination. Her visual acuity was 20/20 OU and there were no abnor-

malities in slit-lamp biomicroscopy. Fundus photographs in both eyes displayed multiple, small, bilateral, symmetrical retinal flecks that affected the post-equatorial retina but spared the macular region (Figure 1). No family members were affected, and there was no history of consanguinity between the parents.

Increased autofluorescence corresponding to retinal flecks was observed in the infrared image (Figure 2). Fluorescein angiography showed a healthy macula with hypofluorescent spots related to pigment clumps; these extended to the far periphery but without macular injury. ERGs were recorded under scotopic and photopic conditions and were normal except for the selective reduced amplitude of oscillatory potentials (Figure 3). Electrooculograms revealed light peak/dark trough ratios (Arden ratios) of 1.9 in the right eye and 2.0 in the left eye (Figure 3). The patient's macula was tested with a spectral domain (SD) optical coherence tomography (OCT) B-scan and SD-OCT angiography, using an Avanti RTVue XR with AngioVue® software (Optovue, Inc., Fremont, CA). The imaging data were obtained using split-spectrum amplitude-decorrelation angiography

Submitted for publication: March 10, 2017

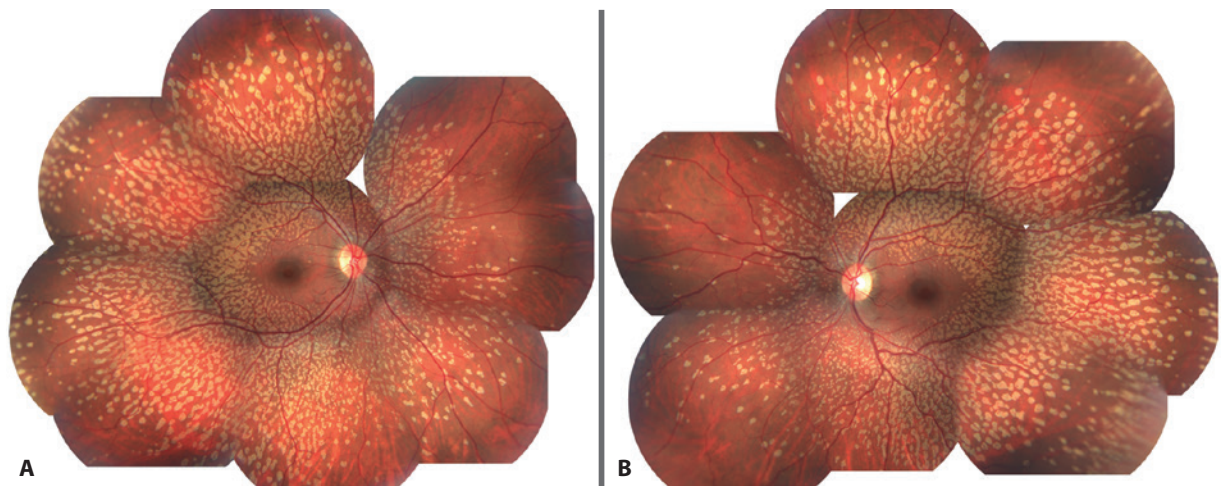
Accepted for publication: June 13, 2017

<sup>1</sup> Universidade Federal de Goiás, Goiânia, GO, Brazil.

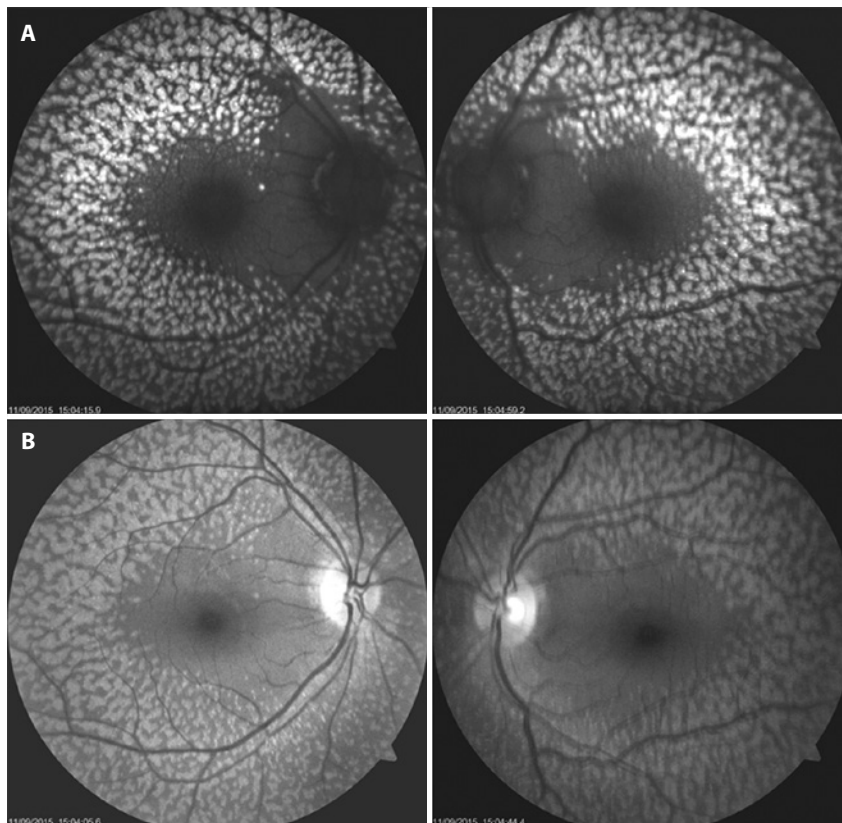
**Funding:** No specific financial support was available for this study.

**Disclosure of potential conflicts of interest:** None of the authors have any potential conflict of interest to disclose.

**Corresponding author:** Jose Mauricio Botto de Barros Garcia. Rua 234, 38/1011 - Setor Leste Universitário - Goiânia, GO - 74605-020 - Brazil - E-mail: zemaucio20@hotmail.com



**Figure 1.** A and B) Fundus photographs showing numerous yellowish flecks that affected the post-equatorial retina but spared the macula.



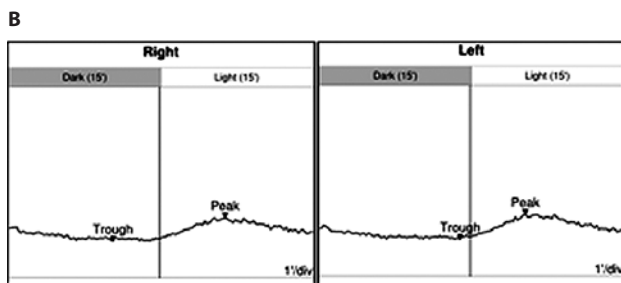
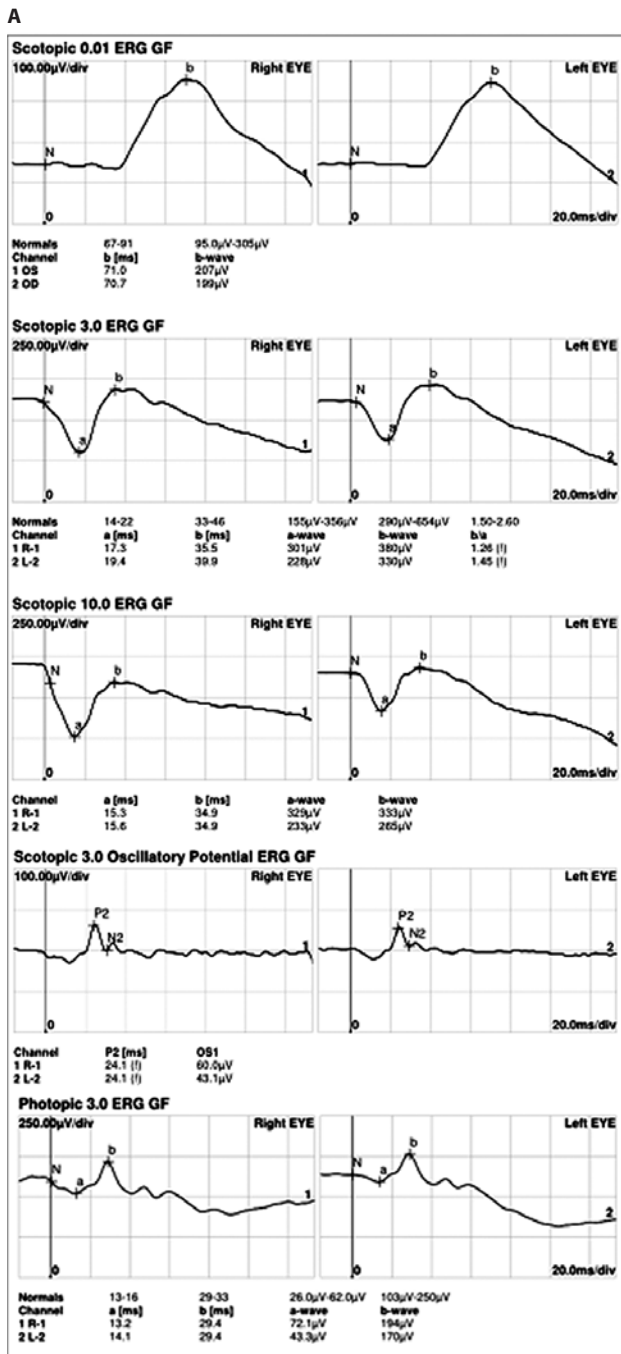
**Figure 2.** A) Fundus autofluorescence demonstrating a symmetrical pattern of yellow-white fleck lesions that affected both fundi. B) Infrared imaging showing the same configuration.

software. The testing demonstrated a normal foveal structure with increased thickness of the RPE in both eyes. The 3 × 3 mm SD-OCT angiography showed no macular injury from the outer retina to the choriocapillaris slab in both eyes. Projection artifacts were removed using a default proprietary algorithm (Figure 4). At a follow-up examination 18 months later, the patient continued to have no ocular symptoms.

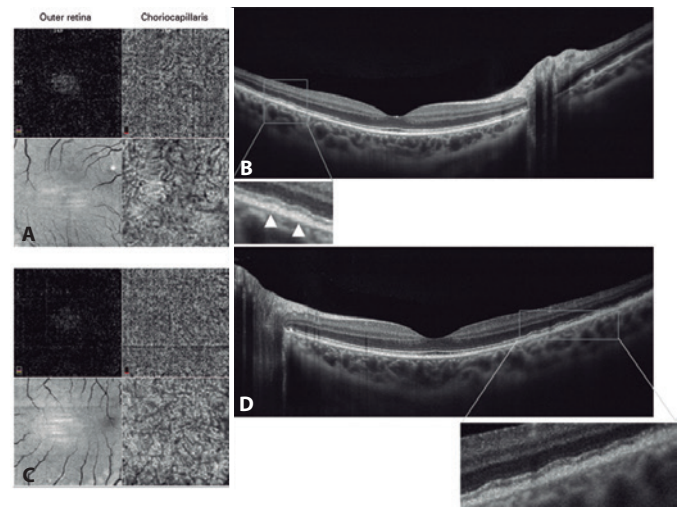
## DISCUSSION

The patients' phenotype resembled that of BFFR described by Aish and Dajani in 1980<sup>(1)</sup>, an extremely uncommon condition<sup>(2)</sup>. Since the original description of a family with benign fleck retina, only three sporadic cases have been reported<sup>(2,7)</sup>.

Some authors have postulated that flecks do not only represent a typical ophthalmic characteristic but may also correspond, in some



**Figure 3.** A) Standard full-field electroretinogram elicited by various stimulus intensities in scotopic and photopic conditions with no abnormalities. B) Electrooculogram recordings. The light peak/dark trough ratio (Arden ratio) was 1.9 in the right eye and 2.0 in the left eye.



**Figure 4.** Optical coherence tomography (OCT) angiography with a split-spectrum amplitude decorrelation algorithm and structural en face OCT 3 x 3 mm (A and C), which showed no macular injury from the outer retina to the level of choroid capillary in both eyes. The OCT B-scan (B and D) demonstrated a slight increase in the thickness of the retinal pigment epithelium, leading to multiple small pigmented epithelium detachments. The enlarged images of the boxed regions show the outer retina and retinal pigment epithelium of both eyes in detail. The hyperreflective band corresponding to the photoreceptor inner/outer segment junction remained intact in both eyes.

patients, to retinal damage that contributes to loss of vision<sup>(4)</sup>. It has been suggested that the flecks may be related to mutations in *PLA2G5*<sup>(8,9)</sup>.

Flecked retina syndromes encompass a group of diseases that include Stargardt's macular dystrophy, fundus albipunctatus, retinitis punctata albescens, Leber congenital amaurosis, pseudoxanthoma elasticum, Kjellin's syndrome, Alport's syndrome, Sjögren-Larsson syndrome, Bietti's crystalline dystrophy, oxalosis, and cystinosis<sup>(8-10)</sup>. It has been suggested that the flecks' hyperautofluorescence in Stargardt's macular dystrophy (OMIM 601691) may represent a precursor of photoreceptor death and RPE atrophy; this contradicts the definition of BFFR, but further studies are needed to confirm this in other diseases.

This report describes a sporadic case of BFFR and presents the standard full-field ERG, electrooculogram, fundus autofluorescence imaging, SD OCT B-scan, and SD OCT angiography findings for this condition.

## REFERENCES

1. Aish SF, Dajani B. Benign familial fleck retina. *Br J Ophthalmol.* 1980;64(9):652-59.
2. Isaacs TW, McAllister IL, Wade MS. Benign fleck retina. *Br J Ophthalmol.* 1996;80(3):267-8.
3. Walia S, Fishman GA, Kapur R. Flecked-retina syndromes. *Ophthalmic Genet.* 2009;30(2):69-75.
4. Verdina T, Tsang SH, Greenstein VC, Zernant J, Sodi A, Lima LH, et al. Functional Analysis of Retinal Flecks in Stargardt Disease. *J Clin Exp Ophthalmol.* 2012 Jul 30;3. doi: 10.4172/2155-9570.1000233.
5. Flynn MF, Bohnert D. Fundus albipunctatus and other flecked retina syndromes. *J Am Optom Assoc.* 1999;70(9):571-80.
6. Audo I, Tsang SH, Fu AD, Barnes JA, Holder GE, Moore AT. Autofluorescence imaging in a case of benign familial fleck retina. *Arch Ophthalmol.* 2007;125(5):714-5.
7. Galindo-Ferreiro A, Sanabria MR, Garcia EP, Coco-Martin RM, Galindo-Alonso J, Palencia-Ercilla J. Benign fleck retinal findings on multifocal ERG, microperimetry, and OCT. *Ophthalmic Surg Lasers Imaging.* 2010 Oct 28;41 Online:e1-5. doi: 10.3928/15428877-20101025-05.
8. Sergouniotsis PI, Davidson AE, Mackay DS, Lenassi E, Li Z, Robson AG, Yang X, et al. Biallelic mutations in *PLA2G5*, encoding group V phospholipase A2, cause benign fleck retina. *Am J Hum Genet.* 2011;89(6):782-91.
9. Bin NJ, Heng HM, Poh R, Noor SM, Subrayan V. Phospholipase A2 group v in benign familial fleck retina in a set of triplets. *Retina.* 2015;35(6):1266-72.