

Epiretinal membrane formation associated with idiopathic macular telangiectasia: case report

Formação de membrana epirretiniana associada a telangiectasia macular idiopática: relato de caso

FLÁVIA CID GOMES¹, JOÃO PAULO FERNANDES FELIX¹, MAURÍCIO ABUJAMRA NASCIMENTO¹, RODRIGO PESSOA CAVALCANTI LIRA¹

ABSTRACT

A 46-year-old woman complained of blurred and distorted vision in both eyes. Ophthalmic examination showed that visual acuity was 20/200 for the right eye and counting fingers left eye. Fundoscopy revealed perimacular hemorrhages, aneurismal dilatation of the vessels in the posterior pole, and a white and elevated lesion adjacent to vascular changes. We report a case of idiopathic macular telangiectasia and epiretinal membrane that occurs concomitantly. To our knowledge, this is the first report that describes an association between idiopathic macular telangiectasia and epiretinal membrane formation.

Keywords: Telangiectasia; Epiretinal membrane; Retina/cytology; Diagnostic techniques, ophthalmological; Fluorescein angiography; Humans; Female; Adult; Case reports

RESUMO

Paciente feminina de 46 anos apresentando queixa de embaçamento visual e visão distorcida em ambos os olhos. Ao exame oftalmológico, sua acuidade visual era 20/200 no olho direito e conta dedos a 5 metros no olho esquerdo. A fundoscopia revelou hemorragias perimaculares, dilatação aneurismática dos vasos no polo posterior e uma lesão elevada e esbranquiçada ao lado das alterações vasculares. Relatamos um caso de telangiectasia macular idiopática e membrana epirretiniana que ocorreram concomitantemente. Até o momento, não existem relatos de associação entre telangiectasia macular e membrana epirretiniana.

Descritores: Telangiectasia; Membrana epirretiniana; Retina/citologia; Técnicas de diagnóstico oftalmológico; Angiofluoresceinografia; Humanos; Feminino; Adulto; Relatos de casos

INTRODUCTION

Macular telangiectasia (MacTel), also known as idiopathic juxtafoveal telangiectasia, is a rare ocular disease that can lead to legal blindness. This disease is characterized by abnormal retinal vascular dilatation and vessel dysfunction.

The term idiopathic parafoveal telangiectasia (IPT) was introduced by Gass and Oyakawa in 1982⁽¹⁾. Based on clinical findings, high-speed indocyanine green angiography, optical coherence tomography (OCT), and demographics, Yanuzzi et al. proposed a classification into type I - telangiectasia Coats aneurismal type, and type II - perifoveais telangiectasias⁽²⁾. The type 2 is the most common form, occurring in the fifth or sixth decade of life in both sexes, usually bilateral, with progressively deteriorating visual acuity⁽³⁾.

The epiretinal membrane (ERM) arises from defects in the internal limiting membrane that allows the migration of the retinal glial cells and subsequent proliferation and contraction on the inner retinal surface⁽⁴⁾. To date, the association between idiopathic macular telangiectasia and ERM formation has not been reported. This case report aims to describe the case of a patient with ERM secondary to macular telangiectasia.

CASE REPORT

The patient was a 46-year-old female with complaints of blurred and distorted vision in both eyes. She had been reporting these symptoms for 2 years. She had no history of any laser treatment, topical medication, or intraocular surgery. She had a history of hypertension and non-insulin dependent diabetes mellitus of 4 months

duration, both of which were controlled medically. She had no history of diabetic or hypertensive retinopathy.

On examination, her vision with correction was 20/200 for the right eye, counting fingers 5 meters left eye, with normal intraocular pressure, normal results of papillary examination, and a slit-lamp biomicroscopy results that revealed significant initial bilateral nuclear cataracts. Ocular motility was normal in both eyes.

Fundoscopy revealed a clear vitreous, attached retina, optical disc stained, and hard drusen in the posterior pole. Perimacular hemorrhages and aneurismal dilatation of the vessels were evident (Figure 1). A white and elevated lesion, with wrinkling of the retina was found adjacent to vascular changes (Figure 1). Optical coherence tomography (OCT) revealed loss of foveal depression and hyper-reflective areas in the inner layers of the retina, suggesting ERM formation (Figure 2). A cavity between the outer layers of neurosensory retina, atrophy of the photoreceptor layer, and integrity of retinal pigment epithelium (RPE) were also noted. Fluorescein angiography (FA) revealed a localized area of hyperfluorescence with telangiectasia of capillaries located inferotemporally to the fovea (Figure 3). These features were evident during the late stages of FA due to active leakage of dilated juxtafoveal capillaries (Figure 4). The patient maintains regular annual follow-up.

DISCUSSION

ERM, whose incidence increases with age, occurs in approximately 6% of the patients over the age of 60⁽⁵⁾. ERMs can be idiopathic or secondary to an initiating event. It is thought that most idiopathic

Submitted for publication: October 14, 2013

Accepted for publication: January 3, 2014

Study conducted at Departamento de Oftalmologia, Hospital de Clínicas, Universidade Estadual de Campinas (UNICAMP).

¹ Departamento de Oftalmologia, Hospital de Clínicas, Universidade Estadual de Campinas (UNICAMP), Campinas, SP, Brazil.

Funding: No specific financial support was available for this study.

Disclosure of potential conflicts of interest: None of the authors have any potential conflicts of interest to disclose.

Corresponding author: Flávia Cid Gomes. Rua Heitor Ernesto Sartori, 574 - Bloco 8 - Apto. 306 - Campinas - SP - 13080-657 - Brazil - E-mail: flaviacid35@gmail.com

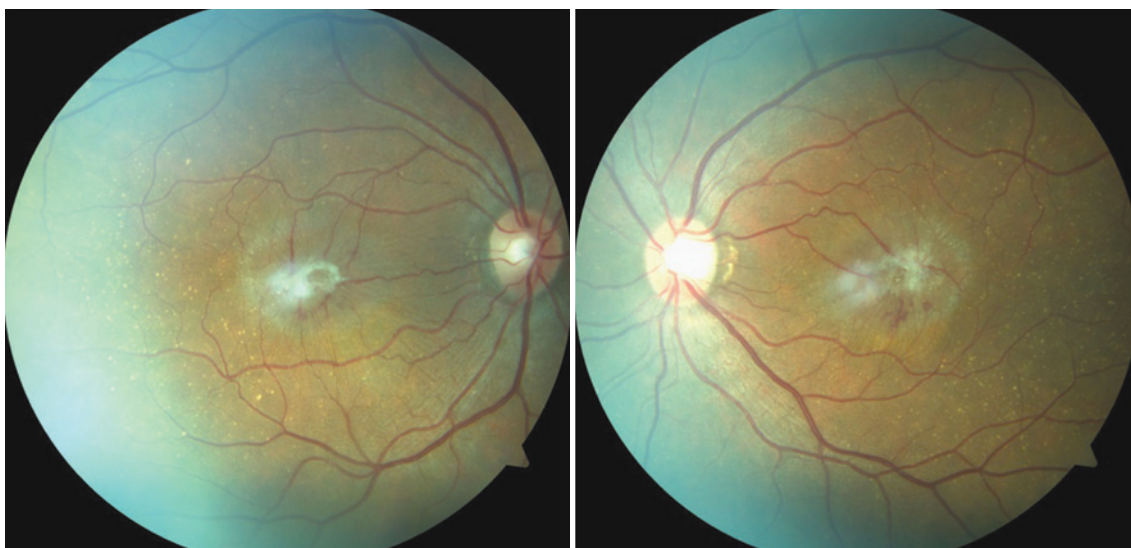


Figure 1. The funduscopy revealing hard drusen in the posterior pole, aneurysmal dilatation of parafoveal vessels and epiretinal membrane.

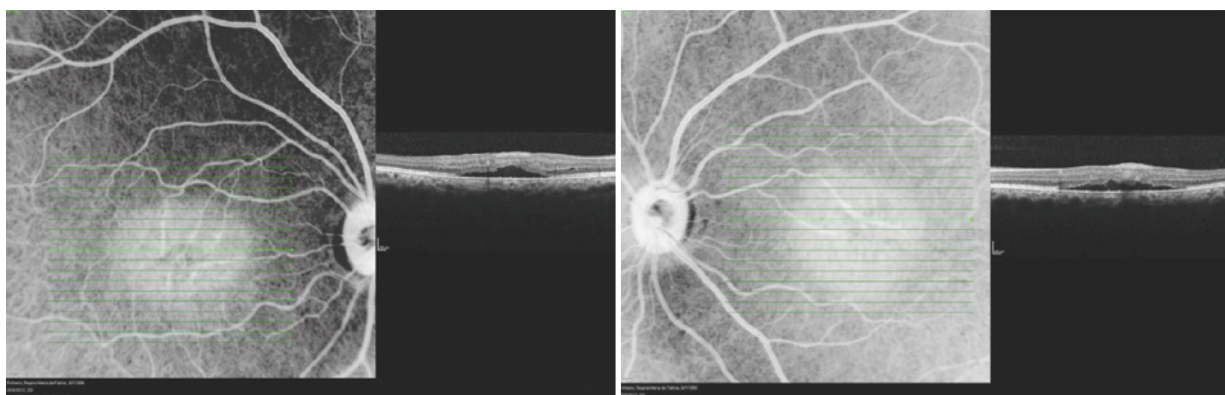


Figure 2. OCT revealing loss of foveal depression, cavity between outer layers of neurosensory retina and hiperreflective areas suggesting epiretinal membrane.

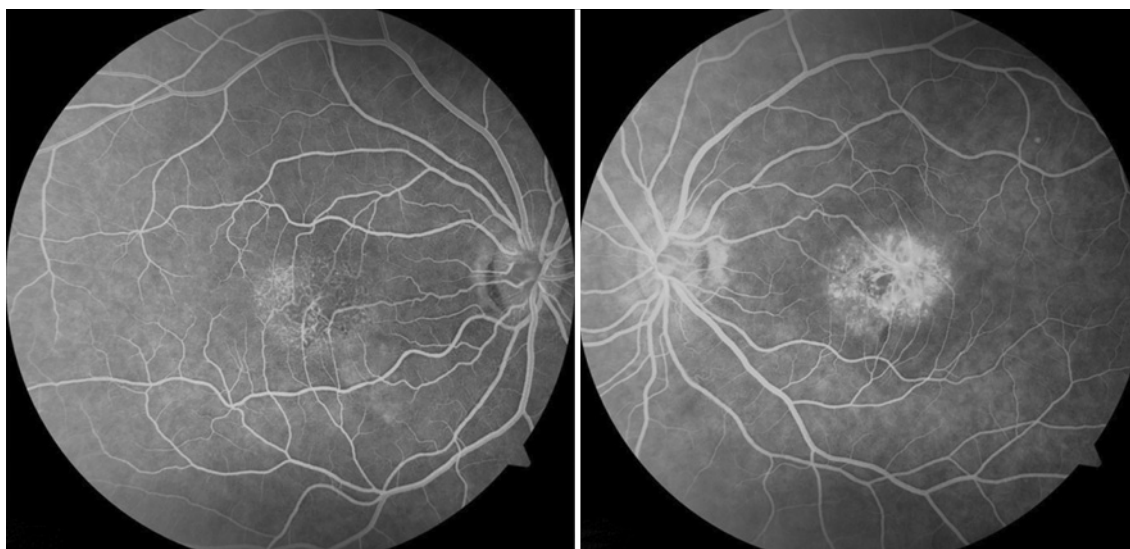


Figure 3. Early stage of FA demonstrating hyperfluorescence with telangiectasia of capillaries located inferiorly temporally to the fovea.

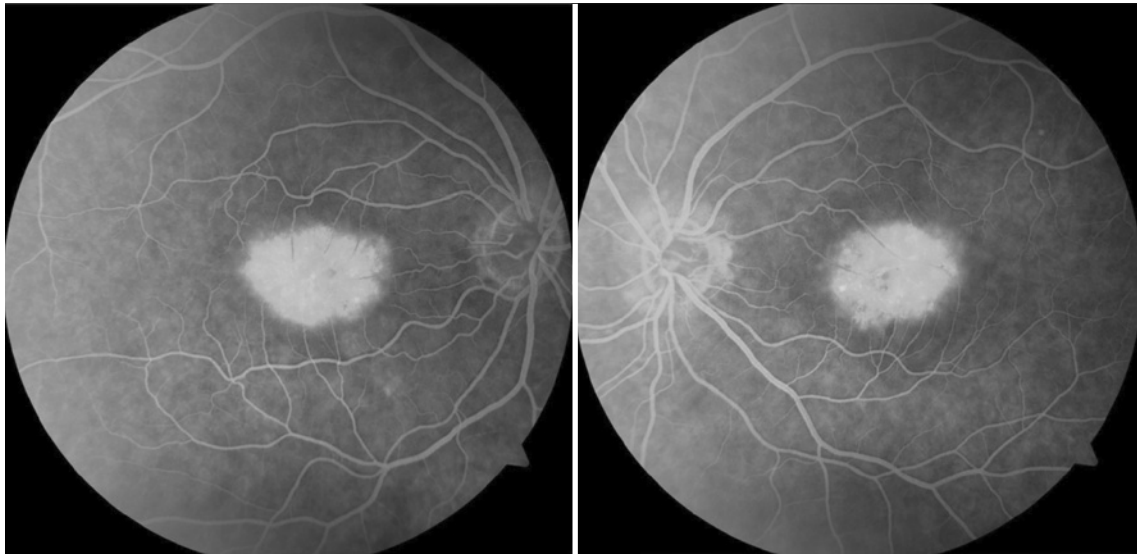


Figure 4. Late stage of FA with increase of hiperfluorescence and leakage of juxtafoveal capillaries.

ERMs originate from fibroglial proliferation on the inner surface of the retina secondary to a break in the inner limiting membrane (ILM) that occur during posterior vitreous detachment. Secondary ERMs result from an already existing ocular pathology such as central or branch retinal vein occlusion, diabetic retinopathy, uveitis, and retinal breaks with or without detachment. Glial cells, RPE cells, and myofibroblasts are shown to be involved in ERM formation.

Yannuzzi et al., classified macular telangiectasias (MacTel) into two types. Type 1 is the aneurismal telangiectasia. This involves predominantly unilateral telangiectasia, mostly in men, with aneurysms of various sizes. Type 2 is the perifoveal telangiectasia. This involves bilateral telangiectasia, which is limited to the perifoveolar area, without visible aneurysms and is associated with subretinal neovascularization (SRN). Nonproliferative perifoveal telangiectasia refers to exudative telangiectasia and foveal atrophy. Proliferative perifoveal telangiectasia refers to proliferative changes with SRN and fibrosis⁽⁶⁾.

The cause of MacTel type 2 is not known and no treatment exists to prevent the progressive loss of central vision that often occurs in patients with this disease. MacTel type 2 is also characterized by a loss of macular transparency, superficial white crystals, depletion of macular pigment, and progressive foveal thinning⁽⁷⁾. In MacTel type 2, the primary defect is located in the Müller cells or neural cells. The Müller cells regulate capillary endothelial function and metabolism of adjacent cells. Degeneration of Müller cells could cause rupture of the blood-retina barrier in parafoveal capillaries, causing edema.

It has been reported that depletion of the macular pigment (most pronounced alterations occur in the temporal perifoveolar region) is a specific and early clinical feature of MacTel type 2⁽⁷⁾. This depletion is associated with a reduction in the number of Müller cells⁽⁸⁾.

Müller cell degeneration may explain the ILM drape, cavities within the inner neural retina that commonly are found in MacTel type 2⁽⁹⁾, as well as the loss of macular pigment. We hypothesized that dysfunction

of Müller cells might lead to ERM formation. It is also possible that MacTel alters the relationship between the hyaloid face and the ILM, thus collaborating in pathogenesis of ERM. It was postulated that chronic exudation caused a change in the vitreous configuration, with secondary vitreomacular traction and ERM formation⁽¹⁰⁾.

In summary, the present case demonstrates that MacTel and ERM may occur concomitantly.

REFERENCES

- Gass JD, Oyakawa RT. Idiopathic juxtafoveal retinal telangiectasis. *Arch Ophthalmol.* 1982;100(5):769-80.
- Abujamra S. Telangiectasias perimaculares idiopáticas. *Rev Bras Oftalmol.* 2012;71(4): 213-16.
- Bonanomi MT, Cresta FB, Abujamra S. Telangiectasia retiniana juxtafoveolar idiopática do grupo 2A: hiperpigmentação macular incomum em dois pacientes. *Arq Bras Oftalmol.* 2001;64(6):569-72.
- Rentsch FJ. The ultrastructure of preretinal macular fibrosis. *Albrecht Von Graefes Arch Clin Exp Ophthalmol.* 1977;203(3-4):321-37.
- Beach JM, Schwenzler KJ, Srinivas S, Kim D, Tiedeman JS. Oximetry of retinal vessels by dual-wavelength imaging: calibration and influence of pigmentation. *J Appl Physiol* (1985). 1999;86(2):748-58.
- Yannuzzi LA, Bardal AM, Freund KB, Chen KJ, Eandi CM, Blodi BC. Idiopathic macular telangiectasia. *Arch Ophthalmol.* 2006;124(4):450-60. Comment in: *Arch Ophthalmol.* 2006;124(4):573-4.
- Charbel Issa P, van der Veen RL, Stijfs A, Holz FG, Scholl HP, Berendschot TT. Quantification of reduced macular pigment optical density in the central retina in macular telangiectasia type 2. *Exp Eye Res.* 2009;89(1):25-31.
- Bringmann A, Pannicke T, Grosche J, Francke M, Wiedemann P, Skatchkov SN, et al. Müller cells in the healthy and diseased retina. *Prog Retin Eye Res.* 2006;25(4):397-424.
- Paunescu LA, Ko TH, Duker JS, Chan A, Drexler W, Schuman JS, et al. Idiopathic juxtafoveal retinal telangiectasis: new findings by ultrahigh-resolution optical coherence tomography. *Ophthalmology.* 2006;113(1):48-57.
- Olson JL, Mandava N. Macular hole formation associated with idiopathic parafoveal telangiectasia. *Graefes Arch Clin Exp Ophthalmol.* 2006;244(3):411-2.