

# Structure-functional correlation using adaptive optics, OCT, and microperimetry in a case of occult macular dystrophy

## Correlação de estrutura e função da retina utilizando óptica adaptativa, OCT e microperimetria em um caso de distrofia macular oculta

KARLOS ÍTALO VIANA<sup>1</sup>, ANDRÉ MESSIAS<sup>1</sup>, RUBENS CAMARGO SIQUEIRA<sup>1</sup>, MURILO W. RODRIGUES<sup>1</sup>, RODRIGO JORGE<sup>1</sup>

### ABSTRACT

We report retinal functional and structural changes of a 40-year-old man diagnosed with occult macular dystrophy. Comprehensive ophthalmological evaluation was performed, followed by spectral-domain optical coherence tomography (SD-OCT - Heidelberg) and image acquisition using an adaptive optics (AO) camera (RTX1, Imagine Eyes) for photoreceptor density analysis. Functional tests included full-field ERG (ERG) and multifocal electroretinography (mfERG) (Diagnosys, LLC) and microperimetry with scanning laser ophthalmoscope (SLO) fixation controlled (MAIA, CenterVUE). OCT revealed a line of discontinuity corresponding to cone outer-segment photoreceptors associated with a loss of cone density, highlighted by a dark blue spot on the AO cone-density map on the fovea in both eyes. Loss of central sensitivity was revealed using microperimetry; ERG was within the normal range, although the mfERG showed a reduced central response amplitude.

**Keywords:** Macular degeneration/diagnosis, Photoreceptor cells, Visual field tests; Electroretinography; Tomography, optical coherence

### RESUMO

Relatamos exames de função e estrutura retiniana de paciente masculino, de 40 anos, com diagnóstico clínico de Distrofia Macular Oculta (DMO). Avaliação oftalmológica completa foi seguida por tomografia de Coerência Óptica (SD-OCT - Heidelberg) e exame com câmara de fundo de olho com tecnologia "Adaptive Optics" (AO - RTX1, Imagine Eyes) para análise da densidade de fotorreceptores. Os exames funcionais incluíram: Eletroretinografia de campo total (ERG) e multifocal (mfERG) (Diagnosys - LLC) e microperimetria com controle de fixação (MAIA - CenterVUE). Os exames revelam descontinuidade da camada de fotorreceptores na região central da fóvea em ambos os olhos pelo SD-OCT em associação com perda de densidade no mosaico cones, representado por mancha azulada no mapa do AO. Os exames de função apresentam diminuição da acuidade visual (20/80; 20/50), redução de sensibilidade central na microperimetria. Como esperado, o ERG está dentro da normalidade, mas há redução da amplitude das respostas centrais do mfERG em ambos os olhos.

**Descritores:** Degeneração macular/diagnóstico; Células fotorreceptoras; Testes de campo visual; Eletroretinografia; Tomografia de coerência óptica

### INTRODUCTION

Occult macular dystrophy (OMD) is an uncommon hereditary disease characterized by the absence of fundoscopic abnormalities, which generally occur with progressive reduction of visual acuity<sup>(1)</sup>. Affected patients show normal full-field electroretinogram (ERG) responses and centrally reduced multifocal ERG responses<sup>(1)</sup>. This finding is the main symptom that differentiates OMD from entities such as optic neuritis, dominant optic atrophy, amblyopia, or psychological disorders<sup>(2)</sup>.

The adaptive optics (AO) system permits detection of changes in the photoreceptor layer<sup>(3)</sup>. In the present case, the photoreceptor layer was evaluated using the rx Adaptive Optics Retinal Camera (Imagine Eyes; Orsay, France). This system is based on En-face reflectance imaging illuminated using a central illumination wavelength of 850 nm (infrared) with a 4 × 4-degree image field (1.2 × 1.2 mm on the retina) and a 600-mm focus interval, acquiring high-resolution cone images. The images were processed using the CK software (V 0.1) and AO detect (V 0.1) (Imagine Eyes). The spatial distribution of points was analyzed according to intercellular spacing, focal cell density, and the number of closely neighboring cells.

Microperimetry was proposed as a more suitable technique to document visual field changes in OMD compared with conventional

perimetry because of small and oftentimes relative scotoma<sup>(4)</sup>. In the present study, we examined the correlation between spectral-domain optical coherence tomography (SD-OCT) images, AO, microperimetry, and multifocal electroretinography (mfERG) in a patient with OMD.

### CASE REPORT

A 40-year-old man admitted to the neuro-ophthalmology service of our institution reported bilateral, painless loss of visual acuity that started during childhood and worsened during the last 7 years. His corrected visual acuity was 20/80 in the right eye (OD) and 20/50 in the left eye (OS). Biomicroscopy revealed a transparent cornea, a trophic iris, and a transparent crystalline lens. Intraocular pressures were 14 mmHg OD and 13 mmHg OE. Fundoscopy revealed an optic nerve with precise limits, physiological excavation, vessels of preserved caliber, and macula with preserved brightness in both eyes (Figure 1). Microperimetry revealed loss of sensitivity at the fovea, but preserved bilateral central fixation. Average thresholds were OD: 20.2 dB; OS: 23.9 dB; fixation stability index P1, OD: 72% and OS: 89% (Figure 2). Optical coherence tomography (OCT) revealed discontinuity of the photoreceptor layer in the foveal region of both eyes (Figure 2).

Submitted for publication: July 29, 2016  
Accepted for publication: October 23, 2016

<sup>1</sup> Departamento de Oftalmologia, Otorrinolaringologia e Cirurgia de Cabeça e Pescoço, Faculdade de Medicina de Ribeirão Preto, Universidade de São Paulo, Ribeirão Preto, SP, Brazil.

**Funding:** This study was supported by CNPQ and FAPESP.

**Disclosure of potential conflicts of interest:** None of the authors have any potential conflict of interest to disclose.

**Corresponding author:** Rodrigo Jorge. Av. Bandeirantes, 3.900, Ribeirão Preto, SP - 14049-900 - Brazil - E-mail: retinausp@gmail.com

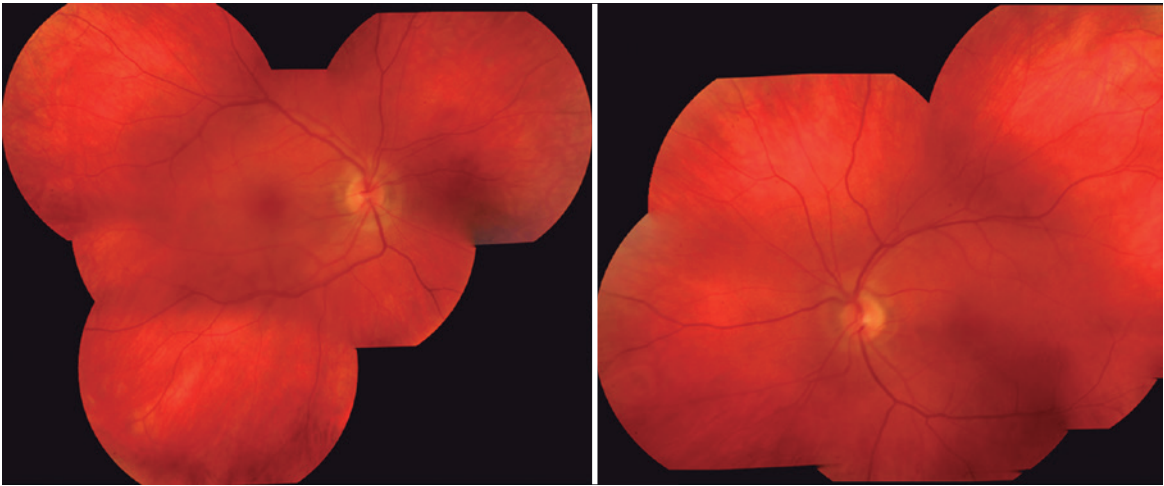


Figure 1. Image of the fundus of a patient with occult macular dystrophy.

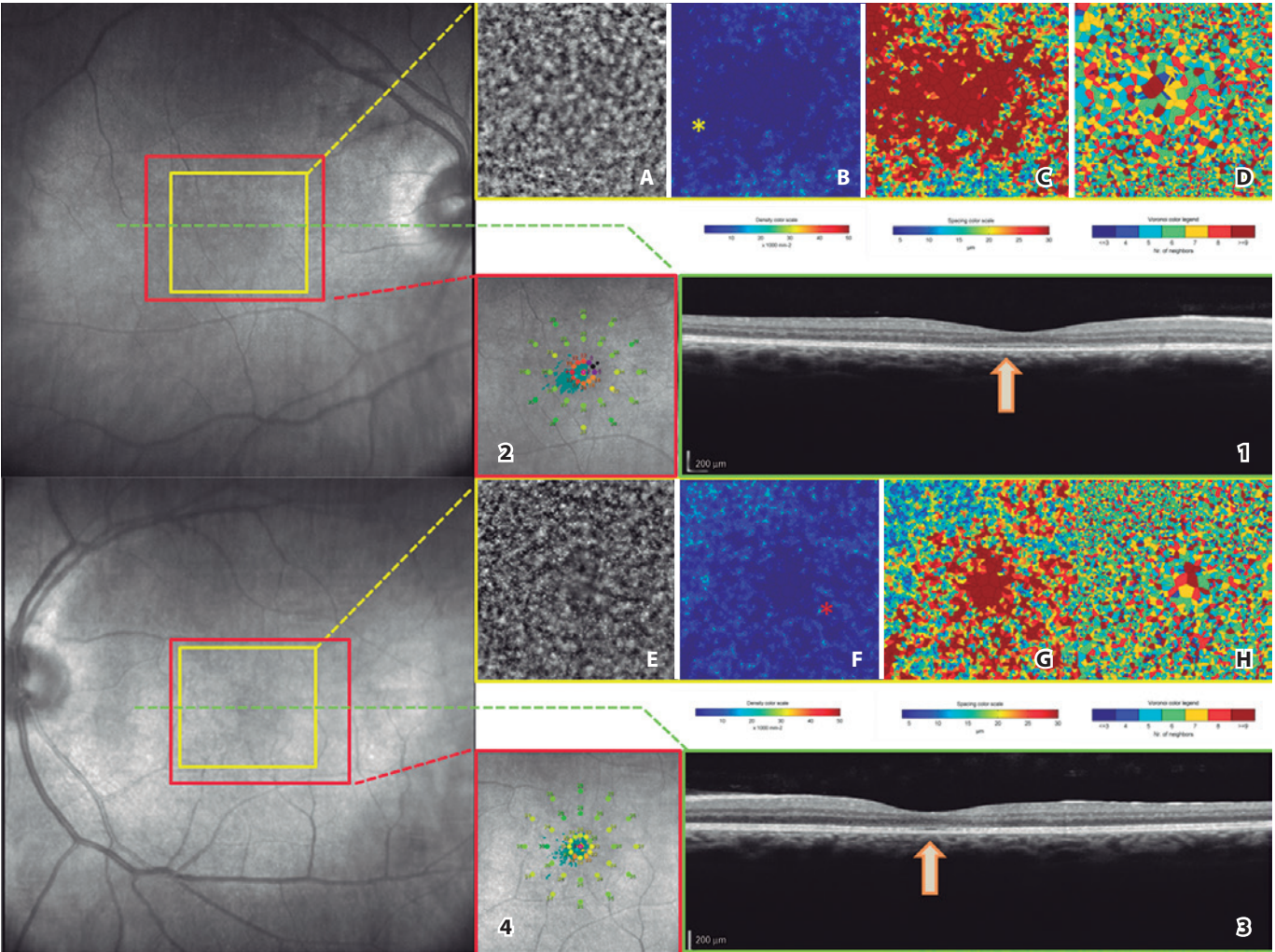


Figure 2. Optical coherence tomography (1-3), adaptive optics (A-H), and microperimetry (2-4) images of a patient with occult macular dystrophy. (Arrows) Loss of continuity of the outer photoreceptor layer in the central foveal region. (yellow asterisk) Reduced ring photoreceptor density in the foveal region. (2) Reduction of ring sensitivity in the central foveal region. (Red Asterisk) Reduced photoreceptor density in a central foveal region. (4) Reduced central sensitivity in the fovea.

Using adaptive optics, we obtained a mean density of 2,754 cones/mm<sup>2</sup> in OD and 4,204 cones/mm<sup>2</sup> in the central area (reference value, 20,000-30,000). The proportion of neighboring cells (Voronoi polygons) was 6 (29.5%) in OD and 6 (30.8%) in OS (reference value, 6). Spacing between cells was 18.90  $\mu$ m in OD and 15.83  $\mu$ m in OS (reference value, 15-20  $\mu$ m) (Figure 2). Full-field ERG revealed a normal response amplitude (Figure 3) and multifocal ERG showed reduced amplitude of photoreceptor central responses (Figure 3).

## DISCUSSION

OMD is a hereditary disease that involves retinal dysfunction only in the fovea, causing altered responses to multifocal ERG without changing the full-field ERG or causing apparent changes in ophthalmoscopy or fluorescein angiography<sup>(1)</sup>. SD-OCT analyses reveal detailed retinal structures and abnormal morphology in patients with OMD<sup>(5)</sup>, including thinning of the fovea and the outer nuclear layer, as well as interruption of the inner and outer segment junction (IS/OS line). The thickness of the photoreceptor layer and the interruption detected using SD-OCT correlate with visual function and disease progression<sup>(6)</sup>. In the present patient, we observed similar changes in SD-OCT and reduction of visual acuity. We examined the correlations

between SD-OCT, adaptive optics images, and the sensitivity potentials of the photoreceptors using microperimetry and observed that the region with loss of IS/OS continuity exhibited a lower density of the photoreceptor mosaic, sensitivity loss, and reduction of the response potentials using mfERG.

This close topographical correspondence between the functional and structurally damaged retina is important because it might help to differentiate OMD from other macular dystrophies such as Stargardt disease, in which this correlation might be absent<sup>(7)</sup>.

The pathological changes that characterize OMD seem to be localized to the posterior retinal layers, and "in-vivo" investigation of photoreceptors using AO seems to be interesting. For example, Kitaguchi et al. used AO to detect irregular dark areas in the eyes of patients with OMD<sup>(8)</sup> and Nakanishi et al. concluded that a significant reduction in cone density in a sparse array of photoreceptors of the macula should be considered a feature of OMD<sup>(9)</sup>.

In the present patient, cone densities were lower around the fovea compared with those in the paracentral retina in both eyes. Further, the temporal paracentral area of the right eye exhibited reduced cone density compared with that of the nasal paracentral retina, consistent with findings reported by Tojo et al.<sup>(10)</sup>.

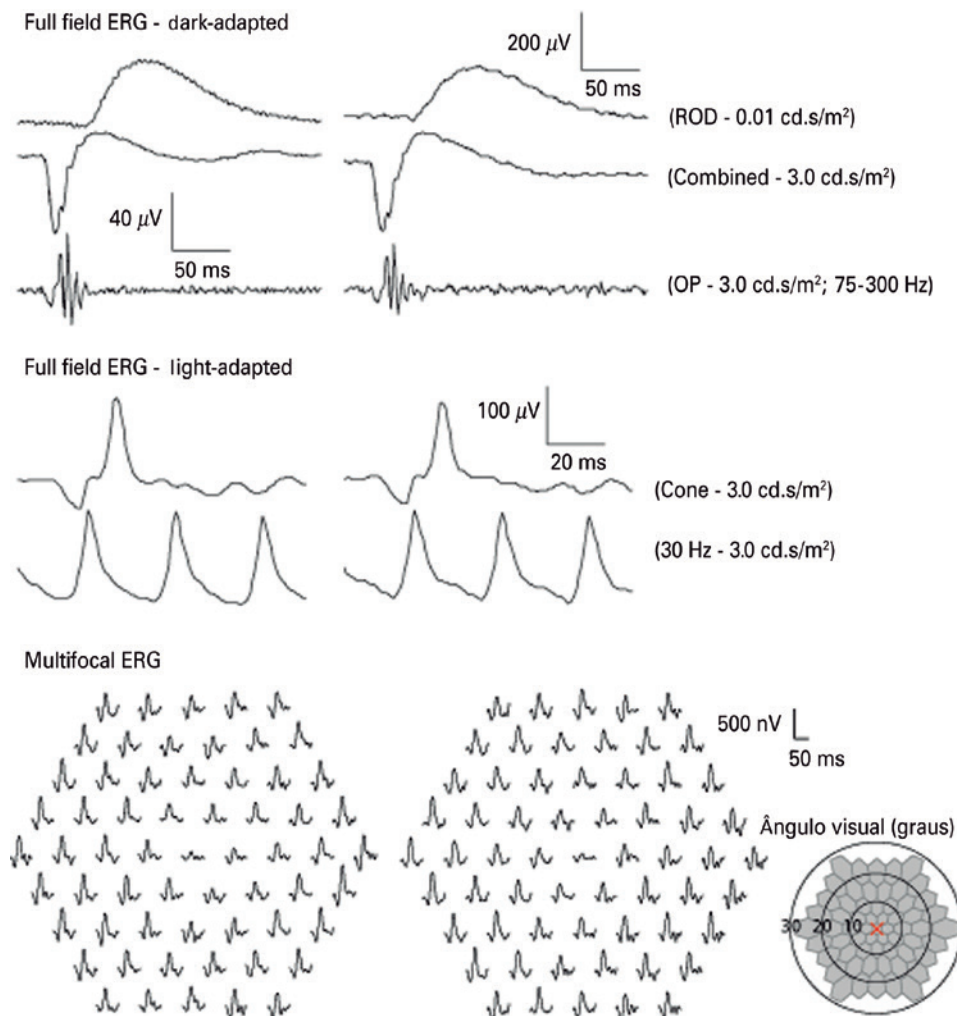


Figure 3. Dark-light-adapted full-field and multifocal electroretinography.

AO imaging can be useful for monitoring changes in photoreceptors in patients with OMD. Future studies should use AO to determine photoreceptor densities of a larger number of patients with OMD as a function of time to evaluate longitudinal photoreceptors changes and their correlation to other imaging findings, allowing diagnoses that are more precise and contributing to a better understanding of disease progression and prognosis.

## REFERENCES

1. Miyake Y, Horiguchi M, Tomita N, et al. Occult macular dystrophy. *Am J Ophthalmol*. 1996;122(5):644-53.
2. Fujii S, Escano MF, Ishibashi K, Matsuo H, Yamamoto M. Multifocal electroretinography in patients with occult macular dystrophy. *Br J Ophthalmol*. 1999;83(7):879-80.
3. Williams DR. Imaging single cells in the living retina. *Vision Res*. 2011;51(13):1379-96.
4. Freund PR, Macdonald IM. Microperimetry in a case of occult macular dystrophy. *Can J Ophthalmol*. 2013;48(5):e101-103.
5. Brockhurst RJ, Sandberg MA. Optical coherence tomography findings in occult macular dystrophy. *Am J Ophthalmol*. 2007;143(3):516-8.
6. Park SJ, Woo SJ, Park KH, Hwang JM, Chung H. Morphologic photoreceptor abnormality in occult macular dystrophy on spectral-domain optical coherence tomography. *Invest Ophthalmol Vis Sci*. 2010;51(7):3673-9.
7. Bernstein A, Sunness JS, Applegate CA, Tegins EO. Mapping the Dense Scotoma and Its Enlargement in Stargardt Disease. *Retina*. 2016;36(9):1741-50.
8. Kitaguchi Y, Kusaka S, Yamaguchi T, Mihashi T, Fujikado T. Detection of photoreceptor disruption by adaptive optics fundus imaging and Fourier-domain optical coherence tomography in eyes with occult macular dystrophy. *Clin Ophthalmol*. 2011;5:345-51.
9. Nakanishi A, Ueno S, Kawano K, et al. Pathologic Changes of Cone Photoreceptors in Eyes With Occult Macular Dystrophy. *Invest Ophthalmol Vis Sci*. 2015;56(12):7243-9.
10. Tojo N, Nakamura T, Ozaki H, Oka M, Oiwake T, Hayashi A. Analysis of macular cone photoreceptors in a case of occult macular dystrophy. *Clin Ophthalmol*. 2013;7:859-64.

# ABO ARQUIVOS BRASILEIROS DE Oftalmologia

Official Publication of the Brazilian Council of Ophthalmology

Neste mês o ABO aterrissou em Baltimore para participação na ARVO 2017 Annual Meeting, a maior reunião de pesquisadores em visão no mundo que atrai mais de 11 mil participantes de mais de 75 países.

É o CBO levando a ciência da Oftalmologia brasileira para o mundo!

AGRADECEMOS A TODOS  
QUE VISITARAM O NOSSO ESTANDE!

**ARVO2017**  
GLOBAL CONNECTIONS IN VISION RESEARCH | MAY 7 - 11 | BALTIMORE