



The importance of considering the possibility of ocular sporotrichosis in areas with high incidence rates of sporotrichosis

Esporotricose ocular: a importância de ser considerada em áreas com grande incidência de esporotricose

Mariana Nadais Aidar¹ , Barbara Millani Rebeschini¹, Carolina Tiburcio Salgado Silveira da Mata¹, Thaís Cândida Borges¹, Maria Emília Xavier dos Santos Araújo¹ 

1. Ophthalmology Service, Hospital do Servidor Público Estadual de São Paulo, São Paulo, SP, Brazil.

ABSTRACT | Ocular sporotrichosis involving adnexa can present in 4 types: granulomatous conjunctivitis, dacryocystitis, Parinaud oculoglandular syndrome, and bulbar conjunctivitis. The incidence of ocular sporotrichosis has increased in regions with high incidence rates of sporotrichosis. We present a series of three cases of ocular involvement by the fungus *Sporothrix* species, including its manifestations, approaches, and relevance in areas where sporotrichosis has considerable incidence rates.

Keywords: Eye infections, fungal; Conjunctivitis; Sporotrichosis/drug therapy; Sporothrix/isolation & purification; Itraconazole/therapeutic use

RESUMO | A esporotricose ocular envolvendo anexos pode se apresentar de quatro formas: conjuntivite granulomatosa, dacriocistite, Síndrome Oculoglandular de Parinaud e conjuntivite bulbar. A esporotricose ocular, apesar de incomum, tem aumentado em regiões com alta incidência de esporotricose. Apresentamos uma série de três casos de envolvimento ocular pelo fungo *Sporothrix* sp.: suas manifestações, abordagem e sua relevância em áreas com alta incidência de esporotricose.

Descritores: Infecções oculares fúngicas; Conjuntivite; Esporotricose/tratamento farmacológico; Sporothrix/isolamento e purificação; Itraconazol/uso terapêutico

INTRODUCTION

Parinaud oculoglandular syndrome (POS) is a rare clinical condition characterized by granulomatous conjunctivitis associated with preauricular or submandibular lymphadenopathy ipsilaterally⁽¹⁾.

The main etiological agent of POS is *Bartonella henselae*^(2,3), although other organisms have also been described⁽¹⁾. The sporotrichosis-causing fungus is described as the third leading cause of POS, after cat-scratch disease and tularemia.

Besides POS, ocular sporotrichosis involving adnexa can also present with granulomatous conjunctivitis, dacryocystitis, and bulbar conjunctivitis⁽⁴⁾. The incidence of ocular sporotrichosis has been reported to increase in regions with considerable incidence rates of sporotrichosis⁽⁵⁾.

We present a case series of ocular involvement caused by a fungus of the *Sporothrix* species, including its manifestations and management, which is relevant in areas with high incidence rates of sporotrichosis.

CASE REPORTS

Case 1

A 17-year-old male patient presented with a 2-week history of symptoms of pain and hyperemia in the left eye. He mentioned contact with various stray cats in the previous weeks. Clinical examination revealed follicles and granulomas in the upper (Figure 1) and lower tarsal conjunctiva (Figure 2) and ipsilateral submandibular and preauricular lymphadenopathy. No other abnormal findings were obtained. The patient was positive for IgM toxoplasmosis and negative for cat-scratch disease. Treatment for toxoplasmosis was administered

Submitted for publication: June 9, 2021
Accepted for publication: October 7, 2021

Funding: This study received no specific financial support.

Disclosure of potential conflicts of interest: None of the authors have any potential conflicts of interest to disclose.

Corresponding author: Mariana Nadais Aidar.
E-mail: aidarmariana@gmail.com

Approved by the following research ethics committee: Hospital do Servidor Público Estadual de São Paulo (CAAE: 45094721.9.0000.5463).

 This content is licensed under a Creative Commons Attribution 4.0 International License.

before the patient's visit to our service, and treatment for cat-scratch disease (doxycycline 100 mg twice daily for 2 weeks) was prescribed, but no improvement was observed. Cultures of specimens from scrapings and conjunctival secretions and a histopathological study of the conjunctival granuloma in the outer corner of the left eye were performed (Figure 3), which showed granulomas but not the causative agent. No fungal growth was observed. Itraconazole 200 mg/day was administered, with total regression in 2 months of treatment (Figure 4).

Case 2

A 6-year-old boy was brought to our clinic by his mother for evaluation due to ocular hyperemia in the right eye, which had persisted for 3 weeks. The mother mentioned previous treatment with topical tobramycin for 1 week and oral erythromycin for 2 weeks, with no improvement. She described a history of feline sporotrichosis in her domestic animal, with a positive culture result of the lesion sample. Clinical examination of the child revealed follicles in the upper and lower tarsal

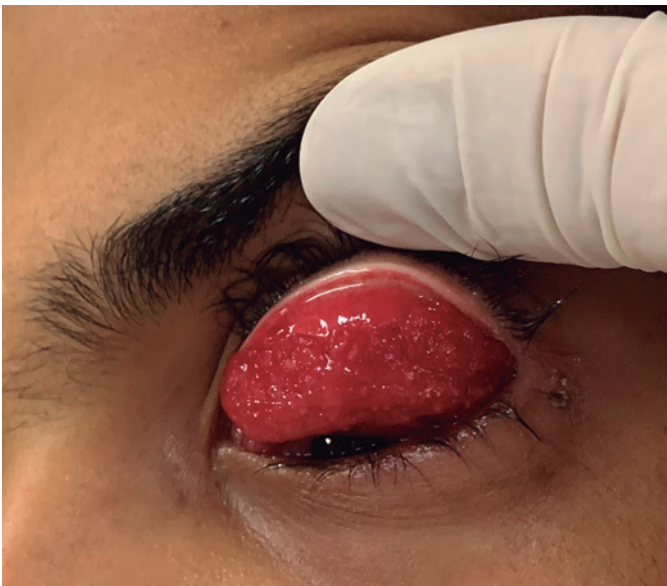

Figure 1. Follicular reaction and granulomas in the upper tarsal conjunctiva.

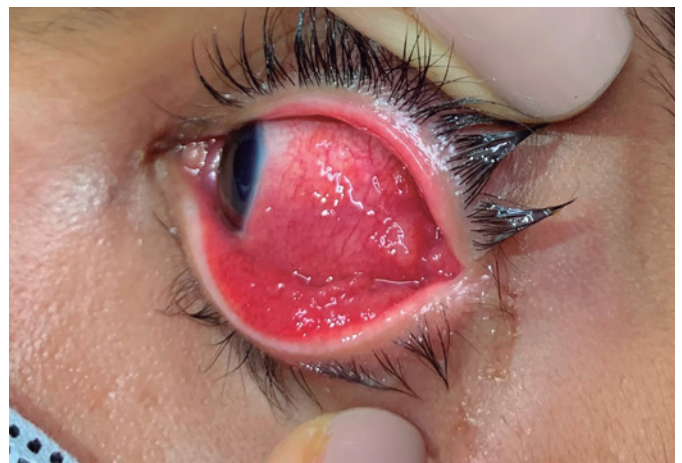

Figure 3. Conjunctival granuloma in the outer corner of the left eye, where biopsy was performed.

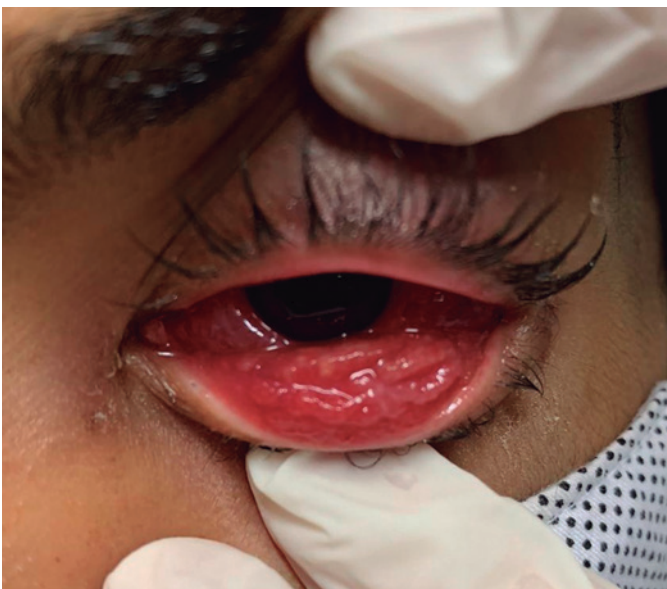

Figure 2. Follicular reaction and granulomas in the lower tarsal conjunctiva.

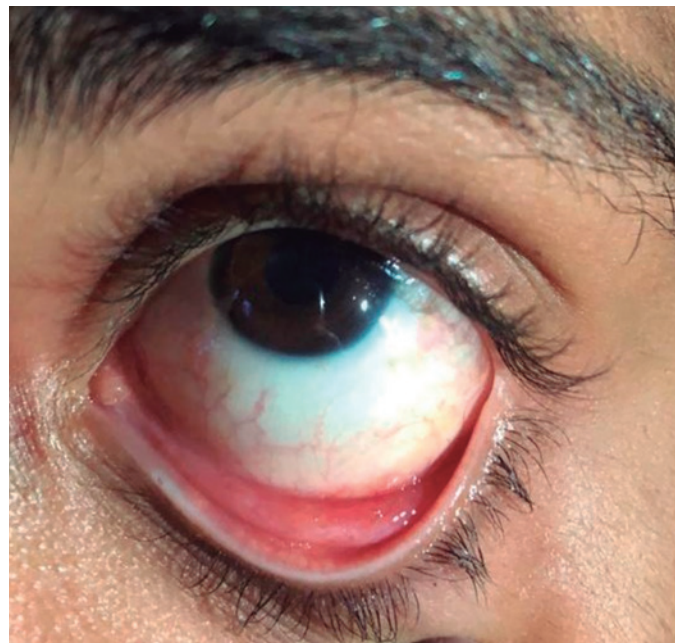


Figure 4. Appearance of the eye during external eye examination, showing total resolution after a 2-month treatment with itraconazole.

conjunctiva, temporal conjunctival hyperemia, and diffuse granulomas in the bulbar conjunctiva. Ipsilateral cervical lymphadenopathy was detected. Other findings were unremarkable. The patient's clinical presentation and epidemiological findings suggested POS due to sporotrichosis. Therefore, treatment was initiated with itraconazole 100 mg twice daily for 2 months, which achieved total regression.

Case 3

An 18-year-old female patient complained about a growing nodule in her right lower eyelid associated with eye discomfort, which started 15 days before. She was previously diagnosed as having a chalazion and treated with corticosteroid, antibiotic ointment, oral doxycycline, and warm compresses, with no improvement. She mentioned that her cat had dermatological lesions diagnosed as sporotrichosis through a skin biopsy. Her clinical examination revealed multiple slightly hyperemic granulomatous lesions on the upper and lower tarsal conjunctiva of the right eye, which was associated with a follicular reaction. At the time of examination, no palpable lymph nodes were found. Other findings were unremarkable. As the clinical presentation and epidemiological findings suggested ocular sporotrichosis, itraconazole was prescribed at 200 mg daily for 30 days, which improved the patient's condition.

DISCUSSION

Fungal infections are generally neglected, and inadequate surveillance leads to their emergence, as observed in zoonotic sporotrichosis. Brazil experienced a geographic expansion of sporotrichosis during 1998-2017, and the incidence of zoonotic sporotrichosis (disease transmitted from animals to humans) has increased considerably⁽⁵⁾. The southeast region had the highest incidence rates of human and animal cases⁽⁶⁾. Some factors can be cited as causes of this increase, such as socioeconomic and environmental difficulties, urban overcrowding, and poor basic sanitation⁽⁵⁾.

Even with the spread of the disease to other states in Brazil, compulsory notification in human cases only occurred in the states of Rio de Janeiro, Pernambuco, and Paraíba and in the municipalities of Guarulhos (SP) and Salvador (BA)⁽⁷⁾. Since 2011, as a result of the frequent increase in the number of sporotrichosis cases, the São Paulo municipality has been conducting widespread surveillance of sporotrichosis cases. However, the muni-

cipal decree that defined notification of suspected cases of sporotrichosis in animals and humans as mandatory in São Paulo municipality was published only in 2020⁽⁵⁾.

Recently, Ribeiro et al. reported a series of 10 cases of POS due to contact with infected domestic cats in the São Paulo metropolitan region, emphasizing the importance of considering ocular sporotrichosis as a differential diagnosis⁽⁸⁾. In addition, Yamagata et al.⁽⁹⁾ described ocular sporotrichosis as an often-misdiagnosed cause of granulomatous conjunctivitis in endemic areas.

Ocular sporotrichosis can develop hematogenously or by the involvement of ocular adnexa due to self-inoculation or trauma⁽¹⁰⁾. Sporotrichosis ocular involvement has rarely been described in immunocompetent patients or in individuals without previous ocular trauma⁽⁸⁾. Our three patients had no history of trauma or relevant past medical history (all of them were immunocompetent), which leads us to the hypothesis of contamination by self-inoculation due to contact with contaminated felines.

When it comes to ocular sporotrichosis involving adnexa, some possibilities of manifestation include granulomatous conjunctivitis, POS, dacryocystitis, and bulbar conjunctivitis⁽⁴⁾. In granulomatous conjunctivitis, clustered nodules appear with a smooth and shiny surface surrounding the tarsal and/or bulbar conjunctiva, associated with conjunctival hyperemia⁽⁹⁾.

At the onset of the disease, granulomas can be confused with hordeolum and chalazion, which leads to delay of the correct diagnosis, as in cases 2 and 3⁽¹¹⁾. Ocular sporotrichosis is an important differential diagnosis in lesions that do not respond to standard treatments and should be considered especially in areas with high incidence of sporotrichosis.

The gold standard diagnostic method for ocular sporotrichosis is the collection of conjunctival discharge sample with a sterile swab and culturing the material for fungi or by granuloma biopsy⁽⁸⁾. However, in our three cases, clinical and epidemiological history-presumptive diagnosis was made. *Itraconazole* at a dose of 100-200 mg daily is effective and well tolerated and has largely replaced spectrum selective kinase inhibitor and amphotericin B owing to its 90-100% efficacy rates for cutaneous and extracutaneous sporotrichosis⁽¹²⁾. Our patients were treated with 200-mg itraconazole daily and showed great therapeutic response with total regression.

As only few reports have described ocular sporotrichosis and sporotrichosis has not been described as the

first diagnostic hypothesis in cases of POS, diagnosis and treatment are delayed. Owing to the increasing incidence of sporotrichosis in certain regions, the incidence of ocular sporotrichosis has also increased. Therefore, in these areas, including sporotrichosis among the first diagnostic hypotheses is relevant in cases of granulomatous conjunctivitis, POS, dacryocystitis, or bulbar conjunctivitis.

We emphasize the importance of ophthalmologists being familiar with the differential diagnosis in cases of granulomatous conjunctivitis that does not improve with conventional treatment, especially in areas with increased incidence of sporotrichosis, and encourage compulsory notification of animal and human cases of ocular sporotrichosis.

REFERENCES

1. Huang MC, Dreyer E. Parinaud's oculoglandular conjunctivitis and cat-scratch disease. *Int Ophthalmol Clin*. 1996;36(3):29-36.
2. Oliveira AH, Pereira CA, Sousa LB, Freitas D. Conjuntivite granulomatosa atípica causada pela doença da arranhadura do gato- Relato de caso. *Arq Bras Oftalmol*. 2004;67(3):541-3.
3. Mannis MJ, Holland EJ. *Cornea*. 4th ed. St. Louis, Mo: Elsevier; 2015.
4. Schubach A, de Lima Barros MB, Schubach TM, Francesconi-do-Valle AC, Gutierrez-Galhardo MC, Sued M, et al. Primary conjunctival sporotrichosis: two cases from a zoonotic epidemic in Rio de Janeiro, Brazil. *Cornea*. 2005;24(4):491-3.
5. Gremião ID, Oliveira MM, de Miranda LM, Saraiva Freitas DF, Pereira SA. Geographic expansion of sporotrichosis, Brazil. *Emerg Infect Dis*. 2020;26(3):621-4.
6. Lopes-Bezerra LM, Mora-Montes HM, Zhang Y, Nino-Vega G, Rodrigues AM, de Camargo ZP, et al. Sporotrichosis between 1898 and 2017: The evolution of knowledge on a changeable disease and on emerging etiological agents. *Med Mycol*. 2018;56(suppl 1):12643.
7. Brizeno MC, Silva EC, Bassoli AC. The public health problem of feline sporotrichosis in the state of Pernambuco, Brazil: a narrative review. *Braz J Dev [Internet]*. 2020 [cited 2021 jan 21];6(12):93845-55. Available from: O problema de saúde pública da esporotricose felina no estado de Pernambuco, Brasil: uma revisão narrativa / The public health problem of feline sporotrichosis in the state of Pernambuco, Brazil: a narrative review | Brizeno | Brazilian Journal of Development (brazilianjournals.com)
8. Ribeiro CR, Silva BP, Almeida Costa AA, Neto AB, Vieira LA, Lima MA, et al. Ocular Sporotrichosis. *Am J Ophthalmol Case Rep*. 2020;19:100865.
9. Yamagata JP, Rudolph FB, Nobre MC, Nascimento LV, Sampaio FM, Arinelli A, et al. Ocular sporotrichosis: A frequently misdiagnosed cause of granulomatous conjunctivitis in epidemic areas. *Am J Ophthalmol Case Rep*. 2017;8:35-8.
10. Vieira-Dias D, Sena CM, Orefice F, Tanure MA, Hamdan JS. Ocular and concomitant cutaneous sporotrichosis. *Mycoses*. 1997;40(5-6):197-201.
11. Ribeiro AS, Bisol T, Menezes MS. Parinaud's oculoglandular syndrome caused by Sporotrichosis. *Rev Bras Oftalmol*. 2010;69(5):317-22.
12. Mahajan VK. Sporotrichosis: an overview and therapeutic options. *Dermatol Res Pract*. 2014;2014:272376.