

Excimer laser photorefractive keratectomy resulting in more myopia postoperatively than preoperatively

Cerectomia fotorrefrativa resultando em mais miopia no período pós-operatório do que pré-operatório

João E. C. Ribeiro⁽¹⁾
Marguerite B. McDonald⁽²⁾
Stephan D. Klyce⁽³⁾

SUMMARY

Purpose: To present three patients who experienced excessive myopic regression which resulted in more myopia after excimer laser surgery.

Methods: All patients, white males, 31 to 35 years old, were treated with the VISX 20/20 excimer laser.

Results: Patient 1 had a manifest refraction of -5.00 diopters before PRK and 9 months later it was -4.25 +0.50 x 65°. Six months after retreatment it was -6.00 diopters and the patient had a corneal haze grade 3. Patient 2 had a manifest refraction of -12.25 +2.25 x 10° before surgery and -14.25 +1.00 x 105° after wards with a corneal haze grade 3. Patient 3 had a manifest refraction of -5.75 +0.25 x 25° and four months after surgery it was -6.25 with a corneal haze grade 2.

Conclusion: The corneal healing process after excimer is not well understood and patients should be informed about the remote possibility that their myopia may increase after PRK and that they may develop a significant haze.

Key words: Excimer laser; Myopia; Haze.

INTRODUCTION

Worldwide excimer laser has been used to correct refractive errors. The results are very encouraging, and for myopia up to -6.00 diopters (D) more than 90% of the eyes have an uncorrected vision (UCV) of 20/40 or better¹. However, a few unexpected results occur. Corneal wound healing affects the refractive outcome after photorefractive keratectomy (PRK) and the variability in the wound healing response of individual eyes cannot be controlled.

We report three eyes of three patients that experienced excessive myopic regression, which resulted in more myopia postoperatively than they had preoperatively, and important corneal haze after excimer laser surgery. The scale used for grading haze was as follows: 0: clear cornea, possibly with faint haze; 1: mild reticulated haze not affecting refraction; 2: moderate haze, refraction possible but difficult; 3: opacity prevents refraction, anterior chamber easily viewed; 4: opacity impairs view of anterior chamber and 5: anterior chamber not visible².

From the Louisiana State University Eye Center, Louisiana State University Medical Center School of Medicine, New Orleans, LA.

- ⁽¹⁾ LSU Eye Center - 1993 Corneal and refractive surgery fellow and Department of Ophthalmology - Federal University of Minas Gerais;
⁽²⁾ Refractive Surgery Center of the South, New Orleans, LA;
⁽³⁾ Lions Eye Research Laboratories - LSU Eye Center, New Orleans, LA.

Endereço para correspondência: Dr. João E. C. Ribeiro - Av. Santos Dumont, 409. Uberaba (MG) CEP 38060-600.

CASE REPORTS

Case 1

A 32-year-old white man underwent a photorefractive keratectomy on his left eye. He had 20/400 UCV and 20/20 with a manifest refraction of -5.00 diopters on this eye. Keratometric readings were 46.00/46.75 at 90° and central corneal thickness was 0.526 mm. The surgery was unremarkable and 0.3% ciprofloxacin hydrochloride and 0.1% diclofenac sodium drops were instilled in the immediate postoperative period. Cornea healed in 4 days and 0.1% fluorometholone (FML) drops were prescribed 3 times a day (TID).

One month after surgery, UCV was 20/40⁺³ and best spectacle-corrected vision (BSCV) 20/30⁻¹ with a refraction of +0.50 +0.75 x 85°. Haze was graded 1, corneal thickness 0.452 mm and keratometry 40.25/41.00 at 100°. The patient was kept in FML TID for the next 3 months and then tapered.

Nine months later, UCV was 20/400, BSCV 20/25⁻² with a refractive error of -4.25 +0.50 x 65° and haze was graded 1. Keratometric readings were 44.87/45.37 at 66° and corneal thickness was 0.528 mm. This eye was retreated.

At his first month following retreatment, UCV was 20/200, BSCV 20/40 with +2.00 +1.75 x 105° and haze was graded 1. Corneal thickness was 0.430 mm and K readings were 36.25/36.50 at 100°. No drugs were used.

Three months after retreatment, UCV was 20/100, and with a manifest refraction of +2.50 +2.00 x 180° his vision was 20/40. His corneal haze was graded 1, corneal thickness was 0.430 mm and keratometric values were 40.00/42.25 at 115°.

On the six month follow-up, UCV was 20/200 and BSCV 20/60⁻¹ with a manifest refraction of -6.00 diopters. Haze was graded 3, keratometric readings were 44.00/45.50 at 90° and corneal thickness was 0.565 mm.

Case 2

A 35-year-old white man underwent excimer laser photorefractive keratectomy on his right eye. Preoperatively, UCV was counting finger, the manifest refractive error was -12.25 +2.25 x 100° yielding a 20/20 vision, keratometric readings were 44.10/46.60 at 90° and ultrasonic central corneal pachymetry was 0.555 mm. The surgical procedure was unremarkable and on the immediate postoperative period a bandage soft contact lens was placed on the eye. Ciprofloxacin hydrochloride (0.3%) and 0.1% diclofenac sodium drops were prescribed four times a day. On the 5th postoperative day, cornea had reached full reepithelialization and unpreserved artificial tears were used thereafter.

At one month examination, UCV was 20/60⁻² and BSCV was 20/30⁻¹ with a manifest refraction of +2.25 diopters. Corneal haze was graded 1. Keratometric readings were 36.50/37.50 at 15° and central corneal thickness was 0.432 mm.

On his third month follow-up visit, UCV was counting finger, BSCV was 20/400 with a manifest refraction of -4.00

diopeters. He had corneal haze graded 2 and keratometric values were 43.00/44.10 at 175°. Central corneal pachymetry was 0.572 mm. One percent prednisolone acetate was given every two hours for two days and four times a day for the following month. The patient experienced no improvement and at the fifth month examination his UCV was counting finger and BSCV 20/60 with a manifest refraction of -14.25 +1.00 x 105°. Corneal haze was graded 3 and K-readings were 47.00/49.90 at 80°. Corneal thickness was 0.560 mm.

Figure 1 shows videokeratography from pre and postoperative period (1, 3, and 5 months) for patient 2.

Case 3

A 31-year-old white man underwent an excimer laser surgery. Preoperatively he had UCV of counting finger and with a manifest refraction of -5.75 +0.25 x 25° his vision was 20/20. Keratometric readings were 44.25/44.87 at 92° and ultrasound central corneal pachymetry was 0.541 mm. The surgical procedure was unremarkable. He was given 0.3% ciprofloxacin hydrochloride and 0.1% diclofenac sodium drops four times a day and a bandage soft contact lens was placed on the eye till reepithelialization. On the 4th postoperative day his cornea was healed and unpreserved artificial tears were prescribed.

At one month examination, his UCV was 20/30 and his BSCV was 20/25 with a manifest refraction of +0.50 +0.75 x 140°. Corneal clarity was graded 1 and K-readings were 39.00/39.50 at 75°. Central corneal thickness was 0.508 mm. He was

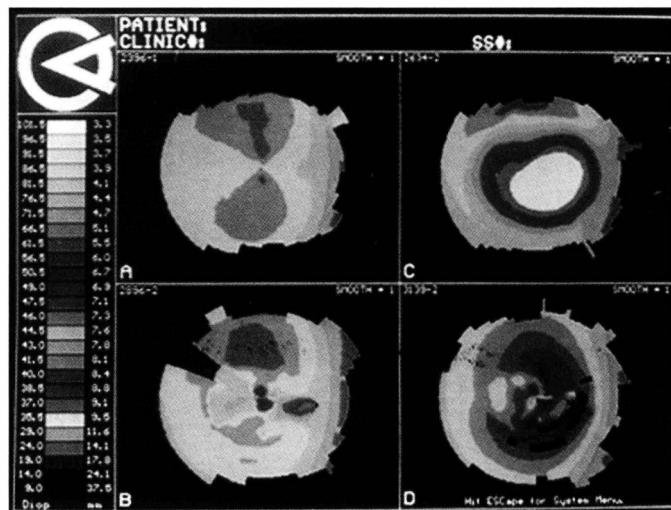


Fig 1 - Illustrates the topography of case 2. Top left - Preoperative topography showed a cornea with regular astigmatism (46.9/44.2 x 176°) and a slight amount of corneal asymmetry. Top right - One month postoperatively, the topography showed the effect of the excimer myopic ablation with an approximate 10 D shift on corneal curvature. Sim K at this time was 37.8/36.1 x 13°. Bottom left - Three months after the procedure, the area of ablation showed marked irregularity and steepening consisting with tissue addition. Sim K was 46.1/41.9 x 170°. Bottom right - Five month postoperatively, continued tissue addition was evident, again with marked surface irregularity. At this time Sim K's had increased to 49.9/47.0 x 172°. Topographies of patient 1 and 3 were normal before surgery and evolved similarly to patient 2 after the surgery.

kept on artificial tears.

Four months after treatment, UCV was 20/300, BSCV was 20/40 with a manifest refraction of -6.25 diopters and corneal clarity was graded 2. Keratometric readings were 40.00/41.50 at 150° and central pachymetry was 0.576.

All cases were treated with the VISX excimer laser, model Twenty/Twenty (Santa Clara, CA). Videokeratographies were performed pre and postoperatively and showed tissue addition and surface irregularity in all cases at the last examination.

DISCUSSION

Two major areas are involved in the success of excimer laser corneal surgery: technical qualities of the laser system and corneal response to trauma. After years of intense research, excimer laser systems adjustments were performed and technical qualities improved. Less progress was made in the field of corneal wound healing after laser.

In the early days of laser corneal surgery, it was expected that the minimal damage induced by the laser would not stimulate stromal keratocytes to migrate into the surgical site and secrete new extracellular matrix. After years, studies have shown that patients have a wide range of haze and regression^{1,2,3}.

Following trauma, a sequence of events is activated to restore the damaged area. Two major systems are involved in the healing process: degradation and removal of damaged tissue, and synthesis of cellular and extracellular elements. A lack of balance between these two processes may lead to abnormal healing⁵.

To the present moment, it is not well established which factors regulates corneal healing. Start signals are recognized like growth factors⁵, proteins from the system plasmin - plasminogen⁴ and different types of interleukins^{6,7}. Less recognized are stop signals. Therefore, corneal healing process after laser is not well understood and individual variations occur.

These three cases presented here are interesting because the refractions after laser corneal surgery show an increase in the myopic power comparing to preoperative values. This could be caused by corneal epithelium or stroma hyperplasia or an association of both. The healing epithelium elaborates cytokines such as Interleukin-3 which stimulates keratocytes to turn into fibroblast and elaborate new extracellular matrix⁷ causing regression and haze formation.

The effect of topical corticosteroids on refractive outcome and corneal haze after photorefractive keratectomy is controversial. Cases 1 and 3 were not initially treated with steroids because of previous study showing that topical use of this

drug had no effect on refractive outcome and corneal haze⁸.

Our current researches involve in vitro response of keratocytes to excimer laser and tear analysis in the sense of predicting which are the good candidates to this surgery and thus increasing the predictability of this surgical procedure. In the meantime, patients should be informed of the remote possibility that their myopia may actually increase after PRK.

RESUMO

Objetivo: Apresentar três pacientes que tiveram excessiva regressão após ceratectomia fotorrefrativa resultando em mais miopia no período pós-operatório.

Método: Todos os pacientes eram brancos, masculinos com idades entre 31 e 35 anos e foram tratados com o VISX 20/20 excimer laser.

Resultados: Caso 1 tinha uma refração dinâmica de -5,00 dioptrias antes da cirurgia e -4,25 +0,50 x 65° nove meses depois. Foi submetido a retratamento e após seis meses sua refração era de -6,00 dioptrias com haze corneano grau 3. Caso 2 tinha -12,25 +2,25 x 10° antes da cirurgia e -14,25 +1,00 x 105° cinco meses depois com haze grau 3. Paciente 3 tinha -5,75 +0,25 x 25° antes da cirurgia e -6,25 dioptrias quatro meses mais tarde com haze grau 2.

Conclusão: Pelo fato do processo de cicatrização corneano após PRK não ser ainda bem compreendido e controlável, os pacientes devem ser informados que esta cirurgia pode levar a um aumento da miopia.

REFERENCES

1. Seiler T, Wollensak J. Myopic photorefractive keratectomy with the excimer laser: One year follow-up. *Ophthalmology* 1991;98(8):1156-63.
2. McDonald MB, Frantz JM, Klyce SD, Beuerman RW, Varnell R, Munnerlyn CR, Clapham TN, Salmeron B, Kaufman HE. Corneal Photorefractive Keratectomy for Myopia - The Blind Eye Study. *Arch Ophthalmol* 1990;108: 799-808.
3. Fantes F, Hanna K, Waring G, Pouliquen Y, Thompson K, Savoldelli M. Wound healing after excimer laser keratomileusis (photorefractive keratectomy) in monkeys. *Arch Ophthalmol* 1990;108:665-75.
4. Lohmann C, Marshall J. Plasmin- and plasminogen- activator inhibitors after excimer laser photorefractive keratectomy: New concept in prevention of postoperative myopic regression and haze. *Refract Corneal Surg* 1993;9:300-2.
5. Hunt T K. Prospective: A retrospective perspective on the nature of wounds. In: Growth factors and others aspects of wound healing: Biological and clinical implications. San Francisco: Alan R. Liss, Inc., 1988. p. XIII-XX.
6. Cubbit C, Lausch R, Oakes J. Differences in interleukin-6 gene expression between cultured human corneal epithelial cells and keratocytes. *Invest Ophthalmol Vis Sci* 1995;36:330-6.
7. Waring G. The challenge of corneal wound healing after excimer laser refractive surgery. *J Refract Surg* 1995;11:339-40.
8. Gartry D, Kerr M, Lohmann C, Marshall J. The effect of topical corticosteroids on refractive outcome and corneal haze after photorefractive keratectomy - A prospective, randomized, double blind trial. *Arch Ophthalmol* 1992;110:944-9.