

# Pyogenic granuloma after retinal detachment surgery with scleral buckle: case report

*Granuloma piogênico após cirurgia de descolamento de retina com introflexão escleral: relato de caso*

Eduardo F. Damasceno<sup>1</sup>

Cristiano Pereira<sup>2</sup>

Nadyr Antônia Pereira Damasceno<sup>3</sup>

Soraya Alessandra Pereira Horowitz<sup>4</sup>

Octavio Moura Brasil Amaral Filho<sup>5</sup>

## ABSTRACT

The authors relate an uncommon case of pyogenic granuloma restricted to tarsal conjunctiva post retinopexy with scleral buckle.

**Keywords:** Cornea/pathology; Scleral buckling; Retinal detachment/surgery; Conjunctival neoplasms; Granuloma, pyogenic; Human; Male; Middle aged; Case reports [Publication type]

## INTRODUCTION

Pyogenic granulomas are classified as variations of capillary haemangiomas that presents as small reddish tumors that usually appear after ocular trauma (or even after surgical manipulation) and grows in areas of vascularized tissue, or when these areas are submitted to chronic inflammatory injuries<sup>(1,2)</sup>. Despite the fact that the main ophthalmological reports on pyogenic granulomas are associated with chalazion and ocular squint surgery, there are reports of spontaneous development even on the conjunctival sac<sup>(1,3)</sup>. Other ocular cases have been described on the eyelids and on the cornea, partly because these tissues on the external ocular surface are more exposed. However, there are cases that occur up to the orbital cavity<sup>(3)</sup>. Though defined as pyogenic granuloma, the reported condition is neither related to purulent infection nor to granulomatous inflammation. A confirming histological examination of pyogenic granuloma would reveal endothelial and capillary cells proliferation associated with inflammatory cells. Therefore, this case study reports an uncommon pyogenic granuloma as a complication after retinopexy with scleral buckle using encircle band and tire.

## CASE REPORT

A 59-year-old white male complained of ocular burning on his left eye. The patient had undergone retinal detachment surgery ten years before. Right after that, he noticed small tumors growing on his left lower lid. An ocular examination under slit lamp revealed two reddish tumors located in the subconjunctival sac, thereby causing lower lid proptosis (Figure 1).

Thus, the hypothesis of pyogenic granuloma was proposed, based on previous clinical history and on the tumor aspect.

The patient underwent a tumor removal surgery and a subsequent histological analysis of the tissue was performed, revealing the diagnosis of pyogenic granuloma (Figure 2).

Trabalho realizado no Hospital Universitário Clementino Fraga Filho da Universidade Federal do Rio de Janeiro (UFRJ) - Rio de Janeiro (RJ) - Brasil.

<sup>1</sup> Médico do Departamento de Oftalmologia do Hospital Universitário Clementino Fraga Filho da Universidade Federal do Rio de Janeiro (UFRJ) - Rio de Janeiro (RJ) - Brasil.

<sup>2</sup> Médico Residente do Serviço de Oftalmologia do Hospital Municipal Souza Aguiar - Rio de Janeiro (RJ) - Brasil.

<sup>3</sup> Médica do Serviço de Oftalmologia do Hospital Municipal Souza Aguiar - Rio de Janeiro (RJ) - Brasil.

<sup>4</sup> Médica do Serviço de Oftalmologia do Hospital Municipal Souza Aguiar - Rio de Janeiro (RJ) - Brasil.

<sup>5</sup> Professor Adjunto do Departamento de Oftalmologia do Hospital Universitário Clementino Fraga Filho da UFRJ - Rio de Janeiro (RJ) - Brasil.

**Address for correspondence:** Eduardo Damasceno, Rua Jangadeiros, 40/601 - Rio de Janeiro (RJ) CEP 22420-010

E-mail: e\_damasceno@yahoo.com

Recebido para publicação em 29.12.2007

Última versão recebida em 10.01.2009

Aprovação em 03.02.2009

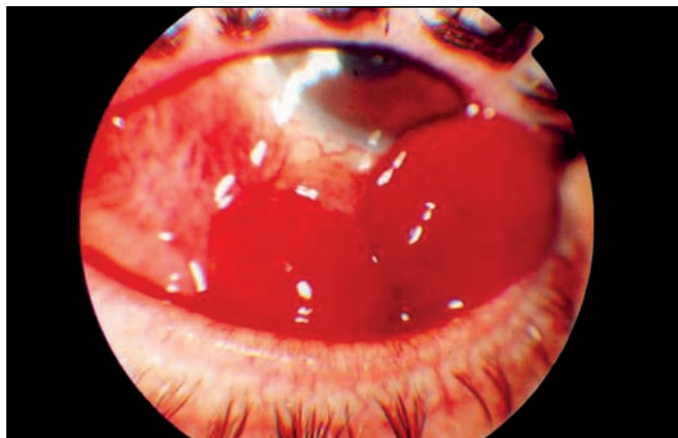


Figure 1 - Tumors growing on the conjunctival sac and protruding from the lower lid of the left eye

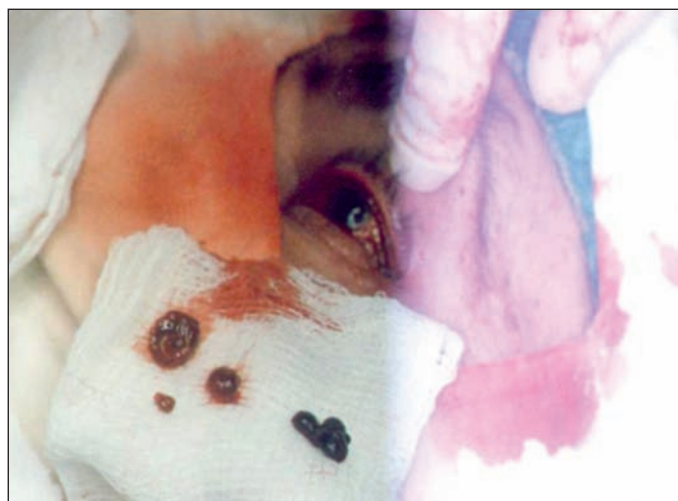

Figure 2 - Pyogenic granuloma removal surgery - showing the pathological material

## DISCUSSION

The cysts and granulomas in the related case were diagnosed as pyogenic granulomas, which usually grow on vascular and elastic tissues when related to post surgery. Thus, some hypotheses could be proposed. An inflammatory process may have occurred due to dynamic eye movements, or an exposure to external contact that would be capable of causing local trauma; such process would eventually culminate in a tumor. Then, it could explain the formation on the conjunctiva, eyelids and extraocular muscles. Another hypothesis could be the healing process due to the use of no absorbable suture materials such as dacron or mersilene, or even absorbable polymers such as Vicryl® used at the surgery for conventional retinal detachment. Furthermore, a less elastic tissue such as the Tenon's capsule

could possibly act as an adjuvant in the case of subconjunctival friction, even when associated with blinking.

Pyogenic granuloma is not only due to buckling surgery and it also can occur after any ocular muscle surgery. No implanted artificial material can be considered totally inert to the body and they can stimulate chronic inflammatory responses. An initial acute inflammatory reaction and a chronic granulomatous tissue reaction may persist even after encapsulation has occurred.

Scleral buckling materials constitute foreign bodies and are therefore at risk for infection, extrusion and inflammatory reaction. Infection appears two weeks to two months after the surgery, but cases of infection have been reported in up to 13 years. Clinical signs include fistula and granuloma formation, purulent discharge and subconjunctival hemorrhage. There may be subretinal exudates and vitreitis over the buckle. Progression of the infection may lead to abscess formation with increasing pain, chemosis and proptosis. The effective management of infected scleral buckling material usually requires removal of any silicone material.

The simple removal of pyogenic granuloma, in the case above mentioned did not result in its complete elimination. Considering the fact that there might be conditions which perpetuate the formation of the tumors and their recurrence, it would be better to remove either the entire Tenon and the subconjunctival tissue sutures. Recurrent cases could indicate the use of antimetabolite drugs such as 5-fluorouracil (5-FU) and Onco thiotepa (used after pterygium surgery). Refractory cases have also occurred and brachiotherapy with radioisotope plaque was indicated<sup>(4-5)</sup>.

## RESUMO

Os autores relatam um caso de granuloma piogênico subconjuntival pós retinopexia com introflexão escleral. É uma complicação pós-cirúrgica incomum neste tipo de procedimento.

**Descritores:** Córnea/patologia; Recurvamento da esclera; Descolamento retiniano/cirurgia; Neoplasias da túnica conjuntiva; Granuloma piogênico; Humano; Masculino; Meia-idade; Relatos de casos [Tipo de publicação]

## REFERENCES

1. Googe JM, Mackman G, Peterson MR, Richey MA, Apple DJ, Brick DC, et al. Pyogenic granulomas of the cornea. *Surv Ophthalmol.* 1984;29(3):188-92.
2. Horton JC, Mathers WD, Zimmerman LE. Pyogenic granuloma of the palpebral conjunctiva associated with contact lens wear. *Cornea.* 1990;9(4):359-61.
3. Espinoza GM, Lueder GT. Conjunctival pyogenic granulomas after strabismus surgery. *Ophthalmology.* 2005;112(7):1283-6.
4. Gunduz K, Shields CL, Shields JÁ, Zhao DY. Plaque radiation therapy for recurrent conjunctival pyogenic granuloma. *Arch Ophthalmol.* 1998;116(4):538-9.
5. Boockvar W, Wessely Z, Ballen P. Recurrent granuloma pyogenicum of the limbus. *Arch Ophthalmol.* 1974;91(1):42-4.