

Conjunctival tattoo: report on an emerging body modification trend

Tatuagem conjuntival: relato de uma crescente tendência de modificação do corpo

NATASHA FERREIRA SANTOS DA CRUZ¹, SÉRGIO FERREIRA SANTOS DA CRUZ², DANIEL HARUO ISHIGAI¹, KATIA SANTANA SANTOS¹, SÉRGIO FELBERG¹

ABSTRACT

We report the case of a patient who received conjunctival tattooing for cosmetic purposes with associated complications. A 28-year-old male experienced severe ocular pain after undergoing conjunctival tattooing. Slit-lamp examination revealed blue deposits over the conjunctiva in association with intense conjunctival edema and a 4+ anterior chamber cellular reaction. The patient underwent clinical treatments to control ocular inflammation. Two months after the injury, the patient was still in follow-up to ensure that any further complications were managed and documented. This unusual case of conjunctival tattooing resulted in conjunctival edema and anterior uveitis. Because of the increasing popularity of eyeball tattooing, the potentially severe complications of this procedure may become more common.

Keywords: Tattooing/adverse effects; Uveitis, anterior/etiology; Conjunctival diseases; Ink; Coloring agents/adverse effects

RESUMO

Relatamos um caso de um paciente que realizou tatuagem conjuntival para fins cosméticos com complicações associadas. Um homem de 28 anos de idade apresentou dor ocular importante após tatuagem conjuntival. O exame de lâmpada de fenda revelou depósitos azuis sobre a conjuntiva, associados a um intenso edema conjuntival e uma reação de câmara anterior de 4+ de células. O paciente foi submetido a tratamentos clínicos para controlar a inflamação ocular. Dois meses após o ocorrido, o paciente ainda estava em acompanhamento para garantir que quaisquer outras complicações fossem gerenciadas e documentadas. Um caso incomum de tatuagem conjuntival resultou em edema conjuntival e uveíte anterior. Devido à crescente popularidade da tatuagem no globo ocular, complicações potencialmente graves deste procedimento podem se tornar mais comuns.

Descritores: Tatuagem/efeitos adversos; Uveítis anterior/etiologia; Doenças da túnica conjuntiva; Tinta; Colorantes/efeitos adversos

INTRODUCTION

Medical conjunctival micropigment tattooing has already been used for cosmetic purposes in eyes with poor visual potential with satisfactory results and with no postoperative complications⁽¹⁾.

However, injection of a colored dye at the ocular surface is a new phenomenon in body modification that is becoming increasingly popular. As previously reported, eyeball tattooing may result in complications, such as inadvertent penetration of the globe and retinal detachment⁽²⁾. This case report describes a patient who received conjunctival tattooing for cosmetic purposes, which resulted in conjunctival edema and anterior uveitis.

CASE REPORT

A 28-year-old male presented with severe ocular pain, ocular edema, and photophobia in both eyes. The patient stated that he underwent conjunctival tattooing in both eyes 3 days prior at a tattoo studio. According to the patient, the blue pigment used was conventional ink used to tattoo the skin, known as "electric ink," which was injected under the conjunctiva at numerous sites in each eye. He also had other tattoos on his face and over his entire body. The patient denied having any systemic or ocular diseases.

At the time of admission, his visual acuity was 20/25 in the right eye and 20/25 in the left eye. The pupillary reflexes were normal. On slit-lamp examination, blue deposits from the tattooing pigment were noted over the conjunctiva, and were associated with intense conjunctival swelling and a 4+ anterior chamber cellular reaction (Figures 1 and 2). There was no evidence of globe penetration.

No other abnormalities were identified. Fundus examination, intraocular pressure (IOP), and gonioscopic results were also normal.

The initial clinical treatment for the anterior uveitis comprised 0.1% dexamethasone and 1% tropicamide eye drops. After 1 month, control of inflammation was achieved, and the conjunctival swelling completely disappeared.

According to the product description, the ink used for the tattoo was primarily composed of an aqueous suspension of vegetable pigments and a blend of nonionic surfactants.

The patient is still in follow-up to ensure that any further complications are managed and documented. For the time being, the conjunctival edema has regressed completely, as well as the uveitis. Additionally, there were no signs of ocular penetration or increased IOP.

DISCUSSION

Although tattooing is an ancient practice, there has been a dramatic increase of its use as a cosmetic and decorative body art form⁽³⁾. In addition, eyeball tattooing has gradually become more popular worldwide.

Skin tattoo inks are typically composed of poorly soluble or insoluble pigments and dispersants in which the pigments are suspended, plus other additives for preservation or to alter the viscosity of the ink⁽⁴⁾. Whereas colored tattoo inks traditionally contained metals, modern colored inks contain organic pigments, such as azo dyes for red and yellow inks and phthalocyanines for blue and green inks. Of all the blue pigments, the synthetic organic pigment phthalocyanine is least likely to cause reactions because it is more stable than cobalt- and chromium-containing inks⁽⁵⁾.

Submitted for publication: May 22, 2017
Accepted for publication: July 17, 2017

¹ Department of Ophthalmology, Irmandade da Santa Casa de Misericórdia de São Paulo, São Paulo, SP, Brazil.

² Universidade do Estado do Pará, Belém, PA, Brazil.

Funding: No specific financial support was available for this study.

Disclosure of potential conflicts of interest: None of the authors have any potential conflict of interest to disclose.

Corresponding author: Natasha Ferreira Santos da Cruz. Rua Dr. Cesário Mota Júnior, 112, São Paulo - SP 01121-020 - Brazil - E-mail: natashascruz@gmail.com

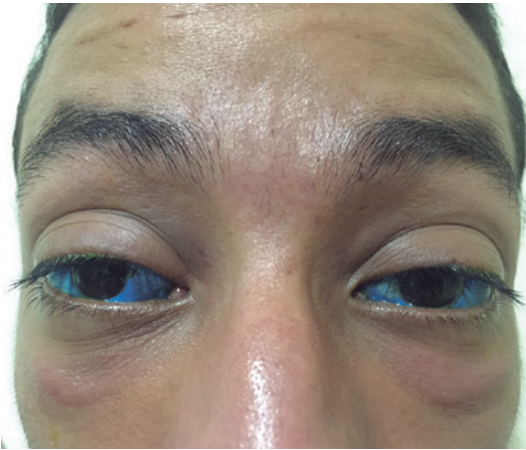


Figure 1. An ectoscopic view of conjunctival tattooing.

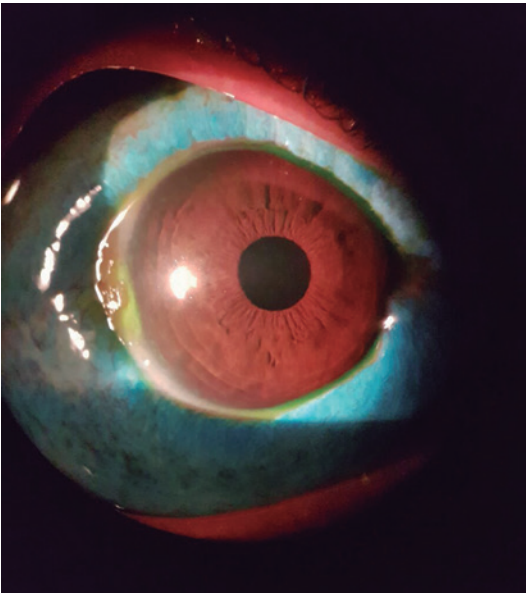


Figure 2. Blue deposits over the conjunctiva with conjunctival swelling.

Previous studies have reported adverse health effects from tattoos, ranging from skin irritation to tumor formation⁽⁶⁾. In addition, although the exact cause is unknown, the majority of reported cases of sarcoidal

tattoo reaction, occurring as a manifestation of systemic sarcoidosis, involved the blue areas of skin tattoos⁽⁷⁾.

Conjunctival tattooing is mainly performed with no surgical instruments or microscope, which may increase the risks of ocular complications. However, while there is insufficient information available on the complications of eye tattoos, because the procedure involves the introduction of a needle into the conjunctiva, there could be a risk of globe penetration, toxicity, inflammation, conjunctival edema, inadvertent injection of pigment, traumatic cataract, secondary glaucoma, retinal detachment, and endophthalmitis. Most important, it also confers a risk of blindness^(2,8,9).

Furthermore, it is important to note that even tattoos that are not applied directly to the eye can still result in ocular complications. There have been related cases of uveitis associated with a dermal tattoo caused by a delayed allergic reaction to the injected pigment, which resulted in simultaneous inflammation of the eyes and skin⁽¹⁰⁾.

As shown in the present case, there are potential risks associated with conjunctival tattooing of the eye, although there have been no previous reports of simultaneous conjunctival swelling and uveitis.

CONCLUSIONS

There are no safety procedures for cosmetic conjunctival tattooing. The general population should be aware of this limitation because of the increasing popularity of this new procedure that can result in serious complications. It is therefore important to notify persons interested in this art form about the risks of blindness and other complications associated with the procedure.

REFERENCES

1. Paik JS, Lee YK, Doh SH. A patient with combined corneal and ingrowing conjunctival tissue tattooing by micropigmentation method. *J Craniofac Surg.* 2014;25(2):e170-2.
2. Jalil A, Ivanova T, Bonshek R, Patton N. Unique case of eyeball tattooing leading to ocular penetration and intraocular tattoo pigment deposition. *Clin Exp Ophthalmol.* 2015;43(6):594-6.
3. Ortiz AE, Alster TS. Rising concern over cosmetic tattoos. *Dermatol Surg.* 2012;38(3):424-9.
4. Neale PA, Stalter D, Tang JY, Escher BI. Bioanalytical evidence that chemicals in tattoo ink can induce adaptive stress responses. *J Hazard Mater.* 2015;296:192-200.
5. Thum CK, Biswas A. Inflammatory complications related to tattooing: a histopathological approach based on pattern analysis. *Am J Dermatopathol.* 2015;37(1):54-66.
6. Wenzel SM, Rittmann I, Landthaler M, Bäuml W. Adverse reactions after tattooing: review of the literature and comparison to results of a survey. *Dermatology.* 2013;226(2):138-47.
7. Antonovich DD, Callen JP. Development of sarcoidosis in cosmetic tattoos. *Arch Dermatol.* 2005;141(7):869-72.
8. Brodie J, El Galhud H, Bates A. A case of episcleral tattooing-an emerging body modification trend. *BMC Ophthalmol.* 2015;15:95.
9. Cruz NF, Santos KS, Farah ML, et al. Conjunctival tattoo with inadvertent globe penetration and associated complications. *Cornea.* 2017;36(5):625-627.
10. Ostheimer TA, Burkholder BM, Leung TG, Butler NJ, Dunn JP, Thorne JE. Tattoo-associated uveitis. *Am J Ophthalmol.* 2014;158(3):637-43.e1.