

Penetrating keratoplasty and anterior chamber intraocular lens implant: Outcomes in aphakic and pseudophakic bullous keratopathy

Ceratoplastia penetrante e implante de lente intra-ocular de câmara anterior: pacientes portadores de ceratopatia bolhosa pseudofácica e afácica

Paulo E. C. Dantas⁽¹⁾
M. Cristina Nishiwaki-Dantas⁽²⁾
Richard L. Abbott,⁽³⁾
Robert G. Webster,⁽⁴⁾
Wayne E. Fung.⁽⁵⁾

SUMMARY

Concerns on anterior chamber intraocular lens (AC IOL) implantation are often raised due to the association of complications with the old-styled closed-loop AC IOL, especially those implanted in the mid-1980's. Although those lenses are no longer marketed, there are still more than 200,000 patients with this type of lens in place in the United States. There are evidences that the new-style open-loop AC IOL may not be associated with the problems caused by closed-loop AC IOL.

We report our experience in patients with pseudophakic bullous keratopathy (PBK) and aphakic bullous keratopathy (ABK) that underwent penetrating keratoplasty (PK) associated with AC IOL exchange (pseudophakic) or secondary implantation (aphakic).

Keywords: Penetrating keratoplasty; Intraocular lens; Secondary implant; Aphakic bullous keratopathy; Pseudophakic bullous keratopathy

INTRODUCTION

Aphakic and pseudophakic bullous keratopathy accounted for nearly 40% of all keratoplasties¹ and had lead the indications for penetrating keratoplasty (PK) in the United States¹⁻³ in the 80's decade. Besides closed-loop anterior chamber intraocular lens (AC IOL) are no longer marketed, there are more than 200,000 patients in the United States with these lens in place⁴. To date, there are no definitive data with regards to the choice of replacement lens design and method of lens fixation. There has been some controversy over the best management of the intraocular lens implant (IOL) in these patients during PK. Generally, there are three traditional choices⁵

- retention of aphakia or of the old IOL;
- removal of the old IOL, rendering

the eye aphakic;

- removal of the old IOL and exchanging it for a new IOL, or inserting a secondary implant into the aphakic eye.

Throughout the years it became clear that iris plane, closed loop AC IOLs and dislocated IOLs should be removed^{5,6}. Hence, in these conditions the patient should have an IOL exchange at the time of the PK. There are controversies and disagreement however in where to best place the secondary IOL implant in these eyes (without support for a posterior chamber (PC IOL), if in the anterior chamber or in the posterior chamber.

We report in this paper our experience in 25 consecutive patients submitted either to a combined PK and IOL exchange (pseudophakic) or PK and secondary IOL implantation (aphakic) using a flexible open-loop AC IOL.

From Department of Ophthalmology of Santa Casa de São Paulo, Brazil. Department of Ophthalmology, University of California, San Francisco, USA. Department of Ophthalmology, California Pacific Medical Center, San Francisco, USA

⁽¹⁾ Assistant, Corneal and External Disease Service, Santa Casa de São Paulo

⁽²⁾ Director, Corneal and External Disease Service, Santa Casa de São Paulo

⁽³⁾ Director, Corneal and External Disease, UCSF

⁽⁴⁾ Director, Corneal and External Disease Service, CPMC

⁽⁵⁾ Director, Retina and Vitreous Service, CPMC

Correspondence to: Paulo E.C. Dantas - Rua Martinico Prado 26, conj. 181/182 - CEP 01224-010 - São Paulo - Brazil - Tel: (011) 224-0122 - Fax: (011) 606-5306 - E-mail: <speyecare@originet.com.br>

The authors do not have commercial interest in the products and instrumental mentioned in this paper.

MATERIAL AND METHODS

The chart of 25 patients who underwent PK for pseudophakic (8 patients=32%) or aphakic (17 patients = 68%) bullous keratopathy with IOL exchange/secondary implantation between November 1990 and September 1994 were reviewed.

Exclusion criterion for AC IOL implant was the finding of peripheral anterior synechiae (PAS) more than 90° of the AC angle, previously seen by gonioscopy with a three-mirror lens or during the surgery.

Donor cornea were preserved in Optisol or K-Sol and stored at 4°C. All surgeries were done by one of the three corneal surgeons (PECD, RLA, MCND).

Surgical technique consisted of PK combined with either an IOL exchange (pseudophakic patients) or secondary implantation (aphakic patients) of an open-loop AC IOL using the UV Kelman Omnifit II (IOLAB, Claremont, CA). Surgeries were performed under local or general anesthesia. Sizing of the AC IOL was determined by measuring the horizontal limbal diameter (white-to-white) with a caliper and adding 1 mm to the measure. Lid speculum was applied and no Flieringa ring was used. A 7.75 mm donor button was punched out from the endothelial side using a disposable trephine blade (Weck, USA). The recipient cornea was trephined to two-third thickness using a 7.5 mm disposable trephine blade and handle. The AC was entered by a microsharp blade (75 Beaver, USA). The host cornea was excised using right and left corneal scissors. When possible, lysis of goniosynechiae was performed with a Barraquer iris sweep or Vannas scissors. No extensive iris manipulation was done. In pseudophakic patients, all the lenses were carefully removed by cutting their haptics to easy removal of the optics and then sliding out the haptics from their iris adhesions. If bleeding was present, either irrigation with sodium

hyaluronate or direct pressure with a Weck cell sponge were enough to control it. No cautery was used. Anterior vitrectomy was performed when necessary and anterior chamber was reformed with balanced salt solution (BSS). A flexible open-loop AC IOL was implanted into the AC angle through an open sky approach, positioned orthogonal to the orientation of the explanted lens and, if the surgeon was sure of its good implantation, the AC IOL and the AC angle were then coated with sodium hyaluronate and the donor button was sutured into place using 16 interrupted 10-nylon sutures. At the end of the sutures, sodium hyaluronate was exchanged by BSS. The knots were left on the donor side and the surgeon checked for the watertight condition of the surgical wound with the Weck cell sponges. Subconjunctival injection of steroid and antibiotic were given and the eye was patched and covered with an acrylic shield.

TABLE 1

Best corrected visual acuity (BCVA) before and after penetrating keratoplasty (PK) associated to anterior chamber intraocular lens (ACIOL) implantation in aphakic (ABK) and pseudophakic bullous keratopathy (PBK).

BCVA	Number of patients (%)	
	Preop	Postop
<20/200	16 (64%)	3 (12%)
20/50 to 20/100	8 (32%)	10 (40%)
>20/40	1 (4%)	12 (48%)

The patients were examined in the postoperative days 1, 7, 15, 30 and then monthly. The clinical parameters assessed included best corrected visual acuity, biomicroscopy, gonioscopy with a three-mirror lens, tonometry with TonoPen and Goldman tonometer and funduscopy by a retina specialist (WEF). When necessary, angiofluoresceinography by ImageNet (Topcon, Japan) was done.

All types and styles of explanted IOLs were identified and recorded in the chart. Complications when present were also recorded in the chart.

RESULTS

Our series consisted of 13 females (52%) and 12 males (48%), with mean age of 74 years-old (range from 46 to 93). Seventeen patients (68%) had aphakic bullous keratopathy (ABK) and eight (32%) pseudophakic bullous keratopathy (PBK). The mean follow-up was 17 months (range from 3 to 45) postoperatively. Fifteen patients (60%) were seen for a period longer than 11 months and 10 (40%) for less than 11 months.

Table 1 displays the best corrected visual acuity pre and postoperatively.

Table 2 displays the type of explanted IOL in each given case.

During the follow-up period, 24 corneas (96%) remained clear. Just one patient (4%) had opaque cornea second-

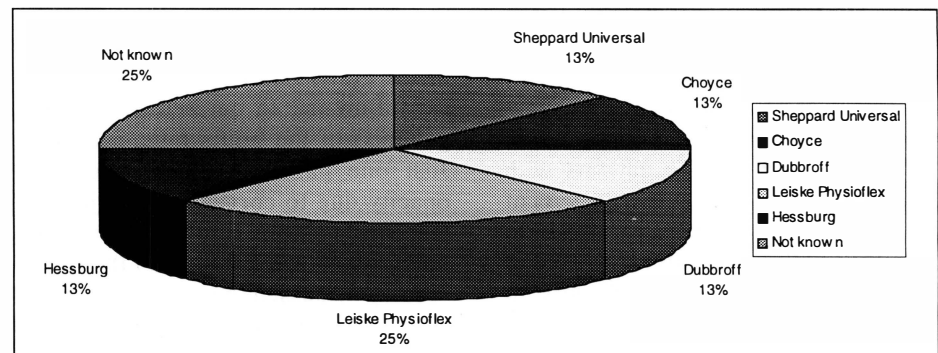


Table 2. Types of explanted AC IOL in pseudophakic bullous keratopathy and penetrating keratoplasty

*Penetrating keratoplasty and anterior chamber intraocular lens implant:
Outcomes in aphakic and pseudophakic bullous keratopathy*

TABLE 3
Comparative final best corrected visual acuity in four studies

Data	Zaidman and Goldman	Hassan et al	Koenig et al	Dantas et al
Postop BCVA				
<20/200	22%	25%	25%	12%
20/50 to 20/100	33%	32.5%	40%	40%
>20/40	31%	42.5%	35%	48%
Number of patients				
Pseudophakic	35	31	20	8
Aphakic	11	9	-	17
Follow-up	15 months (range 3-32 mo)	25 months (range 3.5-51 mo)	15 months (range 4-45 mo)	17 months (range 3-45 mo)

dary to allograft rejection. This patient belonged to the ABK group.

The main complications associated with ABK (17 patients) were age related macular degeneration (ARMD) (2=11,8%), cystoid macular edema (CME) (1=5,9%) and graft failure (1=5,9%). In the PBK group (8 patients), complications were CME (1=12,5%) and ARMD (1=12,5%).

No progressive sinechiae were noted in any case.

DISCUSSION

Many concerns are raised on AC IOL implantation because of the associated complications identified with several previous and outdated AC IOL, especially the closed-loop lens style^{1-3, 6, 7}. They reflect a general distrust of AC IOL, mainly the highly publicized closed-loop AC IOL of the mid-1980's¹. There are evidences that Kelman-style AC IOL may not be associated with the problems caused by old styles of closed-loop AC IOLs^{4-6, 11, 15}.

Zaidan and Goldman⁵ in a prospective study involving 36 patients in 1990, reported 11(31%) patients with best corrected visual acuity (BCVA) of 20/40 or better, 12 (33%) with 20/50 to 20/100, 8 (22%) with 20/200 to 20/400 and, 5 (14%) with count fingers to light perception. Major causes of vision less than 20/40 were CME (9 patients=25%), glaucoma (5 patients

=13.8%), graft failure (4 patients=11.1%) and high astigmatism (3 patients=8.33%). Thirty two patients (90%) of the grafts remained clear at the average follow-up of 15 months (range from 3-32 months).

Hassan and colleagues¹¹ in 1991 comparing iris-sutured PC IOL with Kelman-style AC IOL during PK in 40 patients (9 ABK and 31 PBK) reported 42.5 % with BCVA of 20/40 or better, 32.5% with 20/50 to 20/100 and, 25% with 20/200 or less. In this series, 95% (38 patients) of the grafts remained clear. New glaucoma incidence was 22.5%. Main complications were CME in 16 patients (15%), ARMD in 4 (10%), graft rejection in 5(12,5%), retinal detachment in 1 (2.5%) and, sterile corneal ulceration in 1 patient (2.5%).

Koenig and colleagues¹² in 1990 reported 35% of the patients with 20/40 or better and 25% with 20/50 to 20/100. All grafts remained clear at the end of the study.

In the previous studies, 90 to 100% of the grafts remained clear at the latest follow-up. In our series, 96% (24 patients) of the grafts remained clear. Just one patient developed corneal opacity due to corneal graft rejection. Our study shows similar results post-operatively (see Table 3) to those previously discussed. No new or secondary glaucoma was noted, probably due to absence of progressive sinechiae at the latest follow-up.

Table 3 compares our results to other similar previous studies.

The most common style of explanted and exchanged AC IOL was closed-loop AC IOL (see table 2). No open-loop or iris-fixation IOL was found in any case.

The main disadvantage of AC IOL is the possible deleterious effect on the corneal endothelium and the AC angle^{13, 14}. These observations, however were generally done at a time when most of AC IOL were closed-loop^{1, 7, 10}. Studies have shown that Kelman-style open-loop lenses may have the same effect on the corneal endothelium as sutured posterior chamber (PC) IOLs^{10, 15}. Review of the literature has shown basically equivalent long-term results of PK and IOL exchange using both Kelman-style, flexible, open-loop AC IOL and, acapsular fixation of sutured posterior chamber (PC) IOL. In a large group of explanted AC IOLs (4104), Arffath et al.¹⁶ concluded that complications with closed-loop IOLs were 3 to 4 times higher than with open-loop AC IOLs, providing evidence to conclude that the flexible, one-piece, ball PMMA, open-loop AC IOL will still play a useful role in limited and selected clinical indications. The current generation of open-loop AC IOLs is technically easy to implant, inducing little or almost no iris manipulation, therefore less surgical time is required, hence less complications.

We obtained good visual and functional results in our series comparing to other publications describing the implantation of an open-loop AC IOL during PK. Our study brought about more information and data regarding the implantation of AC IOL in cases where exchanging an old-styled AC IOL or a secondary implant in acapsular patients is necessary. Our results agree with other previous studies and, allow us to state that implanting an open-loop AC IOL in patients with PBK and ABK can give good postoperative results with functional vision

and it is our procedure of choice to treat these very difficult cases.

RESUMO

Devido às complicações associadas às lentes intra-oculares de câmara anterior do tipo "alça fechada", muito usada nos anos 80, o uso de lente de câmara anterior tem sofrido críticas, ora relacionadas à sua influência sobre a fisiologia do endotélio, ora relacionadas ao comprometimento do seio ciliar, levando à progressiva formação de sinéquias anteriores. Essa preocupação se deve ao grande número de artigos publicados relacionando às lentes de "alça fechada", a chamada "epidemia de ceratopatia bolhosa" durante o início dos anos 90. Encontramos porém evidências na literatura dissociando as modernas lentes de câmara anterior de "alça aberta" de tais complicações.

Neste estudo reportamos nossa experiência com implante lentes de câmara anterior de "alça aberta" em pacientes portadores de ceratopatia bolhosa pseudofácica (explante com substituição) e afácica (implante se-

cundário) em pacientes submetidos a concomitante transplante penetrante de córnea.

REFERENCES

- SMITH, P. W.; WONG, S. K.; STARK, W. J. et al. - Complications on semiflexible, closed-loop anterior chamber intraocular lenses. *Arch Ophthalmol*, **105**: 52, 1987.
- HOFFER, K. J. - Rapid fibrosis of ORC Stableflex haptics. *Am Intraoc Implant Soc. J*, **10**: 470, 1984.
- KOENIG, S. B.; SOLOMON, J. M. - Removal of closed-loop anterior chamber intraocular lenses during penetrating keratoplasty. *Cornea*, **6**: 207, 1987.
- KORNMEHL, E. W.; STEINERT, R. F.; ODRICH, M. G.; STEVENS, J. B. - Penetrating keratoplasty for pseudophakic bullous keratopathy associated with closed-loop anterior chamber intraocular lenses. *Ophthalmology*, **97**(4): 407, 1990.
- ZAIDMAN, G. W.; GOLDMAN, S. - A prospective study on the implantation of anterior chamber intraocular lenses during keratoplasty for pseudophakic and aphakic bullous keratopathy. *Ophthalmology*, **97**(6): 757, 1990.
- COLI, A. F.; PRICE, F. W.; WHITSOM, W. E. - Intraocular lens exchange for anterior chamber intraocular lens-induced corneal endothelial damage. *Ophthalmology*, **100**(3): 385, 1993.
- WARING, G. O.; STULTING, R. D.; STREET, D. - Penetrating keratoplasty for pseudophakic corneal edema with exchange of intraocular lenses. *Arch Ophthalmol*, **105**: 58, 1987.
- SUGAR, A.; MEYER, R. F.; HEINDEMANN, D. et al. - Specular microscopic follow-up of corneal grafts for pseudophakic bullous keratopathy. *Ophthalmology*, **92**: 325, 1985.
- APPLE, D. J.; MAMALIS, N.; LOFTFIELD, K. et al. - Complications on intraocular lenses. A historical and histopathological review. *Surv Ophthalmol*, **29**: 1, 1984.
- SOONG, H. K.; MUSCH, D. C.; KOWAL, V. et al. - Implantation of posterior chamber intraocular lenses in the absence of lens capsule during penetrating keratoplasty. *Arch Ophthalmol*, **107**: 660, 1989.
- HASSAN, T. S.; SOONG, H. K.; SUGAR, A.; MEYER, R. F. - Implantation of Kelman-style, open-loop anterior chamber lenses during keratoplasty for aphakic and pseudophakic bullous keratopathy. *Ophthalmology*, **98** (6): 877, 1991.
- KOENIG, S. B.; McDERMOTT, M. L.; HYN-DIUK, R. A. - Penetrating keratoplasty and intraocular lens exchange for pseudophakic bullous keratopathy associated with closed-loop anterior chamber intraocular lens. *Am J Ophthalmol*, **108**: 43, 1989.
- SOONK, H. K.; MEYER, R. F.; SUGAR, A. - Posterior chamber IOL implantation during keratoplasty for aphakic or pseudophakic corneal edema. *Cornea*, **6**: 306, 1987.
- SMITH, R. E.; BEATTY, R. F.; CLIFFORD, W. S. et al. - Intraocular lens selection for pseudophakic and aphakic bullous keratopathy. In Cavanaugh HD, ed. *The Cornea: Transactions of The World Congress on the Cornea III*, New York, Raven Press, 1988:327-321.
- KOENIG, S. B.; APPLE, D. J.; HYN-DIUK - Penetrating keratoplasty and intraocular lens exchange: open-loop anterior chamber lenses versus sutured posterior chamber lenses. *Cornea* **13**(5): 418, 1994.
- AUFFARTH, G. U.; WESENDAHL, T. A.; BROWN, S. J. et al. - Are there acceptable anterior chamber intraocular lenses for clinical use in the 1990s?. *Ophthalmology*, **101**: 1913-22, 1994.

Sociedade Brasileira de Laser e Cirurgia em Oftalmologia (BLOSS) "BLOSS-NET"

Se você ainda não é membro da BLOSS-NET mande o seu correio eletrônico para o número de fax abaixo. Nós o colocaremos na rede. Ao vivo, on-line, com muitos dos melhores cirurgiões em oftalmologia do Brasil e também com a presença de vários colegas latino-americanos, norte-americanos e europeus.

Uma excelente oportunidade educacional e de intercâmbio de informações. Gratuito. A participação na BLOSS também é gratuita. Associe-se.

Fax: (011) 573-4002 - A/C: Dr. Paulo Schor - E-mail: bloss@pobox.com