

Analysis of the histology of the scar bladder and biochemical parameters of rats with a solitary kidney undergoing immunosuppression with tacrolimus¹

Ricardo Cavalheiro Cavalli^I, Renato Tambara Filho^{II}, Regina de Paula Xavier Gomes^{III}, Djanira Aparecida da Luz Veronez^{IV}, Julio Slongo^V, Rogério de Fraga^{VI}

DOI: <http://dx.doi.org/10.1590/S0102-86502014000800005>

^IFellow Master degree, Postgraduate Program in Surgical Clinic, School of Medicine, Federal University of Parana (UFPR), Curitiba-PR, Brazil. Conception and design of the study, surgical procedures, acquisition and interpretation of data, manuscript writing.

^{II}PhD, Chairman, Full Professor of Urology, School of Medicine, UFPR, Curitiba-PR, Brazil. Interpretation of data, critical revision.

^{III}PhD, Volunteer, Faculty of the School of Medicine, UFPR, Curitiba-PR, Brazil. Acquisition and interpretation of data.

^{IV}PhD, Associate Professor of Anatomy, School of Medicine, UFPR, Curitiba-PR, Brazil. Acquisition and interpretation of data.

^VGraduate student, School of Medicine, UFPR, Curitiba-PR, Brazil. Surgical procedures, acquisition and interpretation of data.

^{VI}PhD, Associate Professor of Anatomy, School of Medicine, UFPR, Curitiba-PR, Brazil. Conception and design of the study, interpretation of data, critical revision.

ABSTRACT

PURPOSE: To evaluate bladder histology in healing and biochemical analysis of rats with single kidney in ischemia/reperfusion, treated with tacrolimus.

METHODS: Fifty rats randomized into five groups. Three rats died in surgery, 47 rats divided in groups: Control (non-operated, n=10), Sham (operated without drugs, n=8), T1 (operated + tacrolimus 1mg/kg, n=10), T2 (operated + tacrolimus 0.1 mg/kg, n=10), T3 (operated + tacrolimus 10mg/kg, n=9). The surgery was: laparotomy, right nephrectomy, left kidney ischemia/reperfusion, cystotomy followed by bladder suture. After that, rats were submitted to gavage daily (Control and Sham with saline solution. T1, T2, T3 with tacrolimus in doses already mentioned). On the 14th day, after death induction, cystectomy was performed and bladder was histologically analysed. The serum urea, creatinine and tacrolimus were analysed too.

RESULTS: There was difference in serum tacrolimus in T3 compared to the other groups (p<0.05). There was higher doses of creatinine in T3 group and higher urea in groups with tacrolimus. There were significant differences among all histologic variables comparing groups with and without tacrolimus (p<0.05).

CONCLUSION: Tacrolimus associated with ischemia/reperfusion is nephrotoxic, suppresses inflammation and seems to delay the healing bladder.

Key words: Cicatrix. Bladder. Kidney. Immunosuppression. Tacrolimus. Rats.

Introduction

The repair process of wounds can be basically divided in three phases: Inflammatory with platelet accumulation, coagulation, and leukocyte migration; Proliferative which is the reparative process with re-epithelialization, neovascularization and matrix synthesis; Remodeling phase which is the period of scar contraction and collagen production¹.

Several factors affect healing, slowing the process, for example infections, hypoxia, diabetes, ionizing radiation, aging and malnutrition¹. In addition, some studies have shown that exogenous drugs inhibit healing. Chemotherapeutic agents such as adriamycin, nitrogen mustard, methotrexate, doxorubicin to inhibit cellular proliferation, the number of platelets, inflammatory cells and growth factors. The tamoxifen, an estrogen receptor modulator used for breast cancer, appears to reduce cell proliferation and the tensile strength of the wound. Glucocorticoids affect fibroblast proliferation and collagen synthesis, and reduce the amount of granulation tissue².

Tacrolimus belong to the group of calcineurin inhibitors. It has the effect of inhibiting the signal transduction between T lymphocytes, suppress B cell proliferation induced by Heper T-cells and inhibit the formation of cytotoxic lymphocytes, which are mainly responsible by transplan rejection³. It is a potent immunosuppressive however has potential side effects such as decreased reaction to the vaccine, leukopenia, thrombocytopenia, renal dysfunction, and urethral/bladder symptoms³. These effects could be related to changes in the healing of the urinary tract, which leads to further assess this issue.

The healing and the effects of immunosuppressants on various organs, such as intestine, pancreas and liver has been well described by some authors in various situations. Moreira described that tacrolimus produces histological changes such as edema, inflammatory infiltration and atrophy in the pancreas, in the presence of acute pancreatitis induced in experimental models⁴. Gama Filho published on the effects of tacrolimus in liver regeneration after partial hepatectomy in rats⁵. Vizzotto Junior quantified the inflammatory response in a study on the influence of cisplatin administered preoperatively and postoperatively on the healing of colonic anastomoses in rats⁶.

However, there are few studies in the literature that specifically addressed bladder wound healing under the influence of tacrolimus.

Our goal is to perform histopathological analysis of bladder healing and biochemical analysis of rats with a single kidney subjected to ischemia and reperfusion,

immunosuppressed with tacrolimus, in an attempt to fill part of the gap in the current literature.

Methods

The study was approved by the Ethics Committee on Animal Use of the UFPR, sector of biological sciences. Fifty male Wistar rats were used, average age of 120 days, from the animal vivarium of the Department of Biological Sciences - UFPR, with initial average weights between 221 to 245.1 grams. Were randomly divided into five groups of 10 animals, however three rats died during surgery, leaving 47 rats in the experiment (divided in groups - Chart 1). The control group was not operated. The four remaining groups were operated, following aseptic technique.

The surgical procedure consisted of laparotomy with about 5cm, right nephrectomy, the left renal vascular clamping for 20 minutes and subsequent reperfusion, followed by bladder dissection. In the bladder, we performed a longitudinal 1cm cystotomy in midline. After, the bladder wall was approximated in two planes (foreground with continuous suture and second with separated suture) using monofilament synthetic absorbable polyglecaprone (Caprofy[®]) 4.0 (Figure 1).

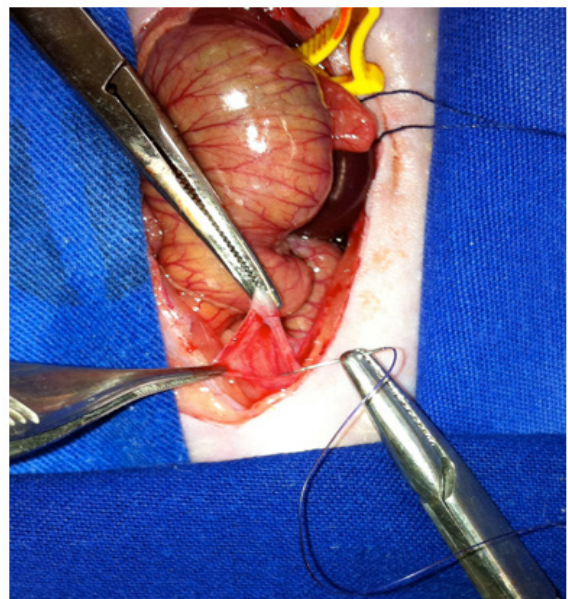


FIGURE 1 - Bladder suture + clamping left kidney.

Finally, abdominal wall closure in two planes, both with continuous suture using nylon 3.0. For the surgical procedure, the animals were anesthetized with a combination of Xylazine 10mg/kg and Ketamine 90mg/kg intraperitoneal. The groups were organized according to Chart 1.

CHART 1 - Groups.

Groups	N° of Animals	Procedimento
CONTROL (C)	10	Not operated + SS 0.9%
SHAM (SH)	8	Operated + SS 0.9%
T 1	10	Operated + Tacrolimus 1mg/kg
T 2	10	Operated + Tacrolimus 0.1mg/kg
T 3	9	Operated + Tacrolimus 10mg/kg

Throughout the procedure the rats were maintained under anesthesia. All animals received the first day of Postoperative analgesic medication intramuscularly (dipyrone) associated with daily hydration *ad libitum*. All animals received a daily dose of 0.5 ml of solution by gavage (in each group one type of solution), as appropriate gauge probe.

The animals in groups CONTROL and SHAM received by gavage, saline sodium chloride 0.9%. O T1 received tacrolimus, diluted in 0.9% saline solution at a dose of 1mg/Kg/day. O T2 received tacrolimus diluted in 0.9% saline at a dose of 0.1 mg / kg / day. O T3 received tacrolimus, diluted in 0.9% saline solution at a dose of 10mg/kg/day. The dilution was made at the time of administration due to tacrolimus molecule remain stable for only 24 hours when diluted in normal saline.

After the procedure, the animals were confined in rooms scheduled to perform light / dark cycle, fed daily under care and were then sacrificed on the 14th day of the experiment, counting as zero the day surgery. We used deep anesthesia with a combination of Ketamine and Xylazine, then thoracotomy, cardiac puncture to remove blood sample and induction of cardiac arrest by exsanguination.

Blood from cardiac puncture, about 6 to 8 ml per mouse, was stored in 2 bottles, collecting about 3 to 4 ml in each; 1 bottle prepared with ethylenediaminetetraacetic acid (EDTA) for tacrolimus dosages and one for biochemical dosages. Then the bottles were sent to the Laboratory of support, which were measured plasma levels of creatinine and urea (by enzymatic colorimetric method⁷, in Vitros device, Version 5.1 FS, Johnson and Johnson^o) and tacrolimus (by chemiluminescence method⁸, in device Architect I2000, Abbott^o).

As regards the preparation of the bladder, cystectomy was performed with full bladder section at the level of the trigone. Realized the posterior longitudinal opening to the dome, avoiding manipulation of the anterior scar. The material was made with the mucosa in contact with the filter paper, the scar bladder in the longitudinal direction, then the bladder was placed in plastic tape and fixation made in 10% formalin.

In an orderly manner, the material that was in 10% formalin was subjected to washing, diaphanization and embedded in paraffin. Paraffin blocks were for microtomy, cuts 4µm thick, and prepared on slides, stained by hematoxylin-eosin technique for analysis by light microscopy. The pathologist did not know which groups were being analyzed (blind study). The histological analysis was performed and quantification of inflammatory variables following: Neutrophils, edema, congestion, mononuclear cells, granulation tissue and fibrosis. The variables were classified as severe, moderate, mild or absent, according to the intensity in which they were found, and transformed into quantitative variables by assigning numerical index to the findings. Edema, congestion and neutrophils were considered indicative of acute inflammation, with these variables being assigned a negative sign. Mononuclear cells, granulation tissue and fibrosis were indicative of chronic inflammation, being assigned a positive sign. The possible values and variables are best shown in Table 1.

TABLE 1 - Graduation of histologic findings.

Inflammatory Variables	Histologic Findings			
	Intense	Moderate	Mild	Absent
Neutrophils	-3	-2	-1	0
Edema	-3	-2	-1	0
Congestion	-3	-2	-1	0
MMN	3	2	1	0
Granulation tissue	3	2	1	0
Fibrosis	3	2	1	0

After the assignment of a numeric index to histological findings, we conducted the sum of the indices representing acute inflammation with representatives indices of chronic inflammation in each rat, thus finding the detailed histological score. This score provides an estimate of the phase of the inflammatory process in which the scar of each animal to be. Performing the average scores of each group, we could compare the groups together. We also performed a comparison of each histological finding individualmetne between groups.

Regarding the statistical analysis, we assessed the means, standard deviations and medians of inflammatory variables, serum levels of tacrolimus, creatinine and urea. To compare the inflammatory variables between groups we used the nonparametric chi-square test, with alpha 5% (p <0.05 significance). For comparison of tacrolimus and serum urea, was used the Student t test (these variables had a normal distribution, in the Bell curve). For the analysis of creatinine values we used the nonparametric Mann-Whitney (SH and T1 had non-normal distribution).

Results

Despite three deaths during surgery, the groups were homogeneous with sufficient number of animals. The operative time was similar between the groups.

The values of tacrolimus showed that administration of different doses produced serum levels different between groups. There was statistically significant difference ($p < 0.05$) at doses of tacrolimus serum between groups T1 x T3 ($p = 0.00008$) and T2 x T3 ($p = 0.00003$). There were differences in the doses of tacrolimus between groups T1 x T2 ($p = 0.0667$), however this difference was not statistically significant (Figure 2).

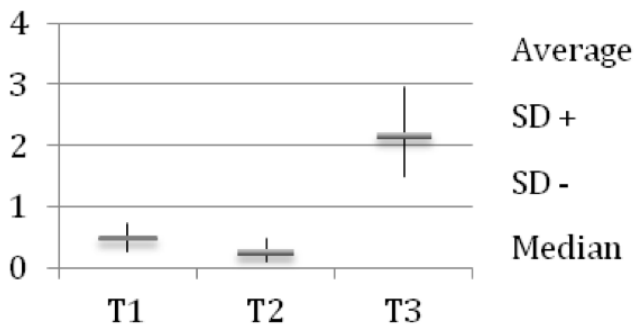


FIGURE 2 – Tacrolimus sérum values (ng/ml)

Creatinine values were not statistically different when comparing the groups C, SH, T1 and T2 together. However, there were significant statistical difference when comparing creatinine values of SH, T1 and T2 with T3 group (Figure 3).

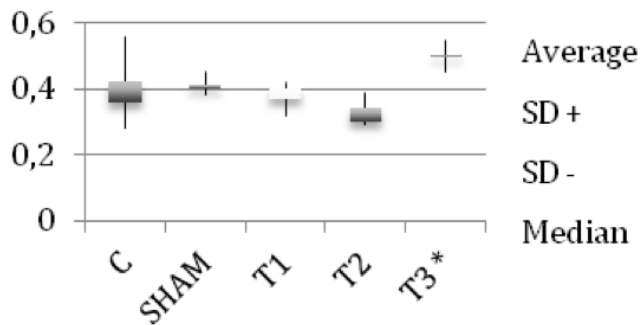


FIGURE 3 – Creatinine Serum Values (mg/dl) (* $p < 0.05$)

TABLE 2 - Average inflammatory variables.

	Neutrophils	Edema	Congestion	MMN	Granulation Tissue	Fibrosis	Detailed Score
C	0	-0.2	0	0	0	0.3	0.1
SH	-0.375	-0.625	-0.75	1.25	0.875	1.25	1.625
T1	-0.1*	-0.2*	-0.3*	1*	0.4*	1.7*	2.5
T1	-0.1*	-0.2*	-0.2*	0.8*	0.1*	2.5*	2.9
T3	0*	-0.111*	-0.444*	0.778*	0.444*	2*	2.667

In blood urea, only the comparison T1 x T2 showed no significant difference ($p > 0.05$). All other groups were compared with each other and presented difference, with $p < 0.05$ (Figure 4).

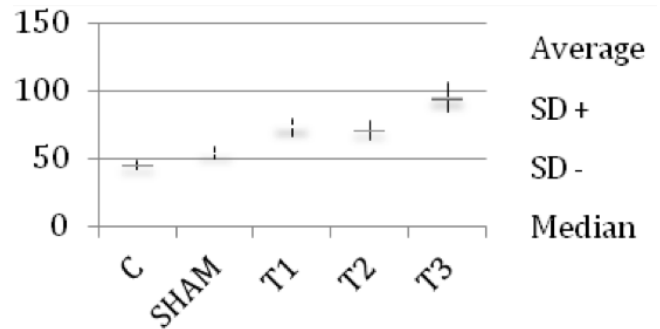


FIGURE 4 – Urea Serum Values (mg/dl)

Regarding inflammatory variables, we observed a suppression of the acute fase marker's (neutrophilic infiltration, edema and vascular congestion) of all groups with the use of tacrolimus compared to SH group ($p < 0.05$). There was no difference among the groups with tacrolimus ($p > 0.05$) (Table 2) (Figure 5).

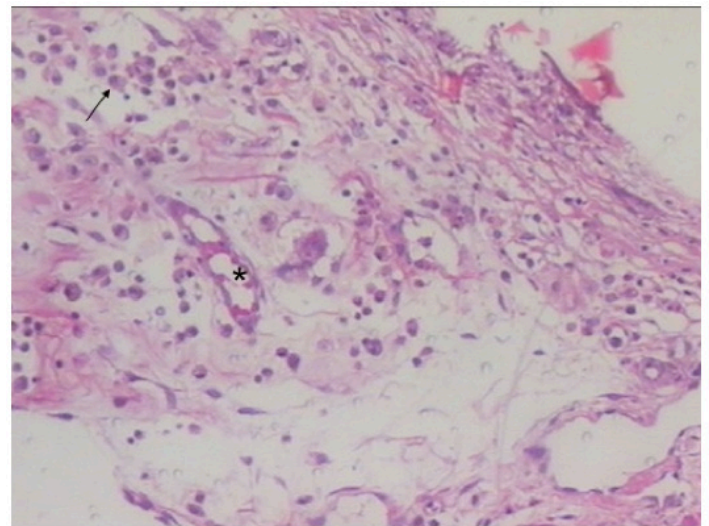


FIGURE 5 - Histology HE (Image from bladder of T1 rat) with example of edema (bright areas), vascular congestion (*) and neutrophils (arrow). Increase (x100).

We also had fewer mononuclear cells and granulation tissue in tacrolimus groups compared to the SH group ($p < 0.05$). There was a significant increase fibrosis in groups with the use of tacrolimus in comparison with the SH group ($p < 0.05$). Furthermore, there was statistical difference in fibrosis compared groups T1 x T2 ($p = 0.009$) and T2 x T3 ($p = 0.0087$) (Table 2).

The sum of the variables in the acute phase to the chronic phase variables, which we call Detailed Score (way used by pathologists to estimate the healing phase), showed positive and higher values of the groups with the use of tacrolimus, suggesting a tendency to chronicity. (Table 2).

Discussion

The biochemical and histological effects of tacrolimus has been demonstrated in various organs in various animal studies^{4,5,9}. The evaluation of creatinine and urea in Wistar rats has well established parameters under normal conditions. Reis, studying metabolic parameters of Wistar rats with diet supplement, established, in control group, normal values of urea 42.5 ± 5.7 mg/dl and creatinine 0.45 ± 0.06 mg/dl¹⁰. The creatinine values found in the groups of the present study are similar within these normal ranges cited, however T3 group had significantly higher value than the other groups ($p < 0.05$) suggesting that the drug causes a worsening of creatinine. Moreover, the urea values of all operated groups were higher than the reference values mentioned, with a significant worsening in the groups with the drug, which proves the worsening of urea with the use of tacrolimus.

Some animal studies have demonstrated analysis and changes of renal function in several ways. Santos *et al.*¹¹, conducted a unilateral nephrectomy in rats and tested the effect on the remaining kidney of 2 and 4 hours of pneumoperitoneum. Described the function and renal morphology of these mice are not changed significantly. Cologna *et al.*¹² studied the effect of Cyclosporine in models of renal ischemia and reperfusion. Concluded that Cyclosporin A had a protective effect on renal function and reduced the severity of tissue damage in kidneys subjected to normothermic ischemia and 40 minutes later reperfusion. Inácio *et al.*⁹ studied the nephrotoxic effects of tacrolimus in experimental tumor models (Walker 256 carcinosarcoma inoculated in murine kidneys). Found concentrations of creatinine significantly higher in groups with tumor subjected to the use of tacrolimus compared to the groups that used only tacrolimus (1.01 ± 0.30 x 0.71 ± 0.16) and compared to the groups that had only tumor ($1,01 \times 0.30 \pm 0.56 \pm 0.03$)⁹.

In the present study, the effect of tacrolimus showed deterioration in renal function with elevated serum creatinine

and urea, in mice with a single kidney subjected to ischemia and reperfusion, when compared to mice that did not use the drug. Nephrotoxicity also appears to be dose-dependent, with progressive worsening of urea parallel to increase the dose of tacrolimus in groups (Figure 4).

Despite the presence of important aspects similiares to a kidney transplant like renal ischemia/reperfusion and bladder healing, in this study there was no antigenicity factor (generated by a graft). The antigenicity is the main reason for the use of an immunosuppressant in renal transplantation, however, when an immunosuppressant such as tacrolimus, is used without antigenicity factor, we can assess their benefits and side effects more accurately. Another important issue is the choice of the dose of tacrolimus for experiments. Ochiai *et al.*¹³ studied heterotopic cardiac allografts in rats treated with FK506 (tacrolimus), reported that the minimum daily oral dose for prolonging graft survival was 1 mg/kg/day. In the present study we used the standard dose of 1mg/kg at T1 group so that the dose tested in the T3 group (dose 10 times higher) do not become very toxic and there were early loss of animals, which would make the dose-dependent study unfeasible.

There are well established methods and criteria for evaluation of wound healing such as mechanical resistance of the scar, the rate of collagen and histological study¹⁴. As in other studies, for example Gonçalves-Filho *et al.*¹⁴, we chose not to use the analysis of mechanical resistance to prevent loss of material and technical difficulties in handling the murine bladder. The study of collagen is a good choice in the evaluation of healing, but in our study, collagen quantification was part of another segment of the research. Therefore, we chose the histological study, with analysis of acute and chronic inflammatory variables.

The type of wire used for the suture bladder, the polyglecaprone 25 (Monocryl®), an absorbable synthetic monofilament material, was chosen for the same histological study of bladder scarring by Simoes *et al.*¹⁵. This compared polyglecaprone 25 to chrome catgut sutures in the bladders of rats and concluded that the tissue behavior is similar to the 2 wires, however the calculous matrix in catgut group was observed in 46.15% of the bladders 50 days after surgery. In the group of polyglecaprone lithiasis was not observed in the same period of time¹⁵.

About the histological method, others have used it to analyze the evolution of healing efficiently. Vizzoto Junior *et al.*⁶ suggested that cisplatin, chemotherapy drug, causes a slowing in the healing of colonic anastomoses. He used the method of grading histological scores and the same inflammatory variables (neutrophils, edema, congestion, MMN, granulation tissue and fibrosis). Found neutrophilic infiltrate and edema significantly

higher in groups that used cisplatin before colonic surgery. Also used the sum score of acute with chronic variables and classified groups according to the period of evolution of the scar. Thus reported that groups with cisplatin had a score different from non-users. Concluded that cisplatin causes slowing of healing⁶. The detailed score used in our study, in with the bladder healing in tacrolimus groups had a tendency to chronicity, was the same score used by Vizzoto Junior *et al.*⁶ to estimate the phase of the inflammatory process, although Vizzoto Junior *et al.*⁶ has calculated this score for colonic healing and using a chemotherapy drug.

Fumagalli *et al.*¹⁶ evaluating chemotherapeutic mitomycin on the healing of colonic rats, found persistence of histological findings of acute inflammation in animals who used the drug. Proposed that there would be persistent proliferative phase in the scar. Similar to these findings, but using an immunosuppressant and evaluating scar bladder, we also had histological scores suggestive of persistent proliferative phase in groups with tacrolimus.

Myers *et al.*¹⁷ presented a form that currently is well known, of graduate scores in healing wounds. Likewise, he considers acute inflammation, chronic inflammation, granulation tissue and collagen as parameters, however, in their scores, he also associates other factors such as abscess, crust, fibroblasts and epithelial regeneration. Similar to Myers *et al.*¹⁷, was used, in this study, positive and negative sign to the scores of acute and chronic inflammation respectively.

In agreement with the studies of tacrolimus laboratory manufacturer³, we found a significant decrease in neutrophil and mononuclear infiltration.

Conclusions

Ischemia for 20 minutes and reperfusion showed harmful to kidney function, causing significant impairment in urea mice compared to non-operated control. Tacrolimus also presented nephrotoxic and worsening of renal function showing dose dependent.

Tacrolimus seems to favor a delay in bladder wound healing with persistence of high rates of fibrosis even after 14 days postoperatively. Also showed significant decrease in neutrophil infiltration, vascular congestion, edema, mononuclear infiltration and granulation tissue.

References

1. Kirsner RS, Eaglstein WH. The wound healing process. *Dermatol Clin.* 1993 Oct;11(4):629-40. PMID: 8222347.

2. Thomas DR. Specific nutritional factors in wound healing. *Adv Wound Care.* 1997 Jul-Aug;10(4):40-3. PMID: 9306784.
3. Astellas Pharma US Inc: Prograf Package Insert. Deerfield, IL, Astellas Pharma US Inc, 2005.
4. Moreira M, Matias JEF, Souza CJF, Nicoluzzi JEL, Caron PE, Repka JCD. Ação do tacrolimus na pancreatite aguda experimental induzida pela arginina. *Rev Col Bras Cir.* 2011 Jul-Aug;38(4):260-5. doi: 10.1590/S0100-69912011000400010.
5. Gama Filho O, Toderke EL, Baretta GAP, Sakamoto DG, Agulham MA, Tambara EM, Matias JEF. Imunossupressão com tacrolimus favorece a regeneração hepática induzida por hepatectomia ampla em ratos. *Rev Col Bras Cir.* 2010 Jun;37(3):218-25. doi: 10.1590/S0100-69912010000300010.
6. Vizzoto Junior AO, Noronha L, Scheffel DLH, Campos ACL. Influência da cisplatina administrada no pré e no pós-operatório sobre a cicatrização de anastomoses colônicas em ratos. *J Bras Patol Med Lab.* 2003 Apr-Jun;39(2):143-9. doi: 10.1590/S1676-24442003000200009.
7. Sodré FL, Costa JCB, Lima JCC. Evaluation of renal function and damage: a laboratorial challenge. *J Bras Patol Med Lab.* 2007 Sept-Oct;43(5):329-37. doi: 10.1590/S1676-24442007000500005.
8. Kricka LJ. Chemiluminescent and bioluminescent techniques. *Clin Chem.* 1991 Sep;37(9):1472-81. PMID: 1893571.
9. Inácio CM, Dietz VA, Malafaia O, Ribas Filho JM, Nassif PAN, Czezko NG, Marcondes CAP. Action of Tacrolimus on Wistar rat kidneys implanted with Walker 256 carcinosarcoma. *Acta Cir Bras.* 2010 Jan-Feb;25(1):98-104. doi: 10.1590/S0102-86502010000100020.
10. Reis TA, Goulart PFP, Oliveira RME, Oliveira L, Abreu PS, Azevedo AO. Metabolic parameters of wistar rats subjected to diet supplemented with stevia and sugar. *Semina: Ciências Agrárias.* 2011 Out-Dez;32(4):1477-88. doi: 10.5433/1679-0359.
11. Santos LS, Tambara Filho R, Figueiredo TMS, Cravo G. Effects of the pneumoperitoneum in rats submitted to a unilateral nephrectomy: morphologic and functional study on the remnant kidney. *Acta Cir Bras.* 2005 May-Jun;20(3):195-9. doi: 10.1590/S0102-86502005000300002.
12. Cologna AJ, Silva Lima LV, Tucci Jr. S, Suaid HJ, Reis RB, Tirapelli LF, Rodrigues Jr AA, Martins ACP. Cyclosporine action on kidneys of rats submitted to normothermic ischaemia and reperfusion. *Acta Cir Bras.* 2008;23(Suppl 1):36-41. doi: 10.1590/S0102-86502008000700007.
13. Ochiai T, Nakajima K, Nagata M, Hori S, Asano T, Isono K. Studies of the induction and maintenance of long-term graft acceptance by treatment with FK506 in heterotopic cardiac allotransplantation in rats. *Transplantation.* 1987 Dec;44(6):734-8. PMID: 2447689.
14. Gonçalves-Filho A, Torres OJM, Campos ACL, Tambara-Filho R, Rocha LCA, Lunedo SMC, Barbosa REA, Bernhardt JA, Vasconcelos PRL. Efeito do extrato de *Passiflora edulis* (maracujá) na cicatrização de bexiga em ratos: estudo morfológico. *Acta Cir Bras.* 2006;21(Suppl. 2):3-8. doi: 10.1590/S0102-86502006000800001.
15. Simões MLPB, Collaço LM, Veronese C, Ribas MM, Flores SN. Behavior of chromed catgut and polyglycaprone 25 sutures in the urinary bladder of rats, with special reference to stone formation. *Acta Cir Bras.* 1998 Jan-Mar;13(1):26-9. doi: 10.1590/S0102-86501998000100004.
16. Fumagalli U, Trabucchi E, Soligo M, Rosati R, Rebuffat C, Tonelli C, Montorsi M. Effect of intraperitoneal chemotherapy on anastomotic healing in the rat. *J Surg Res.* 1991 Jan;50(1):82-7. doi: 10.1016/0022-4804(91)90014-D.
17. Myers AH, Postlethwait RW, Smith AG. Histologic grading of experimental healing wound. *Arch Surg.* 1961;83(5):771-4. doi: 10.1001/archsurg.1961.01300170127025.

Correspondence:

Rogério de Fraga
Rua Portugal, 329
80510-280 Curitiba – PR Brasil
Tels.: (55 41)3074-7497 / 3074-7474
rogeriodefraga@uol.com.br
rogeriodefraga@gmail.com

Received: Mar 10, 2014

Review: May 12, 2014

Accepted: Jun 11, 2014

Conflict of interest: none

Financial source: none

¹Reserch performed at Laboratory of Anatomy, Department of Surgery, Federal University of Parana (UFPR), Curitiba-PR, Brazil. Part of Master degree thesis, Postgraduate Program in Surgical Clinic, UFPR. Tutor: Rogério de Fraga.