

# 11 - Experimental model to study correction of rectus diastasis by laparoscopy, in pigs<sup>1</sup>

Fábio Xerfan Nahas<sup>2</sup>  
Lydia Masako Ferreira<sup>3</sup>

---

Nahas FX, Ferreira LM. Experimental model to study correction of rectus diastasis by laparoscopy, in pigs. *Acta Cir Bras* [serial online] 2003 Vol 18 Special Edition. Available on URL: <http://www.scielo.br/acb>.

**ABSTRACT** - The use of swines as an experimental model to correct rectus diastasis by laparoscopy is described on this article. The correction of this deformity was achieved by the plication of the posterior rectus sheath with the insertion of two trocars on the inferior abdominal fold. One trocar was placed in the midline whereas the other was inserted laterally to the right rectus muscle. A continuous suture was made on the posterior rectus sheath with 0-Polipropilene. This suture was anchored at the anterior rectus sheath under direct vision. An incision of all layers was performed on the flank and the abdominal wall was turned inside out so that the area of plication could be assessed and evaluated. The experimental model described showed to be feasible to demonstrate the correction of rectus diastasis by laparoscopy.

**KEY WORDS** Laparoscopy. Rectus distasis. Pigs.

---

## Introduction

Over the last decades plastic surgeons changed the way they treat cosmetic deformities. Instead of correcting only the excess skin, they recognized the deep layers as fundamental areas to be treated. The repositioning of muscles and fascias became routine in several cosmetic procedures, mainly in the correction of abdominal deformities.<sup>1,2,3,4,5</sup> The cosmetic result achieved was more natural and durable. Another important concept change is the possibility of skin retraction, widely demonstrated after the introduction of liposuction. Moreover, patients who present for a cosmetic consultation search for small incisions. Limited incision abdominoplasties<sup>6,7,8</sup>, known as mini-abdominoplasties, were the first step toward the reduction on the extension of the abdominal scars.

Plication of the posterior rectus sheath using laparoscopy associated with liposuction could provide correction of the mioaponeurotic layer and reduction of the subcutaneous tissue, therefore correcting abdominal deformities on selected patients.<sup>9,10,11</sup>

- 
1. Federal University of São Paulo - Paulista School of Medicine. UNIFESP-EPM. Brazil.
  2. Professor of Post-graduation Program in Reconstructive Plastic Surgery of UNIFESP-EPM. Brazil
  3. Head and Chairwoman of Plastic Surgery Division of Surgery Department and Coordinator of Post-graduation Program in Reconstructive Plastic Surgery - UNIFESP - EPM. Brazil.

## Proposition

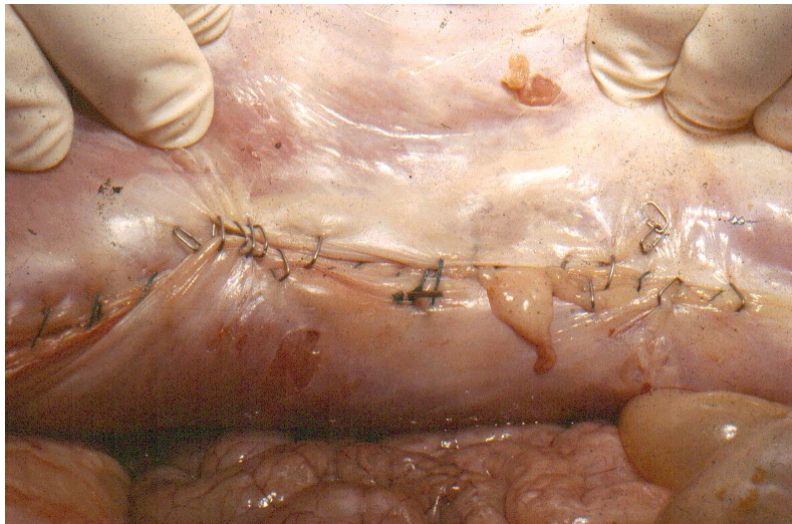
The purpose of this study is to report and bring to light the use of swines as an experimental model to evaluate the possibility of correction of rectus diastasis by laparoscopy.

## Method description

### *Pilot Study*

Different techniques of plication were used on the posterior rectus sheath to correct diastasis on three swines. An articulated stapler, that could rotate 60 degrees and could back up to the anterior abdominal wall, was used to perform the plication of the posterior sheath. This method was abandoned because of : A) The use of at least 4 ports (laparoscope, stapler, two forceps); B). The need of a third person in the surgical team who would put the edges of the aponeurosis together; C). The staples were not efficient in the plication because they were weak and not big enough, and their shape couldn't bear high pressure such as that of the abdominal muscles.

The use of interrupted stitches was also tried. Two techniques were used: A). the knot was tied inside the abdominal cavity; B). the knot was tied extra corporeally and guided to the inside. The main problem is that the knot gets loose even using different tying techniques (Figure 1).



**FIGURE 1** Plication of the posterior rectus sheath of a swine using staples and interrupted stitches. Please note the poor tension obtained on the plication when these techniques were used.

The technique showed to be efficient when a continuous suture was performed on an animal of the pilot study.

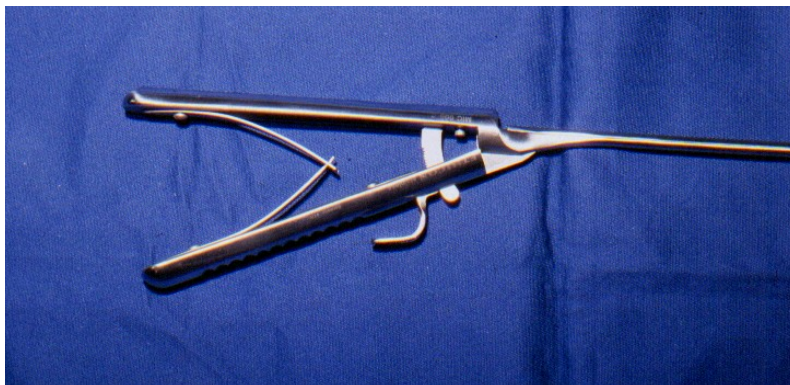
### *Methods*

Eight male adult swines were undergone laparoscopy for correction of rectus diastasis using continuous suture with 0-Polipropilene. A 10mm 45 degree Laparoscope (Olympus®), that makes possible the visualization

of the anterior abdominal wall (Figure 2), a curved laparoscopic scissors, and a Castroviejo needle holder (Ethicon®) - Figure 3 - were also used.



**FIGURE 2** Close view of the 10mm 45 degree Laparoscope.



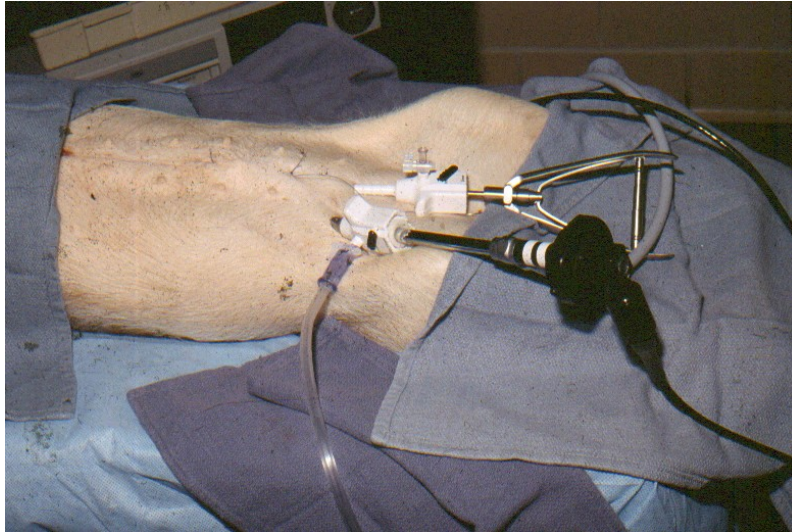
**FIGURE 3** View of the handle of the Castro-Viejo needle holder.

### *Surgical Technique*

The animal was placed in the lithotomy position. A urethral catheter was introduced to keep the bladder empty during the procedure. The surgeon was seated between the rear legs of the animal. The assistant who controls the scope should be on the left side of the surgeon.

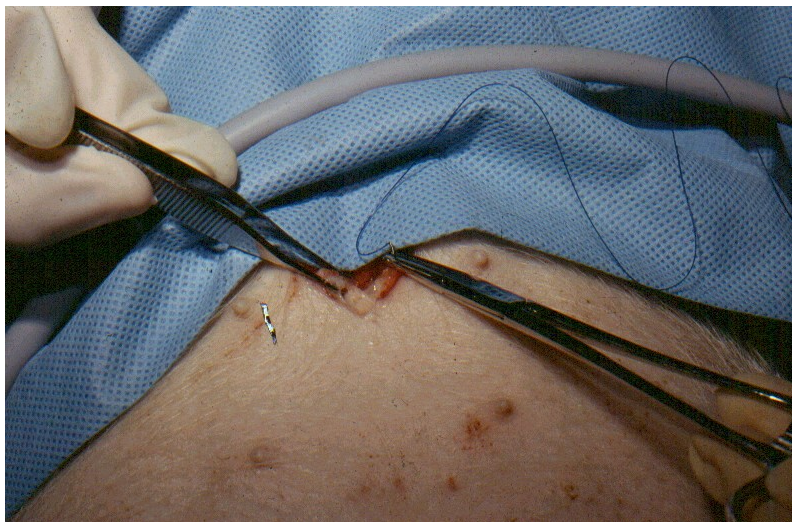After the insufflation of the peritoneal cavity, a 10 mm trocar is introduced in the median region, above the pubic region. Another trocar is introduced laterally to the right rectus abdominis muscle, under direct vision, in order to avoid injury to the epigastric vessels. A 10 mm 45 degrees laparoscope is inserted through the lateral trocar. After a careful evaluation of the abdominal cavity, curved scissors are introduced through the median trocar. They are used to cut and undermine the peritoneum. The whole median line of the peritoneum is incised, exposing the posterior rectus sheath. Graspers are used for hemostasia. At this moment the Castro-Viejo needle holder is inserted through the median trocar (Figure 4).





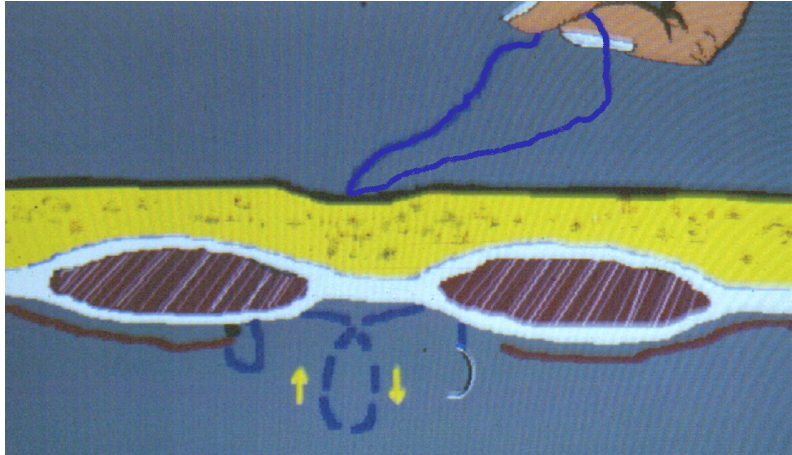
**FIGURE 4** Insertion of the trocars on the inferior abdominal fold, one on the midline and the other laterally to the lateral edge of the right rectus muscle. This allows the surgeon to be positioned between the lower limbs of the animal.

A stab incision is made in the midline, 2 cm below the xiphoid appendix. Dissection is performed down to the fascia. A stitch of 0-Propilene is made to anchor the suture line in the anterior rectus sheath (Figure 5). This is the beginning of the running suture. The needle is inserted through the linea alba to the inside of the abdominal cavity. This movement is made under endoscopic visualization. The needle is caught by the needle holder introduced through the median trocar. At this point, a continuous suture line is made in the posterior rectus sheath, correcting the diastasis.



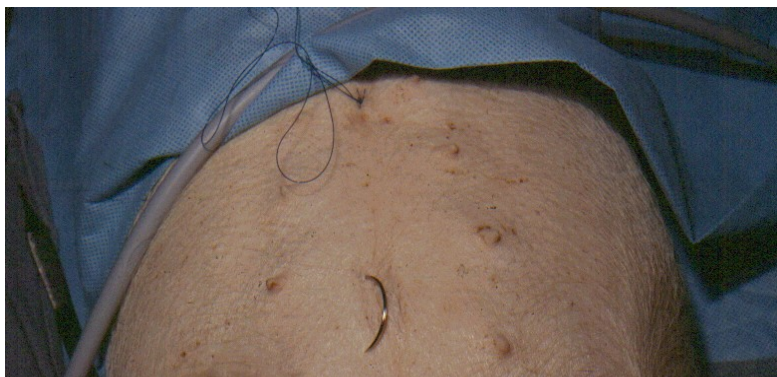**FIGURE 5** Through a 1 cm midline incision, close to the xiphoid, a stitch is anchored to the anterior rectus sheath. This is the beginning of the continuous suture.

In order to facilitate the technique, and perform it safely, the assistant pulls the excess length of the suture outside the abdominal cavity, forming a loop in the anchored stitch. Due to a gravitational factor, this maneuver will force the tip of the needle downwards, which is the ideal position for the next stitch. The surgeon should use one hand to control the needle holder and the other to feel the abdominal wall at the point where the next stitch will be made (Figure 6).



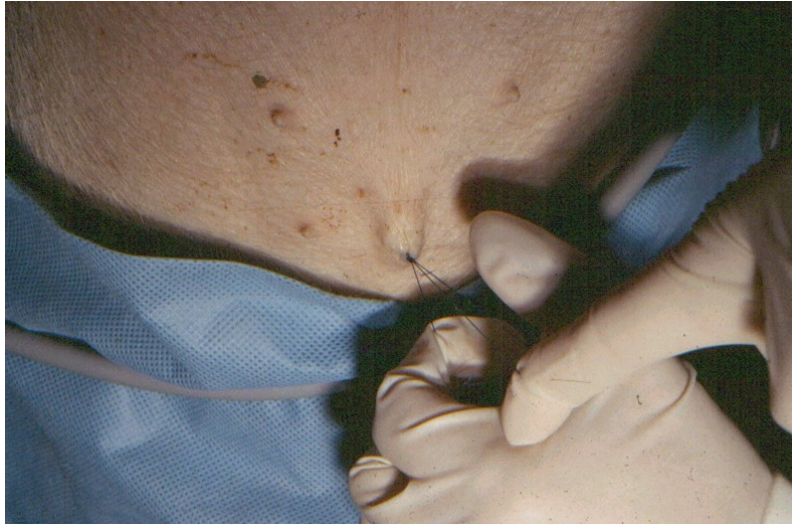
**FIGURE 6** The suture is inserted into the abdominal cavity. This diagram demonstrates the plication of the posterior rectus sheath. The needle should be passed first at the right posterior rectus sheath. The needle holder should be rotated clockwise on the surgeon's hand so that the needle will be ready to be inserted on the left posterior rectus sheath. The surgeon is also able to palpate the abdominal wall with the non dominant hand to feel the needle being inserted into the aponeurosis.

This suture continues until the umbilicus, where a cutaneous incision is made and the needle is passed through the linea alba (Figure 7). The suture is pulled and anchored to the anterior aponeurosis, pulling both edges of the rectus muscles to the midline. At the time of traction, the intraperitoneal gas pressure should be decreased (Figure 8).



**FIGURE 7** A 1 cm incision is made at the level of the umbilicus. The needle is passed through the linea alba to the exterior of the abdominal cavity.

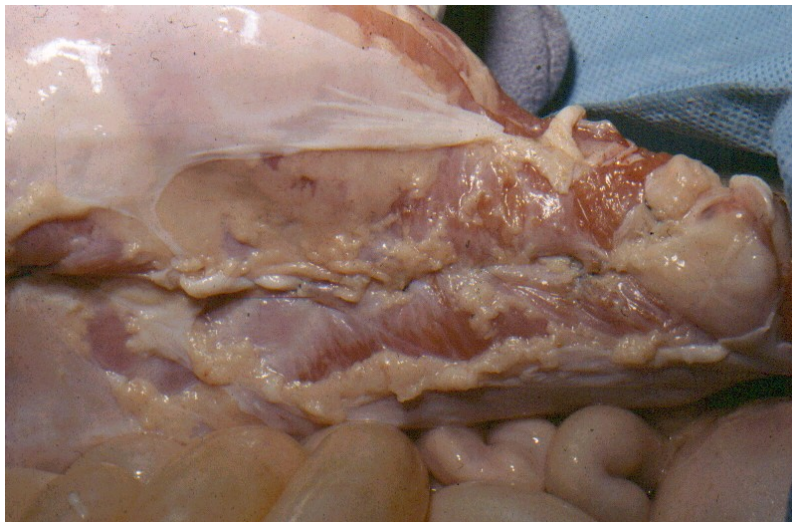




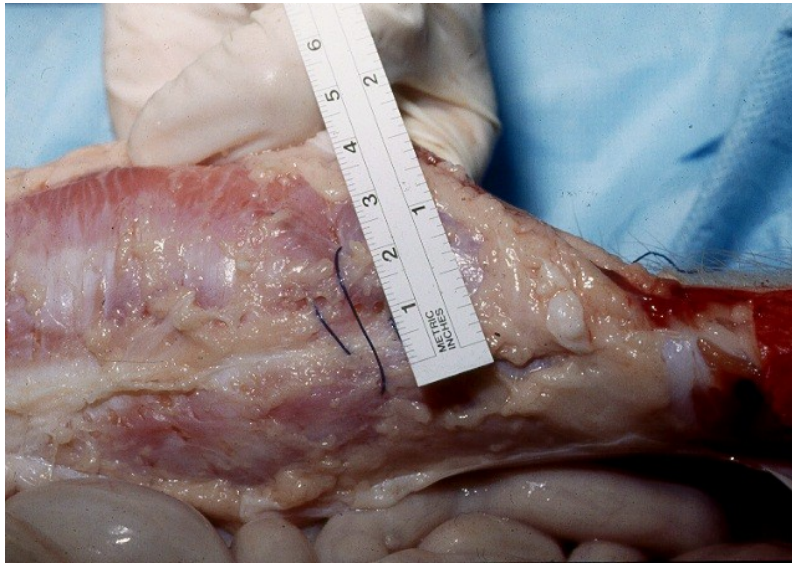
**FIGURE 8** The Polipropilene suture is tractioned and anchored to the anterior rectus sheath.

A new suture is performed in the lower abdomen, in the same manner, beginning at the umbilicus. This suture goes clockwise down to the arcuate line. A subcutaneous dissection over the anterior aponeurosis is made from the point of the insertion of the trocar until the level of the arcuate line. At this point the needle is passed through the fascia and the suture is continued clockwise, over the anterior aponeurosis, down to the skin incision. The suture is pulled and anchored to the anterior aponeurosis. Interrupted stitches as well as a second suture line may be performed as a safety measure.

After the surgical procedure, all layers of the abdominal wall were opened by an incision in the left flank (Figure 9). The edges of the plication were marked and the suture line was cut. By doing this, the area plicated was limited by the marks. Two distances were measured transversally to the marks, 3cm above and 3cm under the umbilicus (Figure 10).



**FIGURE 9** View of the anterior abdominal wall which had all layers incised on the flank and was turned inside out, showing an ample exposure of the plication of the posterior rectus sheath. Note the tight closure of the posterior sheath achieved by the plication.



**FIGURE 10** Measurement of the rectus diastasis after the release of the plication suture on the posterior rectus sheath.

### Perspectives

The experimental model described showed to be feasible to demonstrate the correction of rectus diastasis by the plication of the posterior rectus sheath. This model may be used on studies of correction of abdominal wall defects by laparoscopy and for the study of techniques of endoscopic plastic surgery.

### References

1. Pina DP. Aesthetic abdominal deformities: a personal approach to the posterior rectus sheath and rectus muscles. *Plast Reconstr Surg* 1985;75:660-7.
2. Psillakis JM. Plastic surgery of the abdomen with improvement in the body contour. Physiopatology and treatment of the aponeurotic musculature. *Clin Plast Surg* 1984;11:465-77.
3. Abramo AC, Viola JC, Marques A. The H approach to abdominal muscle aponeurosis for the improvement of body contour. *Plast Reconstr Surg* 1990;86:1008-13.
4. Nahas FX, Ferreira MC. Cirurgia reconstrutora da parede abdominal In: *Residente de Cirurgia*. São Paulo:Roca; 1992. p. 469-74.
5. Asaadi M, Haramis HT. A Simple Technique for Repair of Rectus Sheath Defects. *Ann Plast Surg* 1994;32:107-9.
6. Castro CC, Cupelo AMB, Cintra H. Limited incisions in abdominoplasty. *Ann Plast Surg* 1987;19: 436-47.
7. Greminger RF. The mini-abdominoplasty. *Plast Reconstr Surg* 1987;70:356-65.
8. Wilkinson TS. Limited Abdominoplasty Techniques Applied to Complete Abdominal Repair. *Aesthetic Plast Surg* 1994;18:49-55.
9. Nahas FX. Correção da Diastasi Recti por Laparoscopia. Descrição de uma nova Técnica Cirúrgica. In: Pinotti WP, Domene CE. *Cirurgia Vídeio-Laparoscópica*. São Paulo:Robe;1993. p. 331-44.
10. Nahas FX. Reconstrução da Parede Abdominal por Via Laparoscópica. *Arq Bras Cir Digest* 1993;8:132-3.
11. Nahas FX. Studies on the Endoscopic Correction of Diastasis Recti - *Oper Tech Plast Reconstr Surg* 1996; 3(1):58-616.

---

Nahas FX, Ferreira LM. Modelo experimental na correção de diástase de retos por laparoscopia. Acta Cir Bras [serial online] 2003 Vol 18 Edição Especial. Disponível em URL: <http://www.scielo.br/acb>.

**RESUMO** - O uso de suínos como modelo experimental para a correção de diástase de retos por laparoscopia é descrito no presente artigo. A correção desta deformidade foi obtida pela plicatura da aponeurose posterior dos retos pela inserção de dois trocares na prega abdominal inferior. Um trocar foi introduzido na linha média enquanto o outro foi inserido lateralmente ao músculo reto abdominal direito. Uma sutura contínua de polipropileno-0 foi realizada na aponeurose posterior. Esta sutura foi ancorada na aponeurose anterior do músculo reto sob visão direta. Uma incisão foi realizada em todos os planos na região do flanco e a parede abdominal foi evertida para visualização e avaliação da área onde fora realizada a plicatura na aponeurose anterior. O modelo experimental descrito mostrou-se factível em demonstrar a correção da diástase de retos por laparoscopia.

**DESCRITORES** - Laparoscopia. Diástase de reto. Porcos.

---

Conflict of interest: none  
Financial source: none

Correspondence:  
Fabio Xerfan Nahas  
UNIFESP-EPM, Plastic Surgery Division, Surgery Division  
Rua Napoleão de Barros, 715, 4º andar  
04024-900 São Paulo SP  
Tel: (11)557604118 FAX: (11) 55716579  
sandra.dcir@epm.br fabionahas@uol.com.br

Data do recebimento: 22/ 04/2003  
Data da revisão: 18/05/2003  
Data da aprovação: 28/07/2003