

Evaluation of optical density of bone defects filled with calcium phosphate cement and bioactive glass in rats¹

Avaliação da densidade óptica de cavidades ósseas preenchidas com cimento de fosfato de cálcio e vidro bioativo em ratos

Luiz Alberto Biancon Filho^I, Bruno Tochetto Primo^{II}, Humberto Thomazi Gassen^{II}, Vânia Regina Camargo Fontanella^{III}, Aurelício Novaes Silva Jr^{IV}

^I Research performed at the Animal Experimentation Unit, Research Center, Department of Veterinary Medicine, School of Veterinary Medicine, Lutheran University of Brazil (ULBRA), Canoas-RS, Brazil. *Part of the dissertation of the first author. Tutor: Aurelício Novaes Silva Jr; Postgraduate Program on Oral and Maxillofacial Surgery, School of Dentistry, ULBRA.*

^{II} Fellow Master degree, Department of Oral and Maxillofacial Surgery, School of Dentistry, ULBRA, Canoas-RS, Brazil. *Main author. Responsible for conception, design, intellectual and scientific content of the study.*

^{III} Fellow Master degree, Department of Oral and Maxillofacial Surgery, School of Dentistry, ULBRA, Canoas-RS, Brazil. *Surgical procedures. Manuscript writing.*

^{IV} PhD, Associate Professor, Department of Maxillofacial Radiology, School of Dentistry, ULBRA, Canoas-RS, Brazil. *Acquisition and interpretation of data. Critical revision.*

^V PhD, Associate Professor, Department of Oral and Maxillofacial Surgery, School of Dentistry, ULBRA, Canoas-RS, Brazil. *Tutor. Responsible for conception and critical revision of the study.*

ABSTRACT

Purpose: To evaluate new bone formation, by the analysis of optical density, in rat femoral defects filled with calcium phosphate cement (CPC) and bioactive glass (BG). **Methods:** Twenty-one rats were divided into three groups, Group I (CPC), Group II (BG), and Group III (control), and assessed after 7, 15, and 30 days. Three bone cavities were made in the left femur and filled with CPC, BG, and no material (control). Digital images were obtained and the results were subjected to statistical analysis of variance (ANOVA), complemented by the Friedman and Kruskal-Wallis nonparametric tests, with a significance level of 5%. **Results:** Regarding optical density, Group I showed statistical values significantly higher than Group III and also higher, although not statistically significant, than Group II, in all observation periods. When Groups II and III were compared, Group II showed higher optical density values, without statistically significant differences, in all periods. **Conclusion:** The biomaterials analyzed showed higher optical density in relation to the control group in all observation periods, calcium phosphate cement being the best option in the repair of bone defects, but without statistically significant differences in relation to bioactive glass.

Key words: Bone Substitutes. Biocompatible Materials. Bone Transplantation. Bone Regeneration. Rats.

RESUMO

Objetivo: Avaliar a neoformação óssea, por meio da análise de densidade óptica, em cavidades em ratos preenchidas com cimento de fosfato de cálcio (CFC) e vidro bioativo (VB). **Métodos:** Utilizou-se 21 ratos distribuídos em três grupos, sendo Grupo I (CFC), Grupo II (VB) e Grupo III (controle) avaliados em 07, 15 e 30 dias. Foram realizadas três cavidades, junto ao fêmur esquerdo e preenchidas com CFC, VB e sem material (controle). Realizaram-se radiografias digitais e os resultados foram submetidos à análise estatística de variância (ANOVA), complementada através dos testes não-paramétricos de Friedman e Kruskal-Wallis, com níveis de significância de 5%. **Resultados:** Comparando a densidade óptica o Grupo I apresentou valores estatísticos significativamente maiores que o Grupo III, e também apresenta valores maiores, sem diferença estatística significativa, em todos os períodos, quando comparado ao Grupo II. Quando comparamos o Grupo II com o Grupo III, o Grupo II apresenta valores maiores de densidade óptica, sem diferença estatística significativa, em todos os períodos. **Conclusão:** Observou-se maior densidade óptica dos biomateriais em relação ao grupo controle em todos os períodos avaliados, sendo o cimento de fosfato de cálcio a melhor opção para restauração de cavidades ósseas, porém sem diferenças estatisticamente significantes em relação ao vidro bioativo.

Descritores: Substitutos Ósseos. Materiais Biocompatíveis. Transplante Ósseo. Regeneração Óssea. Ratos.

Introduction

The search for an ideal material that enables tissue repair has become the predominant issue for researchers and surgeons interested in the acceleration of fracture healing or reconstruction of bone defects. The study and development of biomaterials have improved the characteristics and properties of synthetic bone graft substitutes. Of these, calcium phosphate cement (CPC) lists the properties of biocompatibility, bioactivity¹ and osteoconductivity, in addition to easy handling and molding that enable optimal adaptation to the bone defect to be repaired. Bioactive glasses (BG) are silicon-based bone graft substitutes that, in addition to osteoinductive and osteoconductive properties, have pro-angiogenic potential as a result of factors generated by products of its dissolution² and great ability to bond to bone and soft tissue³.

Biomaterials that can substitute bone structures are the current choice in reconstruction, since they prevent patient complications from a possible autogenous donor site, such as inflammation, stiffness, pain, and bacterial infection⁴.

Taking these data together, the objective of this study was to evaluate new bone formation in rat femoral defects filled with CPC and BG by the analysis of optical density.

Methods

The study protocol was analyzed and approved by the Research Ethics and Animal Care and Use Committees of Lutheran University of Brazil (ULBRA). The use of laboratory animals followed the ethical code for animal experimentation of the Council for International Organization of Medical Sciences and the Brazilian College on Animal Experimentation.

Twenty-one clinically healthy, young adult, male albino Wistar rats (*Norvegicus albinus*), at approximately 180 days of age and mean weight of 300g at surgery, were selected for this study.

The CPC (Laboratory of Biomaterials, Federal University of Rio Grande do Sul, Porto Alegre-RS, Brazil) used in the present study was composed of 85% -tricalcium phosphate (-TCP) and 15% calcium sulfate, mixed with an aqueous solution containing 2.5% Na₂HPO₄ (accelerator). This cement has a dual-setting hydraulic system. The initial setting is obtained by the hydration reaction of calcium sulfate ($\text{CaSO}_4 \cdot \frac{1}{2}\text{H}_2\text{O} + \text{H}_2\text{O} \rightarrow \text{CaSO}_4 \cdot 2\text{H}_2\text{O}$) and the final setting is obtained by the hydration reaction of -TCP ($\text{Ca}_3(\text{PO}_4)_2 + \text{H}_2\text{O} \rightarrow \text{Ca}_9(\text{HPO}_4)(\text{PO}_4)5\text{OH}$). The BG (3i Innovations, São Paulo, SP, Brazil) used in this study had granules of a narrow size range (300-355 µm).

For experimental standardization, the animals were divided into 3 groups of 7 animals each. Three bone cavities were made in the left femur of each rat, proximal to the coxofemoral joint: the first cavity, located in the uppermost region of the femur, was filled with CPC; the second cavity was filled with BG; and the third cavity, located in the lowest region of the femur, was the control bone defect (control group, CG) and received no graft material. Each group was then randomly divided into three observation time points: 7, 15, and 30 days after grafting. The groups were distributed as follows (Table 1):

TABLE 1 - Distribution of groups in the respective observation time points according to type of material

	Radiographic assessment		
	7 days	15 days	30 days
1. CPC	CPC (07)*	CPC (07)	CPC (07)
2. BG	BG (07)	BG (07)	BG (07)
3. Control	CG (07)	CG (07)	CG (07)

BG = bioactive glass; CG = control group; CPC = calcium phosphate cement
*Number of animals

Initially, the animals were anesthetized with 20 mg/kg tiletamine-zolazepam combined (0.4 mL/kg) (Zoletil 50, Virbac, São Paulo, Brasil) intramuscularly, supplemented with half the dosage, if necessary (0.2 mL/kg).

Trichotomy was then performed in the coxofemoral joint region, followed by antisepsis of the region with 2% alcohol-based iodophor. Surgical access to the left femur was established by means of an incision of approximately 2.0 cm through the skin and subcutaneous tissue, with tissue tearing over the muscle and periosteum layers, in the upper left medial region, allowing direct access to the exposed surface of the femoral shaft.

A titanium surgical guide was manufactured in order to standardize the perforations, which were equally spaced. Bone perforations were made using a 3.8-mm diameter trephine drill (Promm®, Porto Alegre-RS, Brazil), to create a “critical size defect” and prevent postoperative femoral fractures, according to previous studies⁵ and an electric motor (Driller BLM600®, Sao Paulo-SP, Brazil) coupled with a handpiece (KAVO®, Biberach, Germany). The depth of the created defects was determined by the rupture of the cortical bone marrow.

The first perforation was made in the lateral surface of the left femur, proximal to the coxofemoral joint. The second and third perforations were made following the surgical guide and the same procedures employed to produce the first bone defect (Figure 1).

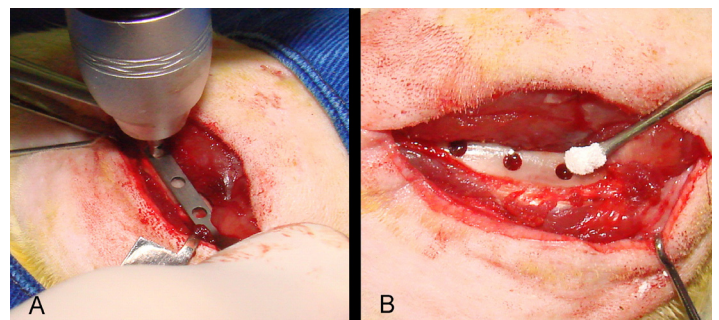


FIGURE 1 – (A) Positioning the trephine drill guided by the surgical guide. (B) Image illustrating the moment of calcium phosphate cement insertion into the produced cavity.

Suture was performed in layers using absorbable suture material (Vicryl 4.0 - Ethicon, Johnson & Johnson, USA).

After the surgical procedure, the animals received 40,000 IU/kg benzathine penicillin G (single dose) intramuscularly as

antibiotic coverage. Topical Terramycin eye ointment (Pfizer, USA) and larvicide spray (Lepecid, Dow Quimica Industrial Ltda, Sao Paulo, Brazil) were applied on the suture for 10 days as an antiseptic measure on the site of the surgical wound. Each animal received oral analgesia (paracetamol drops), at a maximum daily dose of 200 mg/kg.

For the acquisition of individual digital radiographs, the animals, previously sedated, were secured in a standard position on a flat acrylic platform. A rod guided the position of the cone of the X-ray machine to standardize the incidence of the central ray perpendicular to the horizontal plane, with 20-cm focal length. The place of the radiographic sensor was also established on the platform so that this position remained the same for all the necessary radiographic scans.

Digital radiographs were obtained using a direct digital CCD system (Cygnus Ray MPS; Progeny, Buffalo Grove, IL, USA), a Gnatus 70X apparatus (Gnatus Equipamentos Medico-Odontologicos Ltda, Ribeirao Preto-SP, Brazil) operating at 70 kVp and 10 mA, 20-cm focal length, and 0.25-second exposure time (Figure 2).

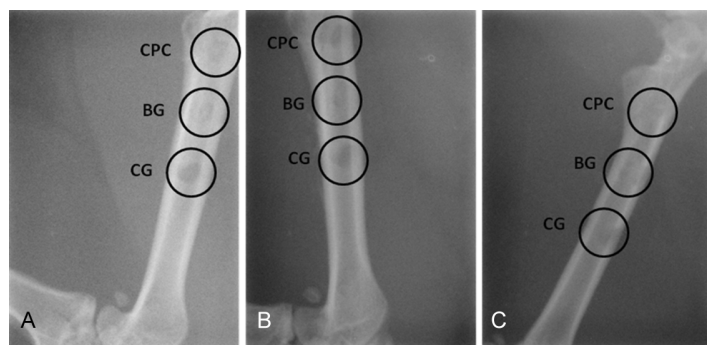


FIGURE 2 - (A) Digital radiographic image of the rat left femur 7 days after grafting. **(B)** Digital radiographic image of the rat left femur 15 days after grafting. **(C)** Digital radiographic image of the rat left femur 30 days after grafting. Calcium phosphate cement (CPC), bioactive glass (BG) and no material (control group CG).

To obtain optical density values, the images were imported into Adobe Photoshop v.6.0 (Adobe Systems, San Jose, CA, USA), in which, using the histogram command, we obtained density mean values and standard deviation of areas corresponding to graft materials and control defects, as well as an unchanged area of normal bone tissue, which served as a parameter for calculating the difference in optical density. To obtain optical density values from the exact site where femoral bone cavities were made, a digital mask was designed based on the scanned image of the surgical guide used in the creation of bone defects during the surgical technique. The difference between each area of unchanged bone tissue and each test area in the same femur was then calculated. Positive values represented gain and negative values expressed loss of optical density in the radiographic images. The digital radiographs revealed femoral fracture in 2 animals of the 30-day group and in 1 animal of the 7-day group. The results were stored in an Excel database for Windows (Microsoft Corporation, Redmond, WA, USA) and then subjected to statistical analysis of variance (ANOVA) using the Friedman and Kruskal-Wallis nonparametric tests, with a significance level of 5%.

Results

Analysis of optical density between groups

A comparative analysis of the biomaterials grafted into the rat femurs (CPC and BG) and GC (without material) was performed between groups 7, 15, and 30 days after grafting.

According to the Friedman nonparametric test, complemented by its multiple comparison test, at a significance level of 5%, Group I (CPC) showed significantly higher optical density values than Group III (control) in all observation periods. Group I also had higher optical density values, although not statistically significant, than Group II (BG), in all observation periods. When Groups II and III were compared, Group II showed higher optical density values, without statistically significant difference, in all observation periods (Table 2).

TABLE 2 - Comparison between groups (comparison of lines)

Time point		Group I	Group II	Group III	p
7 days	Median	-1.80	-5.26	-10.03	0.002
	(P25 ; P75)	(-2.35 ; -1.57)	(-5.54 ; -5.09)	(-10.58 ; -9.73)	
	Mean rank	3.00 ^A	2.00 ^{AB}	1.00 ^B	
15 days	Median	7.11	4.53	-8.48	0.001
	(P25 ; P75)	(6.73 ; 7.59)	(4.25 ; 4.75)	(-9.86 ; -7.12)	
	Mean rank	3.00 ^A	2.00 ^{AB}	1.00 ^B	
30 days	Median	12.16	9.85	-0.87	0.007
	(P25 ; P75)	(11.56 ; 12.39)	(9.53 ; 9.94)	(-1.57 ; -0.76)	
	Mean rank	3.00 ^A	2.00 ^{AB}	1.00 ^B	

Group I: calcium phosphate cement; Group II: bioactive glass; Group III: without material (control group).

p = minimum level of significance of the Friedman nonparametric test. Mean ranks followed by different letters differ significantly by the Friedman nonparametric test, complemented by its multiple comparison test, with a significance level of 5%.

Analysis of optical density within groups

AN analysis of the biomaterials grafted into the rat femurs (CPC and BG) and GC (without material) was performed within groups 7, 15, and 30 days after grafting.

According to the Kruskal-Wallis nonparametric test,

complemented by its multiple comparison test, at a significance level of 5%, differences in optical density for Groups I and II were significantly lower at day 7 than after 15 and 30 days. In Group III, the difference at day 7 did not differ significantly from that at day 15, and both were significantly lower than that observed 30 days after grafting (Table 3).

TABLE 3 - Comparison between observation time points (comparison of columns)

Time point		Group I	Group II	Group III	p
7 days	Median	-1.80	-5.26	-10.03	0.001
	(P25 ; P75)	(-2.35 ; -1.57)	(-5.54 ; -5.09)	(-10.58 ; -9.73)	
	Mean rank	3.50 ^B	3.50 ^B	4.33 ^B	
15 days	Median	7.11	4.53	-8.48	0.001
	(P25 ; P75)	(6.73 ; 7.59)	(4.25 ; 4.75)	(-9.86 ; -7.12)	
	Mean rank	10.00 ^A	10.00 ^A	9.29 ^B	
30 days	Median	12.16	9.85	-0.87	0.007
	(P25 ; P75)	(11.56 ; 12.39)	(9.53 ; 9.94)	(-1.57 ; -0.76)	
	Mean rank	16.00 ^A	16.00 ^A	16.00 ^A	

Group I: calcium phosphate cement; Group II: bioactive glass; Group III: without material (control group).

p = minimum level of significance of the Kruskal-Wallis nonparametric test. Mean ranks followed by different letters differ significantly by the Friedman nonparametric test, complemented by its multiple comparison test, with a significance level of 5%.

Discussion

The results obtained reveal a consistently higher optical density of biomaterials in relation to the control group in all observation periods, indicating CPC as the best option in the repair of bone defects when compared to the control group.

The values observed at day 7 suggest that the mere presence of particles of these products filling the cavities already yields higher density values in relation to the natural process of bone regeneration, as reported by Välimäki *et al.*⁶ and Sanzana *et al.*⁷ This phenomenon demonstrates the important role that the biomaterials studied play as scaffolds for bone healing and new bone formation, since they are replaced with bone tissue over time, through a phenomenon known as osteotransduction⁸. At the same time, they promote faster bone regeneration due to their osteoconductive and osteoinductive properties³, through which the biomaterials seemed to induce the process of bone repair and new bone formation earlier than in the control group.

CPC arises as one of the most promising biomaterials, because it is well tolerated by the body and does not present chronic inflammatory response, toxic reactions, or foreign body reactions; in addition, it establishes a solid union with adjacent bone, with subsequent replacement with mature bone³. However, CPC requires a careful application technique, since, if the material is not inserted appropriately into the bone defect or if contamination by fluids occurs in the postoperative period, CPC may dissociate into small particles triggering an inflammatory reaction⁴. In the present study, the biomaterials showed uniform radiopacity in the cavities during the observation periods, demonstrating good handling, insertion, and stability of materials. Thus, we believe that the biomaterials met the characteristics required of an ideal material which include unlimited availability and filling ability.

Clinical applications of BG in dentistry have become a common practice, since BG belongs to a group of biomaterials that are biocompatible and osteopromotive, which favor osteoblast proliferation and differentiation⁶. Moreover, BG has shown surface osteopromotive and osteoconductive ability, biocompatibility for bone migration, and a bioactive surface colonized by free osteogenic cells in the surgical wound⁹.

When analyzing the results from the within-group analysis, throughout the observation periods, the control group showed increasing values of optical density. After 30 days, optical density values were significantly higher than those observed at day 7 and 15, suggesting that a proper process of new bone formation occurred inside these cavities. According to Schenk *et al.*¹⁰, new bone formation within these defects begins in 2 days and, after 4 weeks, small or large defects (0.1 to 5.0 mm) are filled with compact bone. However, the process still depends on the defect size, and complete remodeling may persist for weeks or even some months. In the three observation periods analyzed, there was no significant difference between the two biomaterials, but CPC always showed higher optical density values.

The experimental model used is justified, since there are no non-animal alternatives, in agreement with the current concepts of bioethics, verifying this type of study in the literature. The choice of rat femoral bone tissue as the defect site in the present study was based on technical rationale, such as easy handling, compatible bone structure, and functional resistance¹¹. Both test and control defects were made in the rat left femur to maintain as much as possible the same variables for all groups. Repair of bone defects is a good model to study bone regeneration, being also very similar to the direct or primary repair of fractures. During

radiographic assessment, femoral fracture was detected in some animals, reducing the sample size. We believe that not filling the control defect may have acted as an adjuvant factor in the etiology of these fractures.

Although histological evaluation is considered the gold standard for assessing bone growth inside bone cavities and defects, this technique has some limitations. An important limitation is the fact that the histological section represents a specific area of the defect site, not the entire defect, thus excluding diversity in the sections and hindering comparison of the results. Bone growth inside cavities may exhibit an irregular pattern, and histological analysis using sections from the center might not represent bone growth in other regions¹².

Digital imaging systems have been widely used in Dental Radiology, which, in view of the few studies evaluating radiopacity of these biomaterials in the early stages of bone regeneration, motivated the development of this research. Furthermore, these systems show similar patterns when expressing variation in relation to the thickness of the material evaluated¹³. They can be used not only as a tool for assessing cases of fractures, but also to evaluate procedures that involve bone repair and regeneration¹⁴, meeting the objective proposed in the present study. The acquisition of digital radiographs with animals secured on a radiographic platform, as described in the methods, enabled us to obtain standardized, good quality radiographs¹⁵.

Conclusion

Calcium phosphate cement was the best option for restoration of bone defects when compared to the control group. In relation to bioactive glass, calcium phosphate cement showed better results, although without statistically significant differences.

References

1. Habraken WJEM, De Jonge LT, Wolke JGC, Yubao L, Mikos AG, Jansen JA. Introduction of gelatin microspheres into an injectable calcium phosphate cement. *J Biomed Mater Res A*. 2008;87:643-55.
2. Leu A, Stieger SM, Dayton P, Ferrara KW, Leach JK. Angiogenic response to bioactive glass promotes bone healing in an irradiated calvarial defect. *Tissue Eng Part A*. 2009;15:877-85.
3. Macedo NL, Matuda FS, Macedo LS, Gonzalez MB, Ouchi SM, Carvalho YR. Bone defect regeneration with bioactive glass implantation in rats. *J Appl Oral Sci*. 2004;12:137-43.
4. Moghadam HG, Sándor GK, Holmes HH, Clokie CM. Histomorphometric evaluation of bone regeneration using allogeneic and alloplastic bone substitutes. *J Oral Maxillofac Surg*. 2004;62:202-13.
5. Le Guehennec L, Goyenvalle E, Aguado E, Houchmand-Cuny M, Enkel B, Pilet P, Daculsi G, Layrolle P. Small-animal models for testing macroporous ceramic bone substitutes. *J Biomed Mater Res B Appl Biomater*. 2005;72(1):69-78.
6. Välimäki VV, Moritz N, Yrjans J, Dalastra M, Aro HT. Peripheral quantitative computed tomography in evaluation of bioactive glass incorporation with bone. *Biomaterials*. 2005;26:6693-703.
7. Sanzana ES, Navarro M, Macule F, Suso S, Planell JA, Ginebra MP. Of the in vivo behavior of calcium phosphate cements and glasses as bone substitutes. *Acta Biomater*. 2008;4:1924-33.
8. Välimäki VV, Aro HT. Molecular basis for action of bioactive glasses as bone graft substitute. *Scand J Surg*. 2006;95:95-102.
9. Schepers E, de Clercq M, Ducheyne P, Kempeneers R. Bioactive glass particulate material as a filler for bone lesions. *J Oral Rehabil*. 1991;18:439-52.
10. Schenk RK, Buser D, Hardwick WR, Dahlin C. Healing pattern of bone regeneration in membrane-protected defects: a histologic study in the canine mandible. *Int J Oral Maxillofac Implants*. 1994;9:13-29.
11. Yuan H, Li Y, de Bruijn JD, de Groot K, Zhang X. Tissue responses of calcium phosphate cement: a study in dogs. *Biomaterials*. 2000;21:1283-90.
12. Schortinghuis J, Ruben JL, Meijer HJA, Bronkers AJ, Raghoobar GM, Stegenga B. Microradiography to evaluate bone growth into a rat mandibular defect. *Arch Oral Biol*. 2003;48:155-60.
13. Farman AG, Farman TT. A comparison of 18 different x-ray detectors currently used in dentistry. *Oral Surg Oral Med Oral Pathol Oral Radiol Endod*. 2005;99:485-9.
14. Bozzo RO; Rocha RG; Haiter Neto F; Paganini GA; Cavalcanti MGP. Linear density analysis of bone repair in rats using digital direct radiograph. *J Appl Oral Sci*. 2004;12:317-21.
15. Mahl CRW, Fontanella V. Evaluation by digital subtraction radiography of induced changes in the bone density of the female rat mandible. *Dentomaxillofac Radiol*. 2008;37:438-44.

Conflict of interest: none
Financial source: none

Correspondence:

Dr. Aurelício Novaes Silva Júnior
Universidade Luterana do Brasil
Faculdade de Odontologia - Depto. Pós-Graduação
Rua Farroupilha, 8001/Prédio 59
92425-900 Canoas – RS Brasil
Phone/Fax: (55 51)9229-8277
aurelicio.junior@uol.com.br

Received: July 14, 2010
Review: September 20, 2010
Accepted: October 19, 2010