

A new proposal to evaluate the healing of open skin wounds. Volumetry¹

Nova proposta para avaliar cicatrização de ferida cutânea aberta. Volumetria

Danilo Nagib Salomão Paulo¹, Antonio Wilson Fiorot^{II}

¹Full Professor, Department of Surgery, EMESCAM, Vitoria-ES, Brazil. Tutor. Responsible for intellectual, scientific content and statistical analysis of the study.

^{II}MD, Fellow Master degree, Postgraduate Program in Public Politics and Local Development, School of Sciences, Santa Casa de Vitoria, ES, Brazil. Involved with technical procedures and manuscript writing.

ABSTRACT

PURPOSE: To present a new proposal to evaluate the healing of an open subcutaneous and skin wound, which we termed “volumetry”.

METHODS: A total of 32 circular wounds were performed in the subcutaneous tissues and skin of four feet of pigs (8 each). Each wound had about 1 cm in diameter and was 0.2 cm deep. Volume was calculated from the wound filled with saline and mass Xantopren. With the aid of a magnifying glass and local lighting, the liquid was dripped with a micropipette inside the wound until complete fullness. Volume repletion was calculated in microliters, corresponding to the volume of the wound. The mass of Xantopren was placed inside the wound to obtain a mold of the lesion. Mold volume was calculated using the formula of the volume of a cylinder closest resembling a geometric figure with mold.

RESULTS: The calculation of wound volume was possible with both Xantopren and mold techniques. Volume as calculated by micropipette was 119.37 ± 30.87 microliters while the volume calculated by mold was 122.41 ± 33.90 mm³ (p=0.79).

CONCLUSIONS: Volumetry in pig feet is simple and reproducible. Volumetry performed with saline did not differ from the volumetry with mass Xantopren. This method may be a useful tool to help evaluate the healing of open skin wounds in experimental and clinical research.

Keywords: Wound Healing. Skin. Swine.

RESUMO

OBJETIVO: Apresentar nova proposta para avaliar a cicatrização de uma ferida cutânea aberta, denominada “volumetria.”

MÉTODOS: Foram provocadas 32 feridas circulares cutâneas, com cerca de 1 cm de diâmetro e 0.2 cm de profundidade, em quatro patas de suíno. O volume da ferida foi calculado com solução salina e massa de xantopren. O líquido foi gotejado com uma micropipeta no interior da ferida até sua completa repleção, o que foi auxiliado com uma lupa de aumento e iluminação local. O volume de repleção foi calculado em microlitros e correspondeu ao volume da ferida. A massa de xantopren foi colocada no interior da ferida para se obter um molde da lesão. O volume do molde foi calculado utilizando-se a fórmula do volume de um cilindro que foi a figura geométrica mais parecida com o molde.

RESULTADOS: O cálculo do volume da ferida foi possível com as duas técnicas propostas. O volume calculado pela micropipeta foi 119.37 ± 30.8693 microlitros e o volume calculado pelo molde foi 122.4088 ± 33.8997 mm³ (p=0.79).

CONCLUSÕES: A volumetria realizada em patas de suíno é um método simples, reproduzível. A volumetria realizada com líquido não diferiu da volumetria realizada com massa de Xantopren. Esse método poderá ser útil para auxiliar na análise da cicatrização da ferida cutânea aberta em trabalhos clínicos e experimentais.

Descritores: Cicatrização. Pele. Suínos.

Introduction

The healing of an open skin wound can be evaluated subjectively and objectively. In subjective evaluation, the evaluator simply observes the course of healing, as the closing of the wound determines whether the injury is well healing. Objective evaluation, on the other hand, has been performed using several techniques: 1 - Microscopy (leukocytes, fibroblasts and collagen fibers), cytokines (TNF, IL-1b, IL-6)¹; 2 - histomorphometry^{2,3}; 3 - digital planimetry, immuno-histochemistry (myofibroblasts)⁴; 4 - histology of the inflammatory reaction and expression of collagen types I and III⁵; 5 - Photography, digital planimetry and histology (vascular proliferation, mononuclear cells, polymorphonuclear cells, fibroblast proliferation, collagen deposition, reepithelialization)⁶; 7 - Planimetry, qualitative and quantitative histological analysis⁷; 8 - Planimetry digital and degree of reparation and average of reparation⁸; 9 - Macroscopy, digital planimetry and histology⁹⁻¹². A combination of techniques, therefore, is used to objectively assess the healing of an open wound. However, it should be noted that healing involves a decrease in the open wound volume, since the wound closes from the periphery to the center and from the depth to the surface. As such, evaluation of volume may be an important tool for the objective assessment of open wound healing. However, calculation of wound volume has not previously been described. For this reason, we carried out a study to present a simple, reproducible technique, "volumetry", to evaluate the healing of open skin wounds and compare the two techniques we used: volumetry with saline and volumetry with mass Xantopren®.

Methods

The study was undertaken at the laboratory level. We used four adult pigs, obtained from a butcher shop working under the guidelines of the National Health Protection Agency. Eight circular wounds were produced in each foot (a total of 32), relevant skin and subcutaneous tissue. Each lesion had about one cm in diameter and was 0.2 cm deep. The wound was inflicted with the aid of a round metal mould with a 1 cm inner diameter, which allowed the surgical pen to mark a circle of about 1cm in diameter on the skin of the pig foot. The circle was incised with a scalpel to remove skin, subcutaneous to the deeper muscular plane. Then the fragment with skin and subcutaneous tissue was removed and the wound thus obtained was similar to a cylinder. Two techniques were used to perform wound volume measurement: the first, using micropipettes and the second using Xantopren® a dental product widely used by dentists in making molds of teeth for future

prosthesis

In the first method, a drip of a 0.9% saline solution was inserted into the wound with three micropipettes (Digipet variable): 1 - (pipette capable of measuring from 0.1 to 10 microliters), 2 - Pipette capable of measuring from 10 to 100 microliters 3 - pipette capable of measuring from 100 to 1000 microliters. The pipettes had disposable tips. A magnifying glass with spot lighting brand, model 55120, and with a focus on local illumination were used to observe the filling of the wound to the ceiling (Figure 1). The volume of the content that dripped fluid until the lesion was fully filled was regarded as the wound volume in microliters.

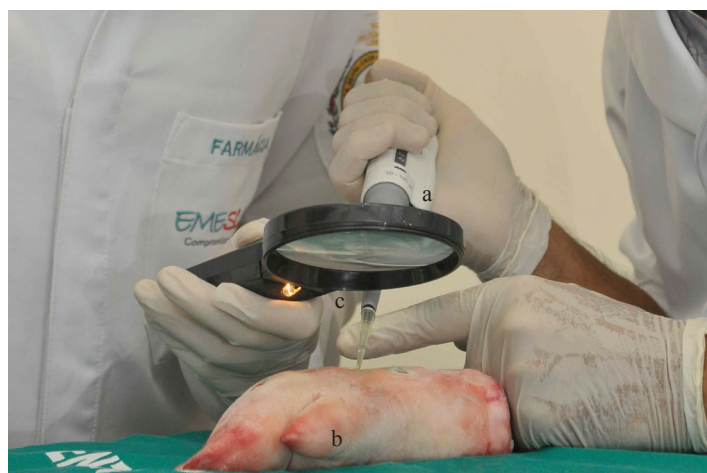

FIGURE 1 - Technical aspects of volumetry by micropipette (a) used for dripping saline within the foot wound (b) to calculate the volume of the lesion. A magnifying glass and a focused illumination (c) served to assess the filling of the lesion and hence its volume.

For the second method, using Xantopren®, the product is prepared as follows: Mixing a light weight low viscosity, VL Xantopren® plus (Heraeus Kulzer South America Ltda, Germany) with an equal proportion of a universal activator for Optosil® and Xantopren®. The mass produced by the mixture is placed inside the wound seeking to occupy the entire volume of the lesion. After about 5 minutes, the mold is removed for analysis of the part which corresponds to the volume of the lesion (Figure 2).

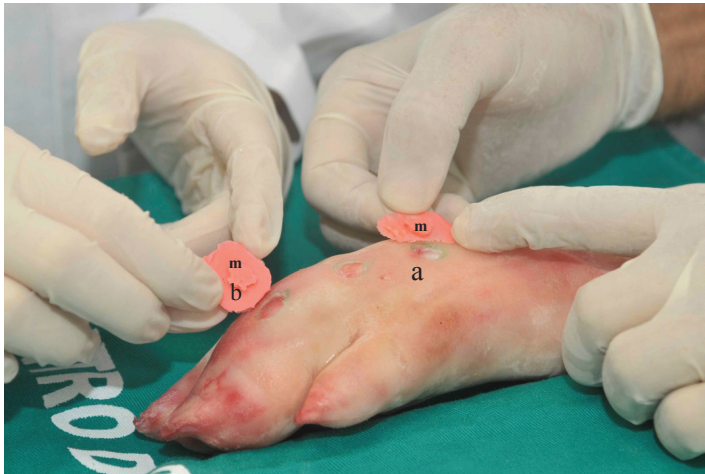


FIGURE 2 – Technical aspects of volumetry of the foot wound (a) with the mould of Xantopren®. The product is placed inside the wound until complete drying, which takes about 5 minutes. The material is then removed (b), and the most salient is the mold (m) which corresponds to the volume of the wound.

The geometric figure that appears in the mold is a cylinder-shaped base ellipse. The cylinder volume was calculated according to the formula: v (volume) = base area x height. As the area of the base of the cylinder looks like an ellipse, the area was calculated using the formula: $\text{base area} = \pi \times \text{DM} \times \text{dm} / 4$, where DM is the maximum diameter, and dm the minimum diameter. The height of the mold was calculated as follows: a horizontal line was drawn in the highest amplitude of the mould together with a line perpendicular to that, resulting in the formation of a cross and four quadrants (Figure 3). The following four measurements were made in each quadrant (a total of 16 measurements) of the height (thickness) of the mold with a stainless steel digital pachymeter (resolution: 0.01 mm, REF.N ° 205509, JOMARCA®, Brazil).

Measurements were made in a counterclockwise direction from a starting point corresponding to the cardinal point north. Then we calculated the average height that was used to measure the volume using the formula earlier described. It should be stressed that for each wound we used the technique of micropipette and the mould. For the selection of the initial technique a 1:1 randomization was used, as follows: 32 were written numbers (16 number one and 16 number two) in a paper with 2 cm 2 and each was placed in an opaque, sealed, stamped envelope signed by the two researchers. Before volume was established, a lay volunteer was asked to open the box, the envelopes and confer a number of them withdrew after breaking the seal. Thus if number one was drawn, the technique of volume was regarded as micropipette; otherwise/after this, it would be regarded as a mould technique. If

the number 2 was removed, the technique was the initial volume of the mould, followed by micropipette.

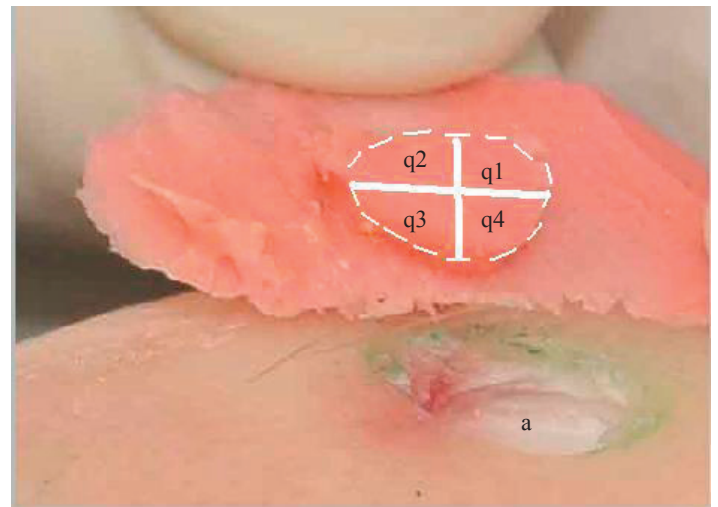


FIGURE 3 - The mold of Xantopren® is divided into four quadrants (q1, q2, q3, q4) with the aid of a line drawn in the largest longitudinal and transverse diameters. In each 4 quadrant measurement of mould thickness were performed (totalizing 16 measurement) with a stainless steel digital pachymeter and then the average thickness of measurement was calculated. Here is how to calculate the volume of the mold which corresponds to the volume of the wound based on the formula of the cylinder. Observe the wound (a) that was created in the foot of the pig (b). The mold used to calculate the volume of the wound has its margin marked by a dotted line.

We used the Student t test for independent samples to compare the mean and standard deviation of the volume of the wound obtained with the micropipette with volume measurement obtained with the mass of Xantopren®. Differences were considered significant when $p \leq 0.05$ (5%).

Results

The wounds produced by the removal of skin and subcutaneous tissues from the pig foot had different volumes in most cases. In some cases, the circle of skin removal was slightly higher; in other cases, the thickness of the subcutaneous tissue was higher. The two techniques used to calculate the volume of open skin wounds worked in all cases. The micropipette method was simpler and faster than the Xantopren®. The latter was harder as it involved the preparation of the mass, mold production, and calculation of this volume. The micropipette method was faster because, after filling the wound with saline, the calculated volume was immediately calculated as the volume injected by micropipette. The average volume of the wound in the 32 cases which used micropipette was 119.37 ± 30.87 microliters, and the

mold was calculated with $122.41 \pm 33.90 \text{ mm}^3$. There was no difference between these two volumes ($p = 0.79$) (Figure 4).

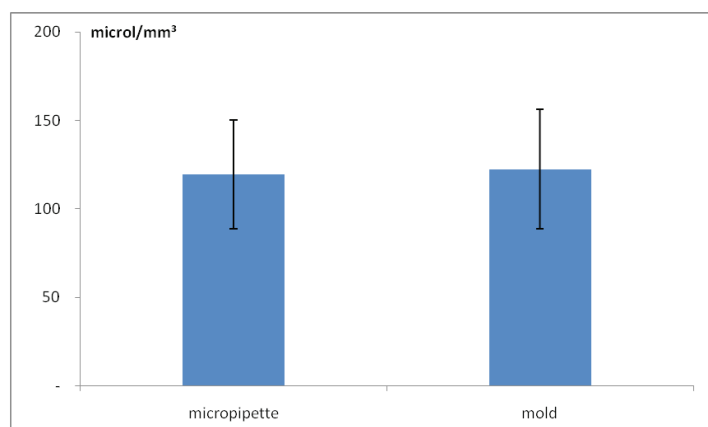


FIGURE 4 - Result of volumetry of open wound volume calculated with saline (micropipette) and mass Xantopren (mold), graphically represented by the arithmetic mean and standard deviation. Note that there were no significant differences between the two alternatives to measure the volume. p values >0.05 .

Discussion

The volumetry gives a fuller picture of the wound (length, width and depth), allows to verify objectively, at any time, the evolution of skin wound that heals from the bottom to the surface and the periphery to the center or vice versa. Until then, the methods used to evaluate the healing of these wounds evaluated at most only two dimensions (area) without assessing the depth¹⁻¹², which is the third dimension. The purpose of this study was to evaluate the wound in three dimensions: length, width and depth, which means the whole volume of the wound.

The volume with saline in pig foot proved to be simple and reproducible. The micropipettes used to drip the liquid inside the wound to calculate the volume had different sensitivities. This study employed three micropipettes with different volumes. This was done carefully in order to fill the lesion with no leakage or lack of fluid into the wound. Obviously, micropipettes with different sensitivities can be used according to the researcher's need. In addition to the micropipette we used a magnifying glass and a light focus in order to observe more clearly the time of filling and the leakage of fluid from the wound and to allow a more accurate measurement.

The volume with a mass of Xantopren® in pig foot was more difficult from the both the technical point of view and mathematical calculations. The product, after appropriate preparation, should be placed inside the wound for long enough to fill it completely. It should wait a few minutes after drying

before the material is removed for analysis. The material removed is a formless flat mass, about 5 cm long by 3cm wide and with a variable depth. In its middle the mould is present as the most prominent and regular part of the mass. The volume calculation must be based on a geometric figure that the mold closest resembles. In this study the geometrical figure was more like a cylinder. So the mathematical formula for calculating the volume was that of a cylinder. However, one should consider other possibilities of geometric figures that most closely resemble the mould as, for example, the truncated cone. In this case, one must employ a mathematical formula to calculate the volume of a truncated cone. And so on. That is, we must seek the formula of the volume of the figure that resembles mould. We should bear in mind that the mold can be weighed on a sensitive balance which can help to evaluate the wound healing. Thus, the decrease in the mold in the subsequent evaluations suggests that the wound is healing. The fact that 1microliter equals 1 mm^3 allowed us to compare the volume of the micropipette with the mold. In this comparison there were no significant differences between the average values of the mold with the micropipette. This suggests that one method validates the other, and both can be used to evaluate the healing of open wounds.

Volumetry could be used to help evaluate the healing of open skin wounds in experimental animals and humans. In experimental animals we can create a model of skin wound^{3,6,9} and test various types of local or systemic medications. Currently in our laboratory, the volume method is being studied in rats with wounds treated with red propolis and silver sulfadiazine using the technique of liquid volume and mass of Xantopren®. During the procedure the animal is sedated to the point of not moving during the examination, and allow for both techniques, with safety and reliability. The volumetry could be performed periodically (e.g. post-operatively and on day 3 postoperatively, at day 6 in the 9th and the 12th day after surgery) and thus help determine the evolution of the healing of a wound over time, using different types of treatment. Of course, photographs, histological injury and planimetry can enrich the study of healing of skin wounds. The volume of the wound with liquid dripped by pipette might be used in humans, since this technique is safe even if the saline solution is used for cleaning wounds. The patient should be directed to remain motionless during the examination, in a position such that the wound is visible in the horizontal position, so that the liquid dripped would drain and not distort the results. The evaluation with mold is more difficult and may not be ethical. It is possible that the volumetric liquid is useful to help evaluate the healing of chronic wounds which are common in ambulatory and bed sores. Studies along these lines could be further developed. Our findings suggest

that volume is a simple, accurate, inexpensive, reproducible method, allowing quantitative evaluation and statistical analysis, and might prove useful in clinical and experimental studies to evaluate the closure of open wounds in several treatment regimens.

Conclusion

Volumetry in pig feet is simple and reproducible. Volumetry using saline did not differ from volumetry with mass Xantopren. This method may be useful to help evaluate the healing of open skin wounds in experimental and clinical research.

References

1. Alves DFS, Cabral Júnior FC, Cabral PPA, Oliveira Junior RM, Meneses do Rego AC, Medeiros AC. Efeitos da aplicação tópica do mel de *melipona subnitida* em feridas infectadas de ratos. Rev Col Bras Cir. 2008;35(3):188-93. Disponível em URL: <http://www.scielo.br/rbc>.
2. Mendonça FAS, Passarini Junior JR, Esquisatto MAM, Mendonça JS, Franchini CC, Santos GMT. Effects of the application of Aloe vera (L.) and microcurrent on the healing of wounds surgically induced in Wistar rats. Acta Cir Bras. 2009;24(2):150-5. Available from URL: <http://www.scielo.br/acb>
3. Carvalho PTC, Mazzer N, Reis FA, Belchior ACG, Silva IS. Analysis of the influence of low-power HeNe laser on the healing of skin wounds in diabetic and non-diabetic rats. Acta Cir Bras. 2006;21(3):177-83. Available from URL: <http://www.scielo.br/acb>.
4. Trindade LCT, Biondo-Simões MLP, Sampaio CPP, Farias RE, Pierin RJ, Netto MC. Avaliação do uso tópico do metronidazol no processo de cicatrização de feridas: um estudo experimental. Rev Col Bras Cir. 2010;37(5):358-63. Disponível em URL: <http://www.scielo.br/rbc>
5. Dantas Filho AM, Aguiar JLA, Rocha LRM, Azevedo IM, Ramalho E, Medeiros AC. Effects of the basic fibroblast growth factor and its anti-factor in the healing and collagen maturation of infected skin wound. Acta Cir Bras. 2007;22(Suppl 1):64-71.
6. Garros IC, Campos ACL, Tâmbara EM, Tenório SB, Torres OJM, Agulham MA, Araújo ACF, Santis-Isolan PMB, Oliveira RM, Arruda ECM. Extract from *Passiflora edulis* on the healing of open wounds in rats: morphometric and histological study. Acta Cir Bras. 2006;21(Suppl 3):55-65.
7. Araújo LU, Grabe-Guimarães A, Mosqueira VCF, Carneiro CM, Silva-Barcellos NM. Profile of wound healing process induced by allantoin. Acta Cir Bras. 2010;25(5):460-1. Available from URL: <http://www.scielo.br/acb>.
8. Magalhães MSF, Fechine FV, Macedo RN, Monteiro DLS, Oliveira CC, Brito GAC, Moraes MEA, Moraes MO. Effect of combination of medium chain triglycerides, linoleic acid, soy lecithin and vitamins A and E on wound healing in rats. Acta Cir Bras. 2008;23(3):262-9.
9. Branco-Neto MLC, Ribas-Filho JM, Malafaia O, Oliveira-Filho MA, Czecko NG, Aoki S, Cunha R, Fonseca VR, Teixeira HM, Aguiar LRF. Avaliação do extrato hidroalcoólico de Aroeira (*Schinus terebinthifolius Raddi*) no processo de cicatrização de feridas em pele de ratos. Acta Cir Bras. 2006;21(Suppl 2):17-22. Disponível em URL: <http://www.scielo.br/acb>.
10. Amorim E, Matias JEF, Coelho JCU, Campos ACL, Stahke Jr HJ, Timi JRF, Rocha LCA, Moreira ATR, Rispoli DZ, Ferreira LM.

Efeito do uso tópico do extrato aquoso de *Orbignya phareolata* (Babaçu) na cicatrização de feridas cutâneas- estudo controlado em ratos. Acta Cir Bras. 2006;21 (Suppl 2):67-76. Disponível em URL: <http://www.scielo.br/acb>.

11. Santos MFS, Czecko NG, Nassif PAN, Ribas-Filho JM, Alencar BLF, Malafaia O, Ribas CAPM, Trautwein VM, Henriques GS, Maia JMA, Bittencourt RCA. Avaliação do uso do extrato bruto de jatropa gossypifolia L na cicatrização de feridas cutâneas em ratos. Acta Cir Bras. 2006;21(Suppl 3):2-7. Disponível em URL: <http://www.scielo.br/acb>.
12. Martins NLP, Malafaia O, Ribas-Filho JM, Heibel M, Baldez RN, Vasconcelos PRL, Moreira H, Mazza M, Nassif PAN. Análise comparativa da cicatrização da pele com o uso intraperitoneal de extrato aquoso de *Orbignya phareolata* (babaçu). Estudo controlado em ratos. Acta Cir Bras. 2006;21(Suppl 3):66-75. Disponível em URL: <http://www.scielo.br/acb>.

Acknowledgments

Renan Lopes Nogueira, Débora Carara Ramos, Luana Castro de Rezende Fiorotti, Ramos da Silva Souza, Luiz Carlos Barros de Castro Segundo, Medical Students, EMESCAM, for helping with technical procedures.

Correspondence:

Prof. Dr. Danilo Nagib Salomão Paulo
Rua Santa Rita, 777
29042-753 Vitória – ES Brasil
Tel.: (55 27)3222-1545
danilo.vix@terra.com.br

Received: April 19, 2011

Review: June 15, 2011

Accepted: July 20, 2011

Conflict of interest: none

Financial source: Espirito Santo Research Foundation (FAPES) and Department for Support of Clinical Experimental Research for Sustainable Development (EMESCAM).

¹Research performed at the Research Center, Department of Surgery, School of Science, Santa Casa de Misericórdia, EMESCAM, Vitoria-ES, Brazil.