

Ultrasonography and swallowing: a critical review of the literature

Ultrassonografia e deglutição: revisão crítica da literatura

Karoline Kussik de Almeida Leite¹, Laura Davison Mangilli², Fernanda Chiarion Sassi³, Suelly Cecília Olivan Limongi⁴, Cláudia Regina Furquim de Andrade⁴

ABSTRACT

Purpose: To identify how the deglutition function has been evaluated using ultrasound (US). **Research strategy:** This literature review used the PubMed database to survey international scientific publications about US and its use to evaluate deglutition. Studies were located and selected by surveying relevant articles published between January 2002 and August 2013. The survey was limited to studies on humans published in English. **Selection criteria:** Repeated studies (determined by overlapping keywords), case studies, literature reviews, letters to the editor and studies not directly related to the topic were excluded. **Results:** A total of 17 studies matching the inclusion criteria were identified. More than half of the studies evaluated the deglutition of healthy adults with no preference for gender. The parameters adopted for image analysis were not unanimous, and there was considerable variation among studies. **Conclusion:** US proved to be a fast, non-invasive, low-cost method for evaluating objective parameters of deglutition. As a further advantage, US may be performed at bedside because the equipment is typically easy to handle and transport.

Keywords: Ultrasonography; Ultrasonics; Deglutition; Deglutition disorders; Evaluation

RESUMO

Objetivo: Identificar como a função da deglutição tem sido avaliada por meio da ultrassonografia (USG). **Estratégia de pesquisa:** Esta revisão da literatura levantou publicações científicas internacionais sobre a USG e seu uso na avaliação da deglutição, por meio da base de dados PubMed. Foi realizada a localização e seleção dos estudos através de levantamento de textos publicados sobre o assunto, no período de janeiro de 2002 a agosto de 2013, limitando-se a estudos em seres humanos, no idioma inglês. **Critérios de seleção:** Foram excluídos aqueles repetidos por sobreposição das palavras-chave, estudos de caso, revisões de literatura, cartas ao editor e os não relacionados diretamente à temática. **Resultados:** Foram identificados 17 estudos que corresponderam aos critérios de inclusão. Observou-se que mais da metade dos estudos avaliou a deglutição de indivíduos adultos saudáveis, sem preferência por nenhum dos gêneros. Os parâmetros adotados para a análise das imagens não foram unânimes, havendo variação considerável entre os estudos. **Conclusão:** A USG da deglutição demonstrou ser um método rápido, não invasivo, de baixo custo, que fornece parâmetros objetivos sobre a deglutição e que pode ser realizado em beira de leito, uma vez que o equipamento costuma ser de fácil manuseio e transporte.

Descritores: Ultrassonografia; Ultrassom; Deglutição; Transtornos de deglutição; Avaliação

Study conducted at the Department of Physical, Speech and Occupational Therapy, School of Medicine, Universidade de São Paulo and Clinics Hospital, School of Medicine, Universidade de São Paulo – USP – São Paulo, (SP), Brazil.

(1) Enhancement Program in Hospital Speech Therapy in Orofacial Functions, Speech Therapy Support Unit, Clinics Hospital Central Institute, School of Medicine, Universidade de São Paulo – USP – São Paulo, (SP), Brazil.

(2) Rehabilitation Sciences Medical Research Laboratory, Clinics Hospital, School of Medicine, Universidade de São Paulo – USP – São Paulo, (SP), Brazil.

(3) Department of Physical, Speech and Occupational Therapy, School of Medicine, Universidade de São Paulo – USP – São Paulo, (SP), Brazil.

(4) Department of Physical, Speech and Occupational Therapy, School of Medicine, Universidade de São Paulo – USP – São Paulo, (SP), Brazil; Speech Pathology Service, Clinics Hospital Central Institute, School of Medicine, Universidade de São Paulo – USP – São Paulo, (SP), Brazil.

Conflict of interests: No

Authors' contribution: *KKAL*: study development, literature review, collection/analysis and interpretation of data, manuscript writing; *LDM*: study development, timeline development, literature review, collection/analysis and interpretation of data, manuscript writing, manuscript submission and procedures; *FCS*: study development, timeline development, collection/analysis and interpretation of data, manuscript writing, manuscript submission and procedures; *SCOL*: co-advisor, study development, timeline development, approval of the final version; *CRFA*: advisor, study development, timeline development, data analysis and interpretation, manuscript text correction and approval of the final version.

Correspondence address: Cláudia Regina Furquim de Andrade. R. Cipotânea, 51, Cidade Universitária, São Paulo (SP), Brazil, CEP: 05360-160. E-mail: clauan@usp.br

Received on: 2/12/2014; **Accepted on:** 7/16/2014

INTRODUCTION

Ultrasound (US) involves placing a transducer on the body part being examined to transform the echoes reflected by the human body into signals that are electronically decoded to form an image⁽¹⁾. US is a noninvasive examination that provides dynamic images that focus on the soft tissues and body structures⁽²⁾. The technique is widely applied in clinical practice because of its low cost, safety, speed and lack of radiation⁽³⁾.

US is a viable option for studying the oral and pharyngeal structures involved in deglutition^(2,3). Some advantages related to its use include the possibility of using food under regular conditions without the presence of contrasts and/or dyes and the portability of the device, which allows the test to be performed at bedside⁽²⁾.

The structures and variables most often analyzed in deglutition studies are the amount and duration of hyoid bone elevation; glottal closure (frequency, latency, response and duration); the amplitude and speed of the vertical movement of the tongue; the total duration of deglutition; the mobility and function of the phonoarticulatory organs during deglutition; the distance between the hyoid bone and the larynx during deglutition; and the laryngeal elevation (beginning, peak and duration)^(3,4).

The literature describes the use of US during deglutition in both healthy and sick individuals for organ analysis or for diagnosing dysphagia^(2,5). US can also be performed in patients of different age groups and is considered a noninvasive, accurate method for visualizing bolus movement in the pharyngeal phase of deglutition during infant feeding⁽⁶⁾.

PURPOSE

The present study aimed to determine how US has been used to assess deglutition based on refereed literature.

RESEARCH STRATEGY

To establish the search method, the precepts of the Cochrane Handbook⁽⁷⁾ were followed.

The studies were located and selected by surveying articles on the subject published between August 2002 and August 2013. The articles were selected from the PubMed database and were limited to studies performed on humans and published in English. The following descriptors were used: “Ultrasound and Deglutition”, “Ultrasound and Deglutition Disorders”, “Ultrasound Diagnosis and Deglutition”, “Ultrasound Diagnosis and Deglutition Disorders”, “Ultrasonography and Deglutition”, “Ultrasonography and Deglutition Disorders”, “Ultrasonography Diagnosis and Deglutition”, “Ultrasonography Diagnosis and Deglutition Disorders”.

SELECTION CRITERIA

The database searches were performed independently by the researchers to minimize the possible loss of citations and to analyze the relevance of each retrieved citation for selection and inclusion in the study. Citations in languages other than English were excluded, as were those that contained overlapping keywords. Among the full articles obtained, case studies, literature reviews, letters to the editor and those not directly related to the topic were excluded. Articles that were effectively related to the research proposal were analyzed. The researchers conducted all stages of the study independently; when disagreements occurred, only articles with consensual final agreement were included. By its nature, this study was not single-blind (Figure 1).

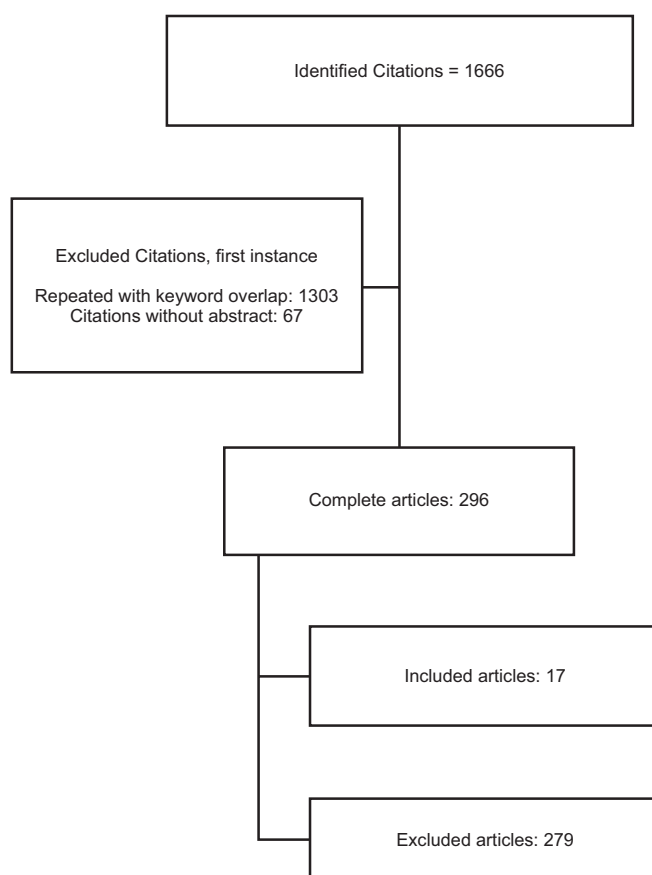


Figure 1. Search pathway for article selection

The rationale for the exclusion of 279 citations is provided in Table 1.

DATA ANALYSIS

The 17 citations selected were critically evaluated in terms of their objectives; number, gender and ages of the participants; criteria and evaluation methods; results; and conclusions.

Regarding the criteria and evaluation methods, we sought to assess and describe the methods used in the articles to determine

Table 1. Articles excluded because of a lack of direct relation to the topic

Excluded articles	n
Esophagus-related study	179
US for diagnostic purposes (not specific to deglutition)	44
Used other complementary tests (non-US)	11
US for treatment control	16
Review articles	6
Studies of fetuses	5
US for analysis of other body parts	7
Animal studies	4
US used for surgery control	3
Nonspecific articles	3
US for mastication analysis	1

Note: US = ultrasound; n = number of citations

whether there was homogeneity among them.

Regarding the results and conclusions, in addition to the general information the articles provided in these sections, we also noted the advantages and disadvantages of the techniques discussed in each study.

RESULTS

The results of the study are briefly described in Chart 1.

Chart 1. Summary of the articles included in the study

Reference	Objective	Method	Results and Conclusions
Yabunaka et al., 2011 ⁽³⁾	To evaluate the movement of the hyoid bone and the changes arising from aging during deglutition in healthy patients using ultrasound.	- 30 adults with no complaints or history of deglutition difficulties divided into three groups: 20-39 years old (5 men and 5 women); 40-59 years old (5 men and 5 women); 60-79 years old (5 men and 5 women). - Variable: trajectory of the hyoid bone (slowly ascending phase, rapidly ascending phase, temporary pause phase and resting position phase) during deglutition of 5 ml of water.	- Mean duration of deglutition increased and peak elevation of the hyoid bone decreased with advancing age. - US can be a quantitative method for clinically evaluating hyoid bone movement during deglutition.
Scarborough et al., 2010 ⁽²⁾	To explore the parameters of maximum displacement of the hyoid bone during spontaneous deglutition in healthy preschool children using US. To observe whether gender is associated with greater displacement of the hyoid bone.	- 29 subjects (16 boys and 13 girls) with a mean age of 4 years and 2 months, ranging from 3 years to 4 years and 10 months. - Variable: amount of hyoid bone elevation when swallowing two food consistencies (puree and liquid) at three different volumes (0.5, 1.5 and 2.5 ml).	- A significant gender effect was observed for all consistencies and volumes: the mean hyoid bone movement was significantly greater in females. - The study concluded that gender can influence the amount of hyoid bone elevation in children.
Galén & Jost-Brinkmann, 2010 ⁽¹⁴⁾	To investigate the possibility of using B-mode and M-mode US to differentiate visceral and somatic deglutition.	- 11 patients referred for orofacial myofunctional therapy (for anterior open bite or excessive overjet and visceral deglutition pattern). - B-mode and M-mode US was applied before and after myofunctional therapy. - Variable: the amplitude and speed of the vertical movement of the tongue and total duration of deglutition of saliva (at least 6 deglutition episodes from each participant). - 13 subjects with visceral deglutition pattern and normal occlusion comprised the control group.	- There was wide intraindividual variability in the variables studied, making interindividual comparisons difficult. - The M-mode images determined the amplitude and speed of the vertical movement of the tongue and the total duration of deglutition. - The B-mode images did not identify characteristics that could be designated as only visceral or physiological deglutition movements.

DISCUSSION

After analyzing the selected articles, we observed that the studies that used US to assess deglutition could be divided into three groups: studies that investigated the deglutition of healthy individuals (52.9%)^(2,3,6,8-13); studies that compared the deglutition of diseased individuals and their healthy controls^(14,15-19) (i.e., those with craniofacial abnormalities⁽¹⁴⁾ [16.7%], stroke^(15,18,19) [50%] and neurogenic dysphagia^(16,17) [33.3%]) to that of healthy controls (35.3%)^(14,15-19); and studies that investigated deglutition in two specific diseases^(5,20) (11.8%): nephropathic cystinosis and amyotrophic lateral sclerosis.

Regarding the participants' gender, most of the studies included individuals of both genders (82.3%)^(2,3,5,8-11,13,15-20). Only one study included only male subjects⁽¹²⁾ (5.9%).

The age of the participants varied considerably among the studies. Most of the studies^(5,15-19) included adult and elderly subjects (35.2%). Some of the studies^(3,9,10) divided the adults into different age groups (17.6%), and others^(8,12) examined adults of a particular age group (11.8%). Studies involving children and infants were the minority^(2,6,11,13,20) (29.41%).

The parameters evaluated during the US examination were not unanimous. In seven studies^(2,3,9,10,12,15,16) (41.1%), the

Chart 1. Summary of the articles included in the study (cont.)

Reference	Objective	Method	Results and Conclusions
Tamburrini et al., 2010 ⁽⁵⁾	To determine the role of US in diagnosing dysphagia in patients with amyotrophic lateral sclerosis (ALS).	<ul style="list-style-type: none"> - 9 patients underwent simultaneous static and dynamic deglutition examinations with US and videofluoroscopy (VDF), respectively: 5 presented with classic ALS and 4 with bulbar ALS; 8 subjects were clinically dysphagic. - Variable: mobility/function of the orofacial myofunctional organs during deglutition, especially during the oropharyngeal phase. - 3 volumes of water (5, 10 and 15 ml) were offered. 	<ul style="list-style-type: none"> - Static phase: 5 patients had tongue atrophy. Abnormal bolus position was observed in 6 patients with US and in 3 patients with VDF. Both techniques identified the inability to maintain the bolus in the oral cavity in 4 patients. - Dynamic phase: decreased tongue movement was observed in 5 patients with US and in 2 patients with VDF. Disorganized movement of the tongue was observed in 3 patients with US and in 2 patients with VDF. - Multiple deglutitions were only visualized with US. The presence of stasis was not observed with US, whereas it was observed in 2 patients with VFS. - US of the tongue is complementary to VDF, as it provides a precise description of the oral phase of deglutition.
Geddes et al., 2009 ⁽⁶⁾	To develop a rough visualization of infants during breastfeeding using US and to determine the accuracy of the US image of deglutition compared with respiratory plethysmography in a cohort of infants.	<ul style="list-style-type: none"> - 16 lactating women and their healthy infants participated in the study. The infants were between 24 and 156 days of age (mean of 57 days) and were within the normal parameters of growth for their age (mean of 4871 g). - US was used to examine deglutition, and plethysmography was used to verify breathing. - Variables: duration of deglutition and of deglutition apnea. To measure breathing during deglutition, breast-feeding was recorded. 	<ul style="list-style-type: none"> - US is a noninvasive, accurate method for visualizing the movement of the milk bolus during the pharyngeal phase of deglutition. - Deglutition apnea was identified using US, and the results correlated well with the results of respiratory inductive plethysmography. - The combined use of these techniques has the potential to provide useful information in cases of breastfeeding difficulties.
Jadcherla et al., 2009 ⁽¹¹⁾	To investigate the pharyngoglottal relationship during basal and adaptive deglutition.	<ul style="list-style-type: none"> - 12 healthy neonates who were orally fed without structural, chromosomal, or neurological disturbances. - Simultaneous pharyngoesophageal manometry, plethysmography, electromyography (submental) and glottal US were used. - Variables: temporal changes in the kinetics of glottal closure (frequency, response latency and duration) during spontaneous and adaptive pharyngeal deglutition. 	<ul style="list-style-type: none"> - Glottal adduction during basal or adaptive deglutition occurs in any respiratory phase, thus ensuring airway protection before and during deglutition. - The duration of adduction of the pharyngeal-glottal closure reflex suggests a state of glottal hypervigilance in preventing aspiration during deglutition or during events of high gastroesophageal reflux. - Investigation of the pharyngoglottal relationship using noninvasive methods may be more acceptable for patients and is applicable to all ages.
Huang et al., 2009 ⁽¹⁵⁾	To evaluate the reliability of US in stroke patients with or without dysphagia.	<ul style="list-style-type: none"> - 55 adults divided into 3 groups: 15 normal (control group); 20 with stroke and without dysphagia (G1); 20 with stroke and with dysphagia (G2). - Variable: distance between the hyoid bone and larynx during deglutition. - Participants had to swallow 3 times with an interval of 1-2 minutes between each deglutition. 	<ul style="list-style-type: none"> - The distance between the hyoid bone and the thyroid cartilage was significantly greater in normal subjects compared with stroke patients and even greater compared with patients with stroke and dysphagia. - The distance between the hyoid bone and the thyroid cartilage during deglutition was significantly smaller in normal subjects than in the stroke group. - The hyoid-larynx approximation was smaller in dysphagic patients with stroke than in stroke patients without dysphagia. - The hyoid-larynx approximation can be quantitatively and reliably evaluated by US using a simple clinical setting.

Chart 1. Summary of the articles included in the study (cont.)

Reference	Objective	Method	Results and Conclusions
Welge-Lüssen et al., 2009 ⁽⁸⁾	To examine whether retronasal olfaction combined with simultaneous gustatory stimuli affects deglutition differently than orthonasal olfaction.	- 47 healthy, non-smoking adults. - US (transducer placed on the floor of the mouth) of deglutition. - Variable: tongue movements (speed and frequency) during deglutition and after the presentation of an olfactory stimulus and latency of deglutition. A sweet taste was presented simultaneously with an essence of an edible food (randomly presented either ortho- or retronasally) using a computer-controlled olfactometer.	- After retronasal stimulation, deglutition occurred significantly more rapidly and more frequently compared with deglutition after orthonasal stimulation. - These results show that an essence of edible food presented as retronasal stimulation in combination with a congruent taste stimulus may influence deglutition.
Komori et al., 2008 ⁽¹²⁾	To evaluate a new method of bedside deglutition assessment that combined US and videoendoscopy (VED) compared with videofluoroscopy (VDF) alone.	- 8 healthy male volunteers aged 25-31 years with no deglutition disorders. - Simultaneous combined videoendoscopy (VED), US of deglutition and videofluoroscopy of deglutition (VDF). - Variable: laryngeal elevation (beginning, peak and duration).	- The beginning of laryngeal elevation was identified with VDF and US. - After the beginning, the pharynx became invisible with VED. - The peak elevation of the larynx was identified with VDF and US, and this moment was almost identical in both examinations. - The distance and duration of peak laryngeal elevation, measured with US and with VDF, were almost equal and were positively correlated. - This study suggests that the combined technique (US + VED) can demonstrate the deglutition function as efficiently as VDF.
Peng et al., 2007 ⁽¹³⁾	To evaluate the movement of the tongue during deglutition using a system assisted by M-mode US.	- 55 individuals (30 females and 25 males) with a mean age of 22.7 years (8 to 50 years). - Variable: movement pattern and duration of the activity of the dorsum of the tongue. Three deglutitions of saliva from each subject were evaluated using M-mode US. The images obtained with US were video recorded and evaluated.	- The duration, amplitude and pattern of tongue movements during deglutition varied considerably among individuals. - M-mode US provides valid information about tongue movements without any side effects and is therefore a useful tool in the diagnosis and research of tongue functions in orthodontics and dentistry.
Sonies et al., 2005 ⁽²⁰⁾	To evaluate the deglutition function of patients with cystinosis, with special attention to the effects of cysteamine treatment.	- 101 patients with nephropathic cystinosis diagnosis. - Oropharyngeal US was used. - Variables: movement of the tongue and of the hyoid bone during deglutition, duration of the oropharyngeal phase of deglutition and movements of the tongue and the hyoid bone needed to initiate and complete deglutition.	- Oral motor dysfunction of deglutition in patients with cystinosis progressively increases with age and is correlated with generalized muscular dysfunction but not with the severity of disease in general. - Long-term therapy of oral cysteamine seems to reduce the severity of oral motor dysfunction and deglutition. - Deglutition dysfunction in patients with cystinosis presents a risk of fatal aspiration and correlates with the presence of muscle atrophy.
Kuhl et al., 2003 ⁽¹⁶⁾	To noninvasively analyze the vertical movement of the larynx during deglutition using US techniques in patients with dysphagia and in healthy subjects.	- 18 patients (mean age: 63 ± 8 years) with dysphagia caused by neurological diseases. - Control group was composed of 42 healthy subjects (mean age 57 ± 19 years). - Deglutition US was used. - Variables: distance between the hyoid bone and the upper edge of the thyroid cartilage during laryngeal elevation in deglutition.	- Healthy subjects: mean distance of 220 mm (± 30) at rest; the shortest distance during deglutition of 5 or 10 ml of water was 85 mm (± 11), representing a reduction of 61% (± 3) under physiological conditions. - Neurogenic dysphagia patients: the mean relative elevation of the larynx was reduced to only 42% (± 10). - US is a viable, noninvasive method for investigating the elevation of the larynx during deglutition. - US allows direct visualization of the larynx in patients with neurogenic dysphagia.

Chart 1. Summary of the articles included in the study (cont.)

Reference	Objective	Method	Results and Conclusions
Söder & Miller, 2002 ⁽¹⁷⁾	To determine the extent of intrapersonal variability in the duration of tongue movement during deglutition.	<ul style="list-style-type: none"> - 10 individuals diagnosed with neurogenic dysphagia. - 10 subjects without disturbances and with no diagnosis of dysphagia (control group). - Deglutition US was used. - Variable: total duration of movement of the tongue and the duration of the oral transport phase during deglutition. The subjects were instructed to swallow water and, after 10 seconds, to swallow saliva. The investigation continued in this manner until at least 15 dry deglutitions were recorded. 	<ul style="list-style-type: none"> - The results indicate considerable intrapersonal variability in both groups. - There were no significant differences between groups. - US was a highly suitable technique for the purpose of the study.
Chi-Fishman & Sonies, 2002 ⁽⁹⁾	To investigate the movement of the hyoid bone during the deglutition of different consistencies.	<ul style="list-style-type: none"> - 31 healthy individuals (16 male, 15 female) divided into three age groups: 20-39 years, 40-59 years and 60-79 years. - Deglutition US was used. - Variables: hyoid bone movement - duration of the movement, actions, maximum amplitudes, total distances, and peak velocities - analyzed in relation to the variance of viscosity, volume, age and gender. - 612 deglutitions were studied. 	<ul style="list-style-type: none"> - The results showed that older individuals were slower to start deglutition and also presented with higher maximum vertical amplitude, higher total vertical distance and higher peak velocity compared with younger individuals. - Males had higher values for most of the motion parameters. - The results illustrate the importance of examining the relationships among the movement variables to better understand the tasks and strategies of motor control. - The evidence also illustrates the functional adaptation of the infrahyoid muscles and their compensation in healthy elderly adults.
Chi-Fishman & Sonies, 2002 ⁽¹⁰⁾	To examine the details of the relationships among the kinematic variables to distinguish strategies of hyoid bone movement in discrete deglutition and in fast sequential deglutition.	<ul style="list-style-type: none"> - 30 healthy subjects divided into three age groups: 20-39 years, 40-59 years and 60-79 years. - Variables: movement, movement duration and maximum amplitude of the hyoid bone. - Changes in the position of the hyoid bone were recorded for a total of 236 discrete deglutitions and 318 rapid sequential deglutitions. 	<ul style="list-style-type: none"> - Rapid sequential deglutitions differ significantly from discrete deglutitions in relation to the movement of the hyoid bone. - When instructed to swallow as quickly as possible, the subjects achieved the smallest movement without increasing the peak speed. This finding suggests greater flexibility in the functional range of movement of the hyoid bone.
Kim & Kim, 2012 ⁽¹⁸⁾	To analyze the movement of the lateral wall of the pharynx using US.	<ul style="list-style-type: none"> - 26 individuals with stroke and dysphagia and 15 healthy individuals. - Individuals with stroke and dysphagia were divided into two groups (A and B) based on videofluoroscopy swallow studies (VFSS). In Group A (n = 12), the subjects presented with penetration or aspiration on the VFSS, while in Group B (n = 14), there was no evidence of penetration or aspiration. - Variables: movement of the lateral pharyngeal wall. The movement was assessed by B/M-mode US. - Comparative analysis between the groups and the relationship between movement parameters in the pharyngeal phase was performed. 	<ul style="list-style-type: none"> - The mean pharyngeal displacement in Groups A and B was significantly smaller compared with that of healthy individuals. - The mean duration of pharyngeal movement of Groups A and B was longer than that of healthy individuals. - The mean displacement in Group A was significantly correlated with residue in the vallecula, duration of the delay of pharynx movement and larynx elevation.

Chart 1. Summary of the articles included in the study (cont.)

Reference	Objective	Method	Results and Conclusions
Hsiao et al., Jan 2012 ⁽¹⁵⁾	To measure changes in tongue thickness of and hyoid bone displacement in patients with stroke using US examination in the submental region.	<ul style="list-style-type: none"> - 60 stroke patients (30 with exclusive alternative feeding and 30 with regular oral intake). - 30 healthy subjects. Another 10 healthy subjects were included to assess the reliability of the examination. - The subjects were instructed to swallow 5 ml of water. During deglutition, videofluoroscopy and US were performed in the mentonian region. The videofluoroscopy exam was complementary to the US for evaluating the displacement of the hyoid bone. 	<ul style="list-style-type: none"> - The changes in tongue thickness and hyoid bone displacement were significantly smaller in stroke patients with exclusive alternative feeding compared with stroke patients with oral intake. - No significant changes were observed between the control group and stroke patients with oral intake in either the tongue thickness or the displacement of the hyoid bone. - US of the submental region showed good reliability and correlated well with videofluoroscopy.

lifting motion of the hyoid bone during deglutition was assessed, and in four of those studies^(3,9,10,12), the duration of hyoid movement was also considered. Four studies^(8,13,14,17) evaluated tongue movements during deglutition (23.5%), and the others assessed different parameters: mobility and functionality of the phonoarticulatory organs during deglutition⁽⁵⁾ (5.9%); duration of deglutition and apnea⁽⁶⁾ (5.9%); glottal closure and its characteristics (frequency, response latency and duration)⁽¹¹⁾ (5.9%); movement of the lateral wall of the pharynx⁽¹⁸⁾ (5.9%); movement of the hyoid bone and tongue thickness⁽¹⁹⁾ (5.9%); and tongue and hyoid bone movements during deglutition⁽²⁰⁾ (5.9%).

For a better discussion of the studies' methods, results and conclusions, the articles were grouped according to the parameters considered for the assessment, as described above.

In studies that assessed the movement of the hyoid bone - elevation and/or duration - the overall objective was to correlate the movement of the hyoid bone with the participant's age, gender and clinical status. A longer mean duration of hyoid bone elevation was observed with increasing age, as was decreased peak elevation of the hyoid bone⁽³⁾. A study conducted with children found that gender may affect hyoid bone elevation - the mean movement was significantly greater in females⁽²⁾. Regarding the participant's clinical condition, the hyoid bone movement was significantly greater in healthy subjects compared with individuals with neurogenic dysphagia^(15,16).

All of the studies that assessed the hyoid bone movement found that US could quantitatively and reliably evaluate this parameter.

Among the studies that assessed tongue movement during deglutition, two subgroups could be defined. The first subgroup aimed to determine the extent of intrapersonal variability in the duration of tongue movements during deglutition. The results indicated high intrapersonal variability in both healthy individuals and individuals with neurogenic dysphagia; however, greater variability in the duration of the transport phase was observed in the dysphagic group⁽¹⁷⁾. The second subgroup^(13,14) investigated US modes using tongue movement as the parameter of interest. High intra- and/or interpersonal variability was also found in

this parameter, and it was observed that M-mode US provided better information about tongue movement during deglutition.

For all of the studies in this group, US provided information about tongue movements during deglutition without any side effects, and it was considered a useful tool. It should be noted that most of the studies concluded that this parameter exhibits high intra- and interpersonal variability, which can often complicate data analysis, as described by Galen and Jost-Brinkmann (2010)⁽¹⁴⁾.

The other parameters were only investigated in single studies. Thus, the conclusions regarding the use of US and its results apply to only one study per parameter.

One of the studies investigated the mobility and function of the phonoarticulatory organs during deglutition. The authors sought to determine the role of US in the diagnostic evaluation of dysphagia in patients with amyotrophic lateral sclerosis (ALS). The exam was conducted concurrently with deglutition videofluoroscopy (VDF), and the study found that US provided static and dynamic functionality data for the oropharyngeal phase of deglutition more efficiently than VDF. Thus, the authors concluded that US should be used as a complement to VDF because it provides a precise description of the oral deglutition phase⁽⁵⁾.

Using deglutition apnea as parameter, one study evaluated the ability of US to identify deglutition apnea in infants⁽⁶⁾. The study involved the concomitant use of US and respiratory plethysmography and showed that the passage of the bolus during pharyngeal deglutition in a nursing child can be recorded using US, regardless of the respiration phase. Deglutition US was correlated with deglutition apnea detected with respiratory inductive plethysmography. Both techniques, when combined, have the potential to provide useful information about children who have nursing difficulties.

A study conducted in healthy newborns used the parameter glottal closure to investigate the concomitant use of esophageal manometry and glottis US. It found that glottal adduction during basal or adaptive deglutition occurs in any respiratory phase, thus ensuring protection of the airways against aspiration before or during deglutition. The methods used in this assessment

allowed the study of glottis movement during deglutition, and it was concluded that investigation of the pharyngeal-glottal relationship using non-invasive methods, such as US, may be acceptable for and applicable to all ages⁽¹¹⁾.

One study examined the duration of the pharyngeal phase of deglutition based on the tongue and hyoid bone movements needed to start and finish deglutition. For this purpose, US was used to assess the deglutition of 101 patients with nephropathic cystinosis. The authors found that oral motor dysfunction of deglutition in patients with cystinosis increases progressively with age and is correlated with generalized muscular dysfunction but not with disease severity. Based on cross-sectional data, the dysfunction increased with increasing age and the number of years without cysteamine treatment⁽²⁰⁾.

A study conducted with healthy subjects and stroke patients used the displacement and duration of pharyngeal movement during deglutition as a parameter. The patients were subdivided into two groups: the first (Group A) consisted of patients who presented with penetration and/or aspiration of food, indicated through VDF, and the second (Group B) consisted of patients with no VDF findings. The mean pharyngeal displacement of Groups A and B was significantly lower compared with that of healthy individuals, while the mean duration of pharyngeal movement of Groups A and B was longer than that of healthy individuals. In conclusion, the study indicated that the use of US to analyze pharyngeal movement may help to quantify pharyngeal function and can serve as a complementary method for the anatomical evaluation of the pharyngeal phase in patients with stroke and dysphagia⁽¹⁸⁾.

Another study analyzed the hyoid bone movement and tongue thickness. These parameters were compared between healthy individuals and stroke patients with and without the use of an alternative feeding route. The study found significantly less hyoid bone displacement and tongue thickness in patients fed exclusively by an alternate route compared with stroke patients with oral ingestion. No significant differences in either variable were observed between the control group and the stroke patients with oral ingestion⁽¹⁹⁾.

Generally, all of the articles assessed found that deglutition US was a fast, noninvasive, low-cost method that provides objective information about parameters of deglutition and can be performed at bedside because the equipment is usually easy to handle and transport. Equally important, the authors of the examined studies all concluded that deglutition assessment with US has some inherent disadvantages, including the following: the pressure exerted by the transducer on the examined structure, transducer positioning and the lack of precise anatomical markers for some of the structures being investigated. Because of these limitations, although US was effective for the initial diagnosis of impaired deglutition, it should be used in conjunction with other exams that complement the assessment of phonoarticulatory organ function during deglutition to accurately diagnose dysphagia.

CONCLUSION

The heterogeneity of the studies showed that different groups and pathologies can be assessed with US; however, the methodological variability of the included studies hinders the definition and generalization of the patterns found.

The present review found that US examination is effective for assessing the components involved in the dynamics of deglutition, especially the oral and early pharyngeal phases, such as phonoarticulatory organ function, deglutition apnea duration, glottal closure and its aspects, and hyoid bone movement. However, US should not replace other examinations that assist in the assessment of the pharyngeal and esophageal phase and in dysphagia diagnosis because US cannot identify some dynamic components of function, such as food stasis in the pharynx. Thus, US has been used as a complement to VDF, plethysmography, surface electromyography (EMG), deglutition videoendoscopy and manometry to provide more reliable parameters of the oral phase and the beginning of the pharyngeal phase of deglutition.

REFERENCES

1. Santos HCO, Amaral WN, Tacon KCB. A história da ultrassonografia no Brasil e no mundo. *EFDeportes.com Rev Digit.* 2012 [acesso em 12 jan 2014];17(167). Disponível em: <http://www.efdeportes.com/efd167/a-historia-da-ultrassonografia.htm>
2. Scarborough DR, Waizenhofer S, Siekemeyer L, Hughes M. Sonographically measured hyoid bone displacement during swallow in preschool children: a preliminary study. *J Clin Ultrasound.* 2010;38(8):430-4. <http://dx.doi.org/10.1002/jcu.20733>
3. Yabunaka K, Sanada H, Sanada S, Konishi H, Hashimoto T, Yatake H, et al. Sonographic assessment of hyoid bone movement during swallowing: a study of normal adults with advancing age. *Radiol Phys Technol.* 2011;4(1):73-7. <http://dx.doi.org/10.1007/s12194-010-0107-9>
4. Ardakani FE. Evaluation of swallowing patterns of the tongue using real-time B-mode sonography. *J Contemp Dent Pract.* 2006;7(3):67-74.
5. Tamburrini S, Solazzo A, Sagnelli A, Del Vecchio L, Reginelli A, Monsorò M, et al. Amyotrophic lateral sclerosis: sonographic evaluation of dysphagia. *Radiol Med.* 2010;115(5):784-93. <http://dx.doi.org/10.1007/s11547-010-0523-2>
6. Geddes DT, Chadwick LM, Kent JC, Garbin CP, Hartmann PE. Ultrasound imaging of infant swallowing during breast-feeding. *Dysphagia.* 2010;25(3):183-91. <http://dx.doi.org/10.1007/s00455-009-9241-0>
7. Higgins JPT, Green S, editors *Cochrane handbook for systematic reviews of interventions Version 5.1.0* [internet]; Baltimore: The Cochrane Collaboration; 2011 [acesso em 11 maio 2011]. Disponível em: <http://www.cochrane.org/training/cochrane-handbook>
8. Welge-Lüssen A, Ebnöther M, Wolfensberger M, Hummel T. Swallowing is differentially influenced by retronasal compared with orthonasal stimulation in combination with gustatory stimuli. *Chem Senses.* 2009;34(6):499-502. <http://dx.doi.org/10.1093/chemse/bjp024>

9. Chi-Fishman G, Sonies BC. Effects of systematic bolus viscosity and volume changes on hyoid movement kinematics. *Dysphagia*. 2002;17(4):278-87. <http://dx.doi.org/10.1007/s00455-002-0070-7>
10. Chi-Fishman G, Sonies BC. Kinematic strategies for hyoid movement in rapid sequential swallowing. *J Speech Lang Hear Res*. 2002;45(3):457-68. [http://dx.doi.org/10.1044/1092-4388\(2002\)036](http://dx.doi.org/10.1044/1092-4388(2002)036)
11. Jadcherla SR, Gupta A, Wang M, Coley BD, Fernandez S, Shaker R. Definition and implications of novel pharyngo-glottal reflex in human infants using concurrent manometry ultrasonography. *J Gastroenterol*. 2009;104(10):2572-82. <http://dx.doi.org/10.1038/ajg.2009.411>
12. Komori M, Hyodo M, Gyo K. A swallowing evaluation with simultaneous videoendoscopy, ultrasonography and videofluorography in healthy controls. *ORL J Otorhinolaryngol Relat Spec*. 2008;70(6):393-8. <http://dx.doi.org/10.1159/000163036>
13. Peng CL, Miethke RR, Pong SJ, Lin CT. Investigation of tongue movements during swallowing with M-mode ultrasonography. *J Orofac Orthop*. 2007;68(1):17-25. <http://dx.doi.org/10.1007/s00056-007-0547-y>
14. Galén S, Jost-Brinkmann PG. B-mode and M-mode ultrasonography of tongue movements during swallowing. *J Orofac Orthop*. 2010;71(2):125-35. <http://dx.doi.org/10.1007/s00056-010-9928-8>
15. Huang YL, Hsieh SF, Chang YC, Chen HC, Wang TG. Ultrasonographic evaluation of hyoid-larinx approximation in dysphagic stroke patients. *Ultrasound Med Biol*. 2009;35(7):1103-8. <http://dx.doi.org/10.1016/j.ultrasmedbio.2009.02.006>
16. Kuhl V, Eicke BM, Dieterich M, Urban PP. Sonographic analysis of laryngeal elevation during swallowing. *J Neurol*. 2003;250(3):333-7. <http://dx.doi.org/10.1007/s00415-003-1007-2>
17. Söder N, Miller N. Using ultrasound to investigate intrapersonal variability in durational aspects of tongue movement during swallowing. *Dysphagia*. 2002;17(4):288-97. <http://dx.doi.org/10.1007/s00455-002-0071-6>.
18. Kim JH, Kim MS. Lateral pharyngeal wall motion analysis using ultrasonography in stroke patients with dysphagia. *Ultrasound Med Biol*. 2012;38(12):2058-64. <http://dx.doi.org/10.1016/j.ultrasmedbio.2012.07.028>
19. Hsiao MY, Chang YC, Chen HC, Chang HY, Wang TG. Application of ultrasonography in assessing oropharyngeal dysphagia in stroke patients. *Ultrasound Med Biol*. 2012;38(9):1522-8. <http://dx.doi.org/10.1016/j.ultrasmedbio.2012.04.017>
20. Sonies BC, Almajid P, Kleta R, Bernardini I, Gahl WA. Swallowing dysfunction in 101 patients with nephropathic cystinosis: benefit of long-term cysteamine therapy. *Medicine (Baltimore)*. 2005;84(3):137-46.