

CELL PROLIFERATION AND APOPTOSIS IN GASTRIC CANCER AND INTESTINAL METAPLASIA

Nora Manoukian FORONES¹, Ana Paula Souza CARVALHO¹, Oswaldo GIANNOTTI-FILHO², Laércio Gomes LOURENÇO³ and Celina Tizuko Fujiyama OSHIMA²

ABSTRACT – *Background* - Higher proliferation is commonly observed in cancer cells. Apoptosis can be a useful measure of a tumor cell kinetic. Alteration of the balance between proliferation and apoptosis is associated with cancer. *Aim* - To study proliferation and apoptosis in gastric cancer and in intestinal metaplasia. *Methodology* – Twenty-two samples from gastric adenocarcinomas and 22 biopsies from intestinal metaplasia were studied. The apoptotic bodies in hematoxylin-eosin slides and the expression of p53, bcl-2 and Ki67 were determined by immunohistochemistry. *Results* - The number of the apoptotic cells was higher in cancer. Ki 67LI increased from intestinal metaplasia to gastric cancer. p53 was positive in 68% of the patients with cancer, more frequently in advanced stage and negative in samples of intestinal metaplasia. Although there was no significant difference between the groups, bcl-2 was positive in 45% of gastric cancer tissue and in 68% of metaplasia. In gastric cancer patients bcl-2 was expressed in early gastric cancer more frequently than in advanced stage. *Conclusion* - The positivity of bcl-2 was higher in metaplasia and probably is involved in the progression of carcinogenesis. p53 was negative in metaplasia and positive in more than half of the gastric cancer, mostly in stage IV, suggesting a late event in gastric cancer.

HEADINGS – Apoptosis. Protein p53. Proto-oncogene proteins. Proto-oncogene proteins c-Bcl-2. Stomach neoplasms. Metaplasia.

INTRODUCTION

Gastric cancer (GC) is the first most common malignancy of digestive tract in Brazil with 20,640 new diagnosed cases and 11,145 deaths per year⁽¹⁾. Intestinal metaplasia (IM) is considered to be a precancerous lesion of well-differentiated GC. In the attempt to understand the mechanisms of gastric tissue progression to malignancy, the proliferative activity and the apoptosis of the premalignant and neoplastic tissue has been studied extensively.

One characteristic feature of cancer is continuous growth. The rates of cell proliferation and cell death may determine the speed of this growth^(3, 23). The inability of cells to undergo apoptosis may advance cancer development, both by allowing dividing cells to accumulate and by not eliminating genetic mutants that may harbour enhanced malignant potential.

Apoptosis is regulated by a variety of genes, including bcl-2 and p53, which may play an important role to keep the homeostasis of the tissue dynamics⁽²³⁾.

The bcl-2 gene was originally discovered owing to its involvement in the chromosomal translocation t(14;18) occurring in the majority of non-Hodgkin's B-cell lymphomas^(1, 20). This translocation places the bcl-2 gene at chromosomal location 18q21 in juxtaposition with the immunoglobulin heavy-chain locus at 14q32, resulting in transcriptional deregulation of the bcl-2 gene and abnormally high levels of the bcl-2 protein^(9, 21).

The product of the bcl-2 gene is a 26 Kd protein that is known as a inhibitor of apoptosis and it may be considered a “generalized cell death suppressor gene”⁽²⁾. bcl-2 expression is a potential mechanism by which tumor cells escape p53-mediated apoptosis and their expression has been reported for a variety of human epithelial malignant tumors, including carcinomas of the stomach⁽²⁾ and colon⁽¹⁵⁾.

The p53 tumor suppressor gene is mapped on chromosome 17p and plays a role in regulating the cell cycle, DNA repair and synthesis, and programmed cell death^(4, 16, 22). Mutation of p53 leads to disruption of these pathways and resultant selective growth advantage of tumor cells, generally observed during tumor progression. Genetic alterations of p53 are frequently observed in a variety of human cancers including GC, in which they occur on early stage^(5, 19).

Ki-67 is a nuclear proliferation associated antigen expressed in the growth and synthesis phases of the cell cycle (G¹, S, G² and M) but not in the resting phase, G⁰. This antigen provides information about the proportion of active cells in the cell cycle⁽⁷⁾.

Most part of the manuscripts had studied these alterations on cancer tissues. To better understand the carcinogenesis on GC we decided to study these markers also on tissues with IM.

In this study, an immunohistochemical study was performed to examine the apoptotic bodies, the p53, the bcl-2 expression and the cell proliferating rates through the quantification of the Ki-67 in IM and GC tissues.

¹Oncology Group/Gastroenterology Division; ²Pathology Department; ³Surgical Gastroenterology Division - Federal University of Sao Paulo, São Paulo, SP. Address for correspondence: Dr. Nora Manoukian Forones - Universidade Federal de São Paulo - Disciplina de Gastroenterologia Clínica - Rua Botucatu, 740 - 2º andar - 04023-900 - São Paulo, SP, Brazil. Email: nora@gastro.epm.br

METHODOLOGY

Formalin-fixed paraffin embedded samples from 22 gastrectomy specimens from gastric adenocarcinomas and 22 biopsy specimens from IM were studied. The characteristic of these patients was described on Table 1. The diagnosis of IM and GC were determined by examination of hematoxylin-eosin stained (H-E) sections from each case. Pathological and clinical TNM stage was done according to the UICC criteria⁽⁶⁾.

TABLE 1 - Characteristics of the patients studied

		GC	IM	P
Age	Mean	65	64	0.8
Sex	Female	10	13	0.54
	Male	12	9	
Clinical stage	I+II	11	-	
	III+IV	11	-	
bcl-2	Positive	10	15	0.22
	Negative	12	7	
p53	Positive	15	0	0.001
	Negative	7	22	
Ki67	>0.4	17	13	0.4
	<0.4	5	9	

GC = gastric cancer; IM = intestinal metaplasia

Quantification of apoptosis

H-E stained paraffin sections were examined for apoptotic cells and apoptotic bodies. Apoptotic cells were characterized by cell shrinkage, with condensed hyperchromatic nodular, ring-like or beaded nuclear chromatin, and often had deeply eosinophilic cytoplasm surrounded by a clear “halo”. Apoptotic bodies consisted of dense extracellular or intracellular chromatin fragments, with or without associated cytoplasm.

Counts of apoptotic cells and apoptotic bodies were performed using 40x objective. All identified apoptosis in the tissue were counted and the apoptotic index (AI) was defined as the total number of apoptotic cells and apoptotic bodies in at least 500 tumoral cells. Clusters of minute apoptotic bodies within the epithelium were scored as one, and the relatively few apoptotic bodies that were shed into the lumen were not scored because they are likely to persist for an indefinite period of time. Areas of marked lymphocytic infiltration or necrosis were not used for counting.

Immunohistochemistry

Expression of p53, bcl-2 and Ki67 were determined by immunohistochemistry, using avidin-biotin-peroxidase complex staining method.

Sections of 3 µm mounted on 3-aminopropyltrimethoxy-silane (Sigma) coated slides were dewaxed in xylene, taken through ethanol to water to rehydrate. The sections were microwaved in 10 mM sodium citrate buffer (pH 6,0) at 10 min intervals for a total of 20 min. Endogenous peroxidase activity was blocked by incubating the sections in a solution of 3% hydrogen peroxide for 20 minutes at room temperature. After washing in PBS the sections were incubated with the primary monoclonal mouse anti-human human Ki-67, clone MIB-1 (Immunotech) (1:50), monoclonal mouse anti-human p53, clone DO7 (Dako) (1:100), and bcl-2, clone 124 (Dako) (1:80) overnight at 4°C. The sections were washed with

PBS and incubated with a biotinylated secondary antibody for 30 minutes, followed by incubation with streptavidin-biotin-peroxidase complex (Dako) for further 30 minutes, at room temperature. Staining was carried out using a solution 3-3'diaminobenzidine (DAB-Sigma), containing 1% hydrogen peroxide and lightly counterstained with Harris hematoxylin.

Sections known to express high levels of p53, bcl-2 and Ki-67 were included as positive controls, while negative control slides omitted the primary antibody. The sections were judged positive for p53 when 5% or more of the nucleus of tumor cells were stained and for bcl-2 when 10% or more of the cytoplasm of tumor cells were stained.

Ki-67 labelling index was determined by observing 1000 nuclei in areas of the section with the highest labelling rates, and the percentage of Ki-67 labelled nuclei was used for analyses.

Statistical analysis

The significance of associations was determined by the chi-square test or the Fisher's exact test. The *t* Student test was done to compare the levels of the parameters studied between the two groups. The Spearman correlation was done between the markers studied. *P* value <0,05 was considered statistically significant.

RESULTS

Among the 22 patients with cancer, 11 were stage I or II and 11 stage III or IV. Seventeen were of intestinal type and five of diffuse type according to the Lauren's classification.

Careful observation of H-E stained preparations showed a few apoptotic bodies and apoptotic cells in IM and GC (Figures 1, 2). Apoptotic cells showed nuclear condensation and eosinophilic cytoplasm forming a clear halo or fragmentation of the nucleus, corresponding to apoptotic bodies with no predominant localisation within tumor tissue. Occasionally, apoptotic cells were shed into the glandular lumen.

Lymphocytes that infiltrate the gastric epithelium can be differentiated of apoptotic bodies by noting that the cytoplasm of lymphocytes is scanty and not strongly eosinophilic and that the nuclei are hyperchromatic, but their chromatin pattern is still clearly discernible.

The GC tissue has a higher number of apoptotic bodies when compared to the metaplasia intestinal tissue (0.03 ± 0.02 versus 0.02 ± 0.01). This difference was significant (Table 2) (*P*<0,008). The GC tissue and the IM shown nuclear staining for Ki67, with a variable numbers of nuclei in both tissues, ranging from 0.19 to 0.80 (Ki-67LI = 0.43 ± 0.17) for IM and from 0.13 to 0.82 (Ki-67LI = 0.54 ± 0.19) for GC. Ki-67 labelling index (Ki-67LI) was higher in GC (Table 2). AI/Ki-67LI values were similar in the two groups (Table 2).

bcl-2 immunoreactivity was localised in the cytoplasm of GC and IM (Figures 1, 2). No nuclear bcl-2 staining was found in this series of tissues. Small lymphocytes were also very often positive. Sixty-eight percent of IM and in 45% of GC expressed this protein. This difference was not significant.

TABLE 2 - Apoptotic index (AI), Ki-67 labelling index (Ki-67LI) and the quotient AI/Ki67LI in human intestinal metaplasia (IM) and gastric cancer (GC)

	AI	Ki-67LI	AI/Ki-67LI
GC	0.03 ± 0.02	0.54 ± 0.19	0.06
IM	0.02 ± 0.01	0.43 ± 0.17	0.05
<i>P</i>	0.008	0.049	0.17

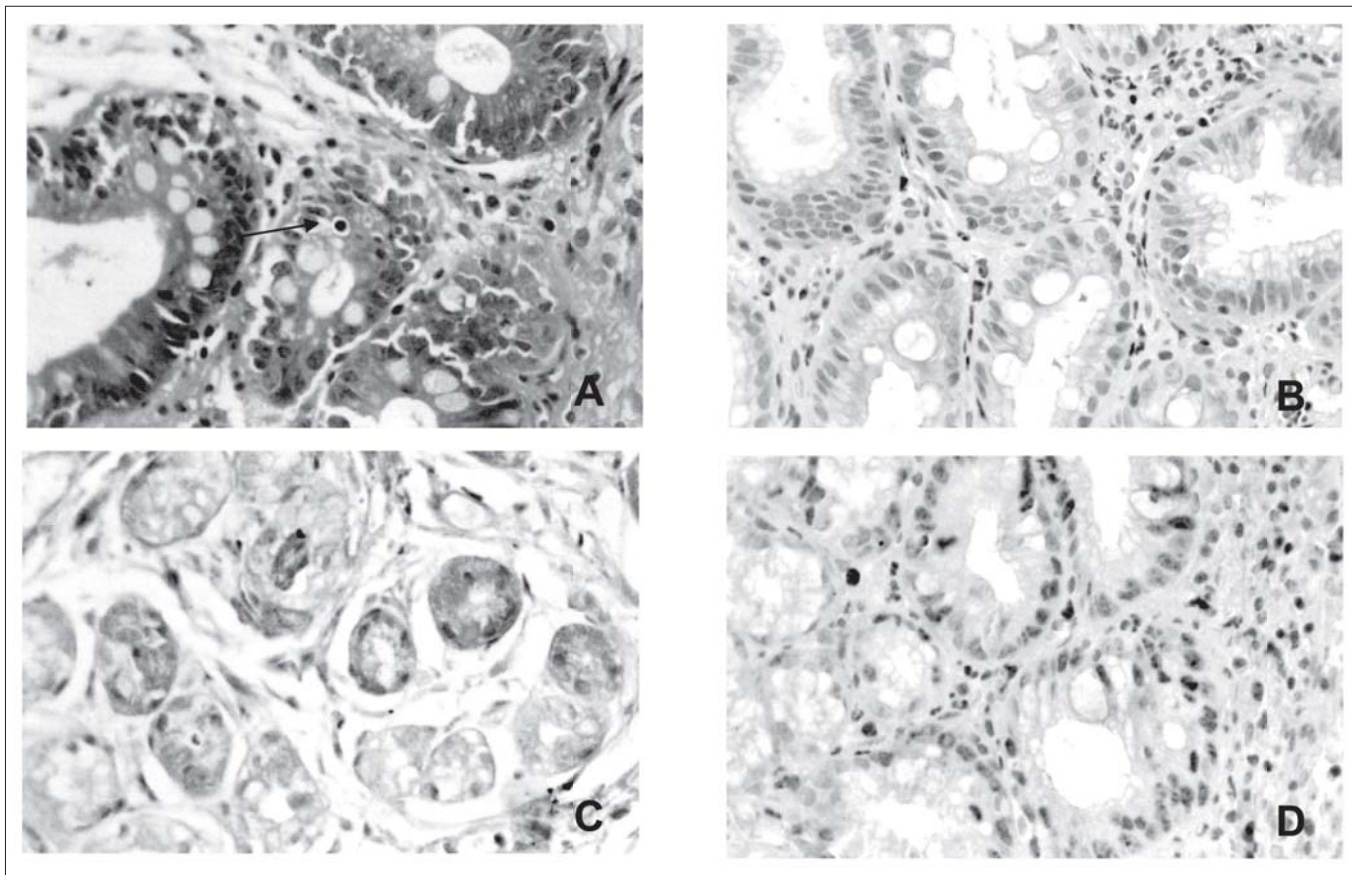


FIGURE 1 - Section of intestinal metaplasia showing: **A** - an apoptotic cells with distinct nuclear condensation and a clear halo, H-E, x400; **B** - an immunohistochemistry for p53 protein; **C** - an immunohistochemistry for Ki-67; **D** - an immunohistochemistry for bcl-2

p53 was negative in all of cases of IM (Figure 1) and positive (Figure 1, 2) in 68% of GC (Table 2). Immunoreactivity for p53 was localised exclusively in the nuclei of positive cells.

Ki67 index and bcl-2 expression was similar in p53 positive or negative tumors. bcl-2 was expressed in all the patients stage I but only in 25% of those stage IV ($P = 0.03$). In the other hand p53 was positive in all the patients stage IV and in 40% of these stage I patients ($P = 0.07$). No difference among the number of apoptosis was observed among these stages.

DISCUSSION

In this study we evaluated the presence of the apoptotic bodies, the Ki67LI, the expression of p53 and bcl-2 in GC tissue and IM, a premalignant lesion.

Cell proliferation is essential in normal cell life and turnover. However, when it is excessive, it potentiates the action of any carcinogen that targets DNA and may lead to a neoplasia. Apoptosis in the other hand, plays an opposite role in human cell populations. Alteration of the balance between proliferation and apoptosis results in a disturbance of tissue homeostasis and is associated with cancer.

Apoptosis is the programmed cell death and was first described by KERR et al.⁽¹⁴⁾. Evaluation of the extent of apoptosis is a potentially useful measure of a tumor cell kinetics and biologic behavior.

Apoptotic bodies have a different morphology from the other cells and can be differentiated from lymphocytic infiltration and from tumor cell necrosis. Apoptotic bodies were observed in GC as well as in IM, but the number of apoptotic cells was higher in the cancer tissue. This indicates that the failure of the apoptotic process leads to an increase survival of cells with DNA damage. The mechanism may be involved in GC growth. ISHIDA et al.⁽¹²⁾ also described a higher number of apoptotic cells in GC when compared to dysplasia. In individuals with normal mucosa, apoptosis seems to be rare and this number increases as the process of multistep carcinogenesis progress from atrophic gastritis, metaplasia intestinal, dysplasia and cancer^(12, 17). When the cancer tissues where compared, advanced GC had lower number of apoptosis^(17, 24). In these assay we did not find differences between the numbers of apoptosis among the stages, probably due to the short number of tissues with cancer studied.

The proliferating index (Ki-76LI) increased from IM to GC. The quotient AI/Ki67 although was higher in the group with GC, this difference was not statistically different.

Apoptosis can occur by the action of p53 at the end of the G1 and G2 phases. Immunohistochemical staining with the monoclonal antibody DO-7 is positive for wild-type p53 as well as for mutant-type p53; however, it is commonly believed that most positive cells

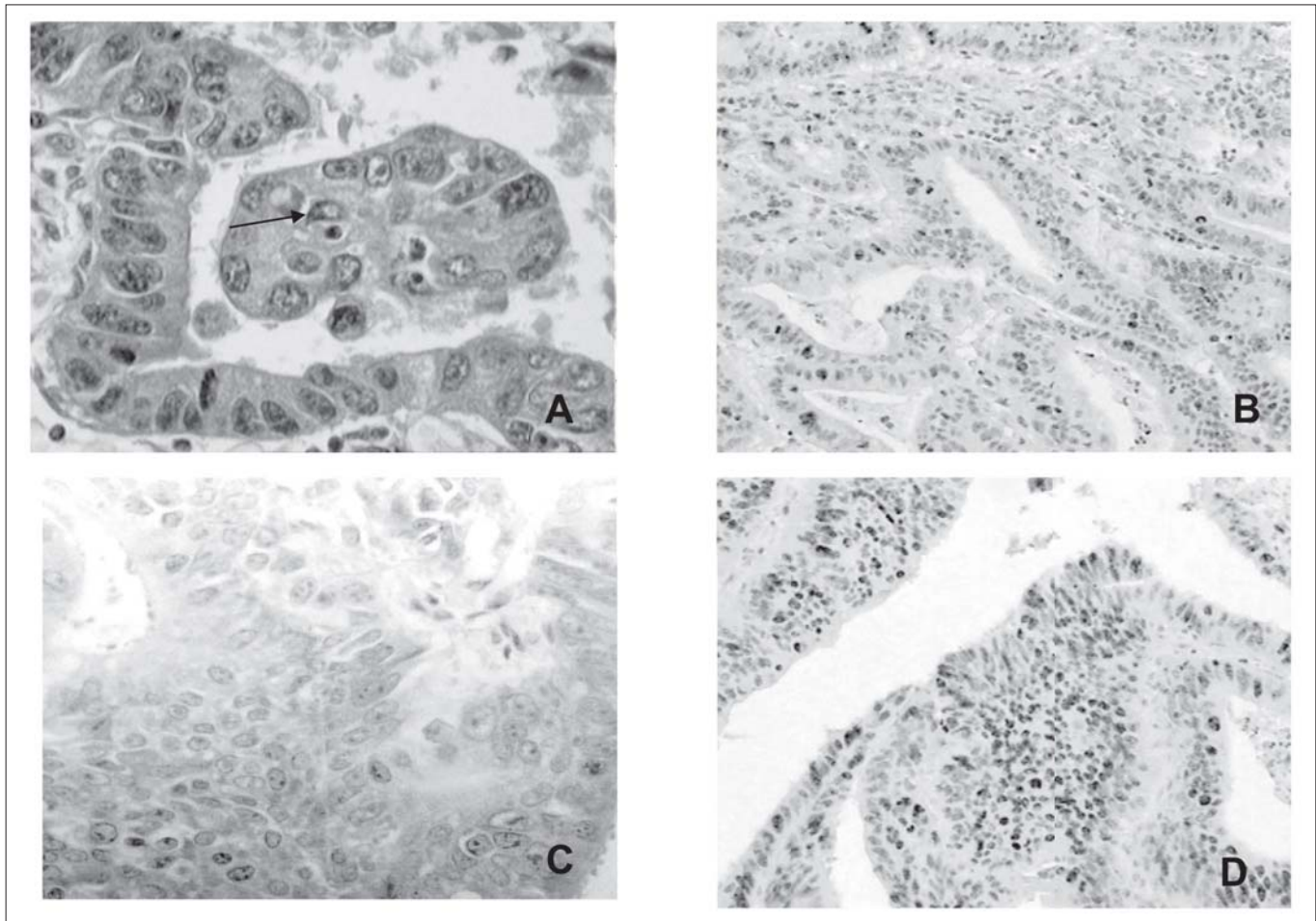


FIGURE 2 - Section of gastric cancer showing: **A** - an apoptotic cells with distinct nuclear condensation and a clear halo, H-E, x400; **B** - an immunohistochemistry for p53 protein; **C** - an immunohistochemistry for Ki-67; **D** - an immunohistochemistry for bcl-2

represent mutant p53, since the half-life of the wild-type p53 protein is very short⁽¹³⁾. p53 was positive in 68% of the patients with GC, more frequently in advanced stage and none of the individuals with metaplasia intestinal. This indicated that the mutation of p53 might be a late event in gastric carcinogenesis. Although most of the GC tissue was positive for p53, the AI was higher in this group than in MI, confirming the hypothesis that apoptosis can be induced via a p53 gene independent pathway⁽²⁴⁾.

bcl-2, a product of the oncogene bcl-2, is expressed in a variety of human cancers, and the apoptosis induced by wild type p53 can be blocked by bcl-2. In the present study, GC and IM tissues demonstrated positive bcl-2 staining. Although there was no significant difference between the groups, the bcl-2 was positive in 45% of the GC tissue and in 68% of the metaplasia. In the GC patients, bcl-2 was expressed in early GC more frequently than in advanced stage. NAKAMURA et al.⁽¹⁷⁾ also observed a high immunoreactivity for bcl-2 (77%) in MI, and a lower percentage in GC (11%). Others authors⁽²⁴⁾ published a higher percentage of bcl-2 in early GC when compared to the advanced GC. Some studies observed that bcl-2 was negative in normal gastric mucosa, increase in metaplasia and

decrease in GC^(12, 17). The aberrant expression of bcl-2 protein may be associated with the early process⁽¹⁰⁾ of the carcinogenic sequence before other carcinogenic events such mutation of p53 was acquired. Perhaps the increased expression of bcl-2 in IM allows prolonged cell survival that allows for persistence and possible progression of a pre-malignant by accumulating genetic abnormalities. Although bcl-2 was a strong inhibitor of apoptosis, it probably could not induce the cancer alone.

Some investigators showed an inverse relationship between p53 and bcl-2 expression in non-Hodgkin's lymphoma⁽¹⁸⁾, breast carcinoma⁽⁸⁾. In this study we also observed an inverse, but not significant correlation.

CONCLUSION

The apoptotic index and the proliferating index Ki67 increased from IM to GC. The positivity of bcl-2 was higher in the metaplasia and probably is involved in the progression of carcinogenesis. The p53 was negative in metaplasia and positive in GC, mostly in stage IV, suggesting a late event in this cancer.

Forones NM, Carvalho APS, Giannotti-Filho O, Lourenço LG, Oshima CTF. Proliferação celular e apoptose em câncer gástrico e metaplasia intestinal. *Arq Gastroenterol* 2005;42(1):30-4.

RESUMO – Racional – O aumento da proliferação celular é comumente observado no câncer e a apoptose pode ser medida útil na avaliação da cinética celular do tumor. Alterações do equilíbrio entre proliferação celular e apoptose estão associadas ao câncer. **Objetivo** – Avaliar a proliferação celular e a apoptose no câncer gástrico e na metaplasia intestinal. **Casuística e Métodos** – Vinte e dois tecidos de adenocarcinoma gástrico e 22 biópsias de metaplasia intestinal foram estudados. Os corpos apoptóticos foram estudados em lâminas coradas pela hematoxilina-eosina e a expressão de p53, bcl-2 e Ki67 por imunistoquímica. **Resultados** – O número de corpos apoptóticos foi maior no câncer. O Ki67LI aumentou no câncer gástrico em relação ao tecido com metaplasia intestinal. O p53 foi positivo em 68% dos pacientes com câncer, principalmente nos tumores avançados e negativo nos indivíduos com metaplasia intestinal. O bcl-2 foi expresso em 45% dos tecidos com câncer gástrico e em 68% dos tecidos com metaplasia, no entanto, esta diferença não foi significativa. Nos doentes com câncer gástrico precoce, o bcl-2 foi expresso com maior frequência quando comparados aos com câncer em estágio avançado. **Conclusão** – A expressão do bcl-2 foi maior no tecido com metaplasia, sugerindo envolvimento desta proteína na evolução da carcinogênese. O p53 foi negativo nos tecidos com metaplasia intestinal e positivo em 50% dos tecidos tumorais, principalmente nos doentes com câncer estágio IV, sugerindo ser um evento tardio no câncer gástrico.

DESCRITORES – Apoptose. Proteína p53. Proteínas proto-oncogênicas. Proteínas proto-oncogênicas c-Bcl-2. Neoplasias gástricas. Metaplasia.

REFERENCES

- Aisemberg AC, Wilkes BM, Jacobson JO. The bcl-2 gene is rearranged in many diffuse B-cell lymphomas. *Blood* 1988;71:969-72.
- Aizawa K, Ueki K, Suzuki S, Yabusaki H, Kanda T, Nishimaki T, Suzuki T, Hatakeyama K. Apoptosis and Bcl-2 expression in gastric carcinomas: correlation with clinicopathological variables, p53 expression, cell proliferation and prognosis. *Int J Oncol* 1999;14:85-91.
- Carlson DA, Ribeiro JM. Apoptosis and disease. *Lancet* 1993;341:1251-4.
- Cho J-H, Kim WH. Altered topographic expression of p21^{WAF1/CIP1/Sdi1}, bcl-2 and p53 during gastric carcinogenesis. *Pathol Res Pract* 1998;194:309-17.
- Feng CW, Wang LD, Jiao LH, Liu B, Zheng S, Xie XJ. Expression of p53, inducible nitric oxide synthase and vascular endothelial growth factor in gastric precancerous and cancerous lesions: correlation with clinical features. *BMC Cancer* 2002;2:8.
- Forones NM, Gil JZ, Lourenço LG. Câncer gástrico. In: Forones NM, Jesus-Garcia FO, Tadokoro H, Freire CAR, editores. *Guia de medicina ambulatorial e hospitalar da UNIFESP em oncologia*. São Paulo: Manole; 2004. p.99-106.
- Gerdes J, Li L, Schlueter C, Duchrow M, Wohlenberg C, Gerlach C, Stahmer I, Kloth S, Brandt E, Flad HD. Immunobiochemical and molecular biologic characterization of the cell proliferation-associated nuclear antigen that is defined by monoclonal antibody Ki-67. *Am J Pathol* 1991;138:867-73.
- Gorczyca W, Markiewski M, Kram A, Tuziak T, Domagala W. Immunohistochemical analysis of bcl-2 and p53 expression in breast carcinomas: their correlation with Ki-67 growth fraction. *Virchows Arch* 1995;426:229-33.
- Hockenbery D, Nuñez G, Millman C, Schreiber RD, Korsmeyer SJ. Bcl-2 is an inner mitochondrial membrane protein that blocks programmed cell-death. *Nature* 1990;348:334-6.
- Ikeda M, Shomori K, Endo K, Makino T, Matsuura T, Ito H. Frequent occurrence of apoptosis is an early event in the oncogenesis of human gastric carcinoma. *Virchows Arch* 1998;432:43-7.
- INCA – Instituto Nacional do Câncer, Rio de Janeiro. Estimative of incidence and mortality of cancer in Brasil, 2003 [homepage on the Internet]. Available from: <http://www.inca.org/>.
- Ishida M, Gomyo Y, Tatebe S, Ohfuji S, Ito H. Apoptosis in human gastric mucosa, chronic gastritis, dysplasia, and carcinoma analysis by terminal deoxynucleotidyl transferase mediated dUTP biotin nick end labelling. *Virchows Arch* 1996;428:229-35.
- Ito H. p53 gene and apoptosis in human gastric carcinomas. *Rec Adv Gastroenterol Carcinogen* 1996;1:99-106.
- Kerr JFR, Wyllie AH, Currie AR. Apoptosis: a basic biological phenomenon with wide ranging implications in tissue kinetics. *Br J Cancer* 1972;26:239-57.
- Leahy DT, Mulcahy HE, O'Donoghue DP, Parfrey NA. Bcl-2 protein expression is associated with better prognosis in colorectal cancer. *Histopathology* 1999;35:360-7.
- Marx J. How p53 suppresses cell growth. *Science* 1993;262:1644-5.
- Nakamura T, Nomura S, Skai T. Expression of Bcl-2 and p53 oncoprotein in gastrointestinal and uterine carcinomas and their premalignant lesions. *Human Pathol* 1997;28:309-15.
- Pezzella F, Morrison H, Jones M, Gatter KC, Lane D, Harris AL, Mason DY. Immunohistochemical detection of p53 and bcl-2 proteins in non-Hodgkin's lymphoma. *Histopathology* 1993;22:39-44.
- Rajnakova A, Mochhala S, Goh PM, Ngoi S. Expression of nitric oxide synthase, cyclooxygenase, and p53 in different stages of human gastric cancer. *Cancer Lett* 2001;172:177-85.
- Tsujimoto Y, Croce CM. Analysis of the structure, transcripts and protein products of bcl-2, the gene involved in human follicular lymphoma. *Proc Natl Acad Sci U S A* 1986;83:5214-8.
- Tsujimoto Y, Ikegaki N, Croce CM. Characterization of the protein product of bcl-2, the gene involved in human follicular lymphoma. *Oncogene* 1987;2:3-7.
- Vogelstein B, Kinzler KW. p53 function and dysfunction. *Cell* 1992;70:523-6.
- Wyllie AH. Apoptosis and the regulation of cell numbers in normal and neoplastic tissues: an overview. *Cancer Metastasis Rev* 1992;11:95-103.
- Xu NG, Li SG, Liu JH, Gan AH. Function of apoptosis and expression of the proteins Bcl-2, p53 and C-myc in the development of gastric cancer. *World J Gastroenterol* 2001;7:403-6.

Recebido em 15/7/2004.
Aprovado em 11/11/2004.