

Short-term results of minimally invasive treatment of gastroesophageal reflux disease by radiofrequency (Stretta): first Brazilian series of cases

Thiago Ferreira de SOUZA^{1,2}, Eduardo GRECCO^{1,2}, Luiz Gustavo de QUADROS²,
Yael Duarte de ALBUQUERQUE¹, Fernanda Oliveira AZÔR³ and Manoel GALVÃO NETO^{1,2}

Received 8/10/2018
Accepted 25/10/2018

ABSTRACT – Background – New endoscopic treatments for gastroesophageal reflux (GERD) are developed every year and are indicated in cases that are refractory to conventional therapies as well as after surgical treatment failure. **Objective** – To present the first cases of endoscopic therapy for GERD performed in Brazil. **Methods** – Use of radiofrequency with the Stretta procedure in symptomatic volunteers diagnosed with GERD. **Results**: The technique was performed in three patients after they were included in the study protocol. No patient had complications, and all patients were discharged on the same day, either without medication or taking it sporadically for symptom control. **Conclusion** – Endoscopic treatment for GERD using radiofrequency was effective in the cases presented herein with no technical complications.

HEADINGS – Endoscopy. Gastroesophageal reflux. Radio waves, therapeutic use.

INTRODUCTION

Gastroesophageal reflux disease (GERD) has a worldwide prevalence ranging between 8% and 33% and affects all age groups and genders. In the United States alone, the annual spending on diagnosing and treating the disease exceeds 9 billion dollars⁽¹⁾.

According to the Montreal Conference consensus, GERD is defined as a disease that develops when the reflux of gastric acid causes unpleasant symptoms and/or complications. It may be attributable to anatomical or physiological defects of the gastroesophageal junction (GEJ) or to altered esophageal peristalsis, and it causes typical or atypical symptoms that negatively affect the quality of life of the individual⁽¹⁻³⁾.

The diagnosis of GERD is primarily clinical, and empirical treatment is endorsed by several associations. Diagnostic tests are used in cases of treatment failure or uncertain diagnoses⁽¹⁾. The most widespread initial approach is the use of proton pump inhibitors (PPIs), alone or in combination with prokinetics, with concomitant changes in eating habits and lifestyle. However, even with adequate treatment, 20% to 40% of cases are refractory to treatment with medications, and the effect of drugs is reduced in patients with atypical symptoms⁽³⁾.

Minimally invasive procedures have emerged as a “bridge” between therapy with medications and surgical treatment, which is considered the gold standard in cases involving an anatomical defect. The Stretta procedure involves the delivery of radiofrequency (RF) energy to the GEJ with the aim of improving the tonicity of

the lower esophageal sphincter (LES) and reducing the number of episodes of transient relaxation.

Although there is a wide range of patients who may benefit from the method the use of radiofrequency does not have the capacity to treat anatomical defects and is not indicated in patients with complicated GERD such as active ulcers and stenoses. Complications related to this endoscopic method are rare, however, perforation is the most feared complication. No deaths were reported with this technique. The objective of the present study was to report the initial experience (first three cases) of the Stretta procedure in Brazil in terms of the results and applicability of the technique.

METHODS

The study describes the first three cases of endoscopic treatment of reflux by Stretta RF performed at the State Hospital of the School of Medicine of the ABC, in Santo André, Brazil, in September 2017. The study was approved by the ethics committee (under number 2.334.962), and all patients gave their written informed consent before being included in the study.

Three patients were selected who had a history of GERD and complaints of heartburn and regurgitation for more than six months and were using a full dose of a PPI, but whose clinical condition had not improved or had improved only partially.

All patients underwent initial 24-hour dual-channel pH monitoring and conventional esophageal manometry. The manometry results showed hypotonia of the LES but no changes in esophageal

Declared conflict of interest of all authors: none

Disclosure of funding: no funding received

¹ Instituto Endovitta, São Paulo, SP, Brasil. ² Faculdade de Medicina do ABC, Santo André, SP, Brasil. ³ Kaiser Hospital Dia, São José do Rio Preto, SP, Brasil.

Research performed at: Faculdade de Medicina do ABC, Departamento de Endoscopia, Santo André, SP, Brasil.

Corresponding author: Luiz Gustavo de Quadros. Orcid: 0000-0001-9586-8109. E-mail: gustavo_quadros@hotmail.com

body motility or upper esophageal sphincter relaxation. The De-Meester score on pH monitoring was greater than 14.7 in all patients, with one patient exhibiting pathological proximal acid reflux.

TECHNIQUE

The procedures were performed in a surgical center under general anesthesia with orotracheal intubation. First, endoscopy is performed to locate and measure the gastroesophageal transition zone, and then a guidewire is passed into the stomach. At the end of the catheter, there is an inflatable balloon with four retractable titanium-coated needle electrodes that deliver the RF (FIGURE 1). The catheter is coupled to an RF generator that tightly controls the temperature of the electrodes, dissipating heat when necessary to avoid thermal injury (FIGURE 2). The system also has suction and irrigation lines for cooling during the procedure. Double-distilled water is used in the process. After adequate measurement of the gastroesophageal transition zone, the data on its position are stored in the generator, which then controls all the steps of the process.

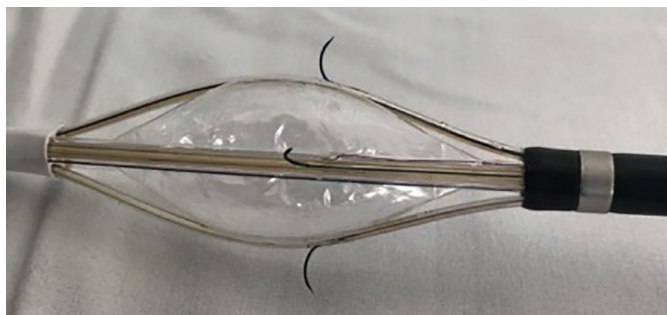


FIGURE 1. Stretta catheter.

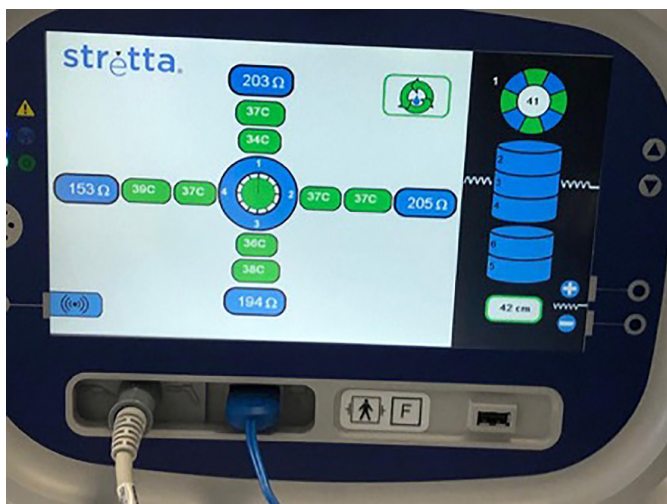

FIGURE 2. Generator of radiofrequency.

The balloon is positioned 1 cm above the Z line and is inflated to 25 mL, the needles are deployed within the tissue, and the first command is given by depressing a foot pedal. Each RF treatment lasts approximately 60-90 seconds. After RF is delivered at each level, the needles are withdrawn, and the balloon is deflated. The catheter is then rotated 45 degrees clockwise at the same level and the process is repeated to complete the first cycle of treatment. This

procedure is repeated systematically every 0.5 cm in the direction of the Z line and at its level. After completion of the esophageal treatment, the catheter is advanced into the stomach and the balloon is inflated to 25 mL and pulled against the cardia for additional cycles of RF, now with two more 30-degree rotations. These steps are repeated by inflating the balloon to 20 mL. Upon completion of this procedure, an additional upper endoscopy is performed to exclude complications and assess the created lesions (FIGURES 3 and 4). In the three cases presented below, postoperative control exams were not performed due to the short follow-up time.

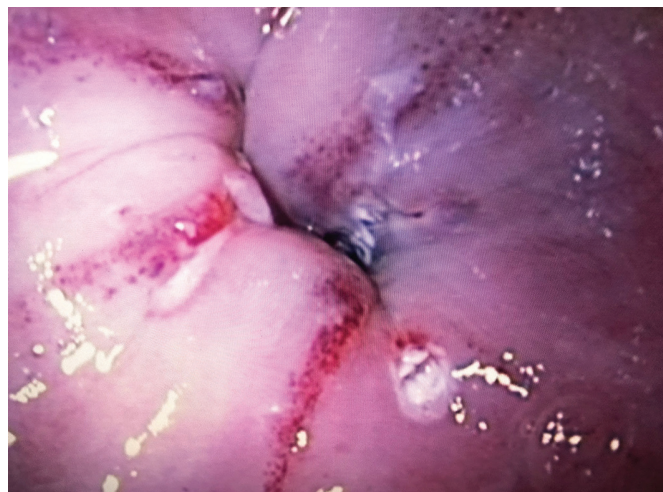

FIGURE 3. Endoscopic view of esophagus post procedure.

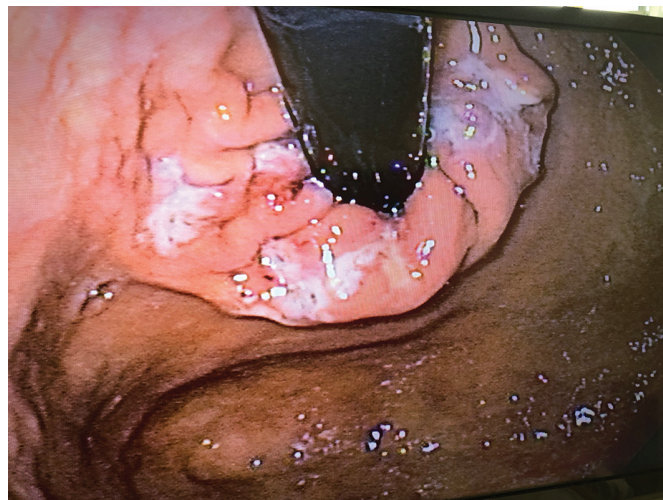

FIGURE 4. Retroflex vision of gastric junction post procedure.

RESULTS

Case 1: A 46-year-old man with a diagnosis of GERD made six years previously who was undergoing treatment with full-dose PPI with only partial improvement of symptoms. After endoscopic treatment, which was performed without complications, he was on a soft diet for 15 days and on full-dose PPI for 90 days. He progressed to mild dysphagia in the first week, after which the symptoms subsequently decreased. He stopped using PPI after the first three months and remained asymptomatic thereafter.

Case 2: A 34-year-old man with typical symptoms of GERD for two years without improvement after the use of PPI, even at a full dose. After undergoing Stretta RF, he progressed without pain and with mild discomfort for five days. He took full-dose PPI for three months, and although drug discontinuation was attempted, the reflux symptoms persisted (which he reported to be milder than before the discontinuation of PPI). He remained asymptomatic with a 20-mg dose of esomeprazole and currently takes the medication sporadically.

Case 3: A 63-year-old man with atypical symptoms of reflux (chronic cough) and a diagnosis of GERD by pH monitoring; respiratory disease was excluded as the cause of the symptoms. He exhibited symptom improvement with the use of PPI (40 mg of esomeprazole every 12 hours) but wished to reduce or discontinue the use of daily medication. After endoscopic treatment, he progressed without complaints; after three months of using PPI daily, the dose was reduced until it was discontinued. He currently takes the medication sporadically when ingesting certain liquids.

DISCUSSION

Although this study shows just a small number of patients and in a short term of follow-up, we presented the firsts cases of GERD treatment performed using radiofrequency in Brazil. Currently, around 200 procedures have already been carried out in our country.

The treatment for GERD includes a wide range of management strategies, from lifestyle changes to pharmacological, endoscopic, and surgical interventions^(4,5,6). When patients with GERD have persistent symptoms that are not controlled with drugs or when they are responders who do not wish to keep taking medication on a daily basis, the Stretta procedure is an alternative to surgery and implants. Since it is a non-surgical procedure that is performed in an outpatient setting, patients can return to their normal activities a few days after the procedure⁽⁷⁾.

Treatment failure has become one of the most common presentations of GERD encountered by gastroenterologists⁽²⁾, with up to 20% of patients unable to achieve total control of the symptoms despite the use of PPIs.

Nissen fundoplication is considered the gold standard invasive treatment for GERD, as it restores the antireflux barrier and improves the quality of life. It is indicated for non-responders to PPIs, atypical symptoms, large hiatal hernias, and complications such as stenosis and Barrett's esophagus; however, patients may develop other complications from the surgical treatment.

The use of RF in the treatment of GERD was approved by the FDA in 2000. The procedure involves the delivery of RF energy to several sites along the GEJ, inducing hypertrophy and thereby increasing the tone of the LES^(3,8).

Two mechanisms may explain the results obtained with the use of the Stretta procedure: improvement of GEJ tone through the retraction and deposition of collagen at the lesion sites and the neurolysis of fibers afferent to the GEJ that are responsible for the transient relaxation of the LES, which may reduce the episodes of transient sphincter relaxation and affect the fibers responsible for heartburn complaints⁽⁹⁻¹³⁾.

Previous studies have shown that the Stretta procedure improves reflux symptoms and quality of life, reduces or eliminates the use of medications, and reduces exposure to acid. In addition, more than 40 clinical studies have shown that the Stretta procedure is safe and effective, with long-lasting results⁽⁹⁾.

Noar et al.⁽⁹⁾ prospectively evaluated 18 patients refractory to previous fundoplication and 81 patients with GERD refractory to the standard treatment. They all underwent therapy with the Stretta procedure during the 10-year follow-up period. Endoscopic treatment resulted in sustained improvement, with results similar to those obtained with the standard nonsurgical treatment. Moreover, patients refractory to surgery have the possibility to undergo a different treatment via endoscopy that is safe and effective, with fewer complications compared to undergoing another surgical procedure. In a systematic review with meta-analysis, FASS et al. demonstrated that RF treatment reduced the incidence of erosive esophagitis by 24% ($P < 0.001$); however, there was a non-statistically significant increase in LES basal pressure⁽¹⁰⁾.

CONCLUSION

The pilot procedures of the first protocol of studies conducted in Brazil produced satisfactory results, similar to those reported in the literature, with discontinuation or reduction in the daily use of medications and improvement of the typical and atypical symptoms of GERD.

Authors' contribution

Souza TF, Grecco E: data collect, revision of the manuscript. Quadros LG: manuscript writing, final approval. Albuquerque YD: revision of the manuscript. Azôr FO: manuscript writing. Galvão Neto M: orientation, revision of the manuscript, final approval.

Souza TF, Grecco E, Quadros LG, Albuquerque YD, Azôr FO, Galvão Neto M. Tratamento endoscópico da doença do refluxo gastroesofágico com uso de radiofrequência (Stretta): resultados a curto prazo da primeira série de casos brasileira. Arq Gastroenterol.

RESUMO – Contexto – Novos tratamentos endoscópicos para refluxo gastroesofágico são desenvolvidos a cada ano, sendo indicados em casos refratários às terapias convencionais, bem como após a falha do tratamento cirúrgico. **Objetivo** – Apresentar os primeiros casos de terapia endoscópica para tratamento do refluxo gastroesofágico realizado no Brasil. **Métodos** – Uso de radiofrequência com o procedimento de Stretta em voluntários sintomáticos e diagnosticados com DRGE. **Resultados** – A técnica foi realizada em três pacientes depois de terem sido incluídos no protocolo de estudo. Nenhum paciente teve complicações, e todos receberam alta hospitalar no mesmo dia, mantendo-se sem medicação ou fazendo uso esporádico para o controle de sintomas. **Conclusão** – Tratamento endoscópico para doença do refluxo gastroesofágico com uso de radiofrequência foi eficaz nos casos aqui apresentados e sem complicações técnicas.

DESCRIPTORIOS – Endoscopia. Refluxo gastroesofágico. Ondas de rádio, uso terapêutico.

REFERENCES

1. Gyawali, C Prakash, Kahrilas PJ, Savarino E, Zerbib F, Mion F, Smout AJPM, et al. Modern diagnosis of GERD: the Lyon Consensus. *Gut*. 2018;67:1351-62.
2. Triadafilopoulos G. Stretta: a valuable endoscopic treatment modality for gastroesophageal reflux disease. *World J Gastroenterol*. 2014;20:7730-8.
3. Nicolau AE, Loboñiu A, Constantinoiu S. New Minimally Invasive Endoscopic and Surgical Therapies for Gastroesophageal Reflux Disease (GERD). *Chirurgia (Bucur)*. 2018;113:70-82.
4. Noar M, Squires P, Khan S. Radiofrequency energy delivery to the lower esophageal sphincter improves gastroesophageal reflux patient-reported outcomes in failed laparoscopic Nissen fundoplication cohort. *Surg Endosc*. 2017;31:2854-62.
5. Liu HF, Zhang JG, Li J, Chen XG, Wang WA. Improvement of clinical parameters in patients with gastroesophageal reflux disease after radiofrequency energy delivery. *World J Gastroenterol*. 2011;17:4429-33.
6. Kethman W, Hawn M. New Approaches to Gastroesophageal Reflux Disease. *J Gastrointest Surg*. 2017;21:1544-52.
7. Maradey-Romero C, Fass R. New and future drug development for gastroesophageal reflux disease. *J Neurogastroenterol Motil*. 2014;20:6-16.
8. Perry KA, Banerjee A, and Melvin WS. Radiofrequency energy delivery to the lower esophageal sphincter reduces esophageal acid exposure and improves GERD symptoms: a systematic review and meta-analysis. *Surg Laparosc Endosc Percutan Tech*. 2012;22:283-8.
9. Fass R, Cahn F, Scotti DJ, Gregory DA. Systematic review and meta-analysis of controlled and prospective cohort efficacy studies of endoscopic radiofrequency for treatment of gastroesophageal reflux disease. *Surg Endosc*. 2017;31:4865-82.
10. van Pinxteren B, Sigterman KE, Bonis P, Lau J, Numans ME. Short-term treatment with proton pump inhibitors, H2-receptor antagonists and prokinetics for gastro-oesophageal reflux disease-like symptoms and endoscopy negative reflux disease. *Cochrane Database Syst Rev*. 2010;(11):CD002095
11. Noar M, Squires P, Khan S. Radiofrequency energy delivery to the lower esophageal sphincter improves gastroesophageal reflux patient-reported outcomes in failed laparoscopic Nissen fundoplication cohort. *Surg Endosc*. 2017;31:2854-62.
12. Utley DS. The Stretta procedure: device, technique, and preclinical study data. *Gastrointest Endosc Clin N Am*. 2003;13:135-45.
13. Herman, DRM, Wojtysiak, R. Jansuz, et al. Interstitial Cells of Cajal (ICC) and Smooth Muscle Actin (SMA) activity after non-ablative radiofrequency energy application to the Internal Anal Sphincter (IAS). In Poster Presentation at Digestive Disease Week Conference, 2013.