

# A NEW TREATMENT FOR LARGE CEREBRAL PARACOCCIDIOIDOMYCOSIS

CARLOS A. M. GUERREIRO \*

SANDRA S. D. CHULUC \*\*

MARIA L. N. BRANCHINI \*

Surgical treatment and/or amphotericin B have been the treatment of choice for cerebral infections caused by the fungus *Paracoccidioides brasiliensis*<sup>1,3,6,7,8,9,11,12,13,15,17</sup>. We are reporting a new drug treatment for the encephalic form of paracoccidioidomycosis. *P. brasiliensis*, the agent of a deep fungal infection highly endemic in Central and South America, has been associated with two types of CNS lesions: granuloma reaction in the meninges, frequently causing a basilar leptomeningitis similar to tuberculous meningitis; solitary and multiple granulomas, most commonly localized in cerebral hemispheres<sup>11</sup>.

We report a patient with a large granuloma of South American blastomycosis in the right fronto-parietal region, successfully treated with sulfamethoxazole-trimethoprim alone, with follow-up documented by repeated CT scans.

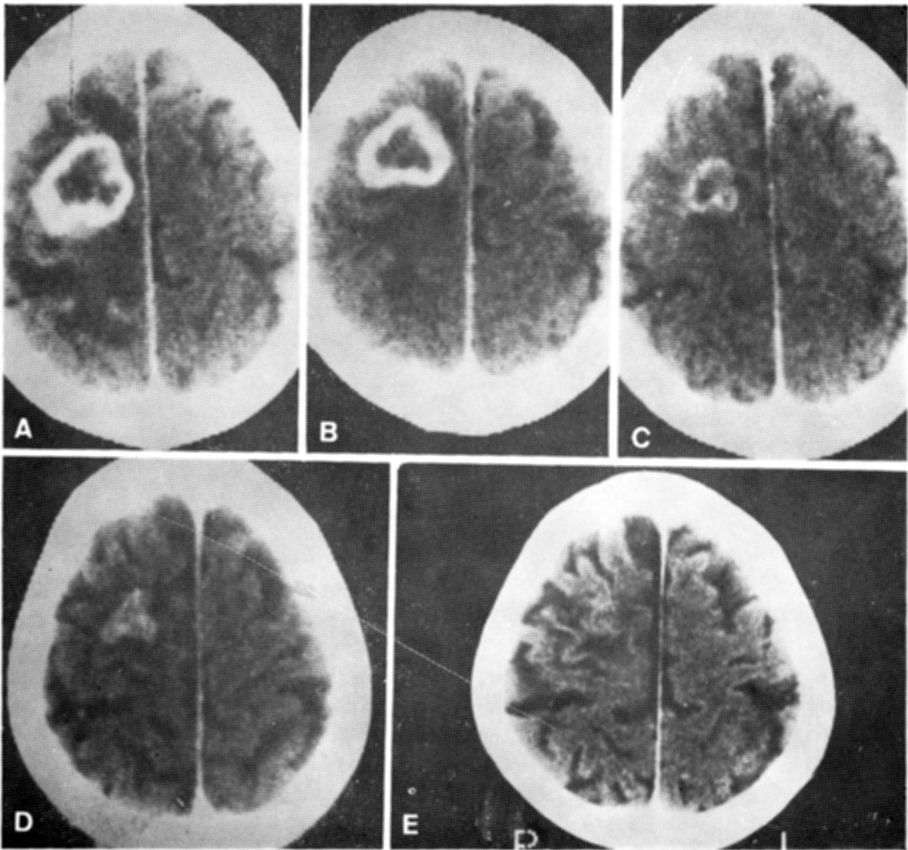
## CASE REPORT

A.M.S., a 59-year-old Brazilian male, truck driver, was admitted to the University of Campinas Hospital because of partial motor seizures starting in the left extremities and progressing to generalized tonic-clonic movements, beginning four months before, associated with a two months history of left progressive hemiparesis. He had been smoking a pack of cigarettes per day since age nine and had abused alcohol up to eight months before admission. Physical examination disclosed discretely pale mucous membranes, distant breath sounds and mild hepatomegaly. The neurologic examination showed a severe left hemiparesis predominating in the upper extremity, suggesting a supratentorial lesion; funduscopic examination and mental status were normal. CBC showed mild normocytic anemia and increased sedimentation rate. Skull X-ray, EEG and CSF were normal. A cranial CT (Fig 1 A) revealed a large hypodense area in the right fronto-parietal region extending up to the cortex; contrast injection enhanced the central area and ring-like pattern. A chest X-ray showed bilateral diffuse pulmonary infiltrates, more prominent in the parahilar regions, consistent with pulmonary paracoccidioidomycosis (Fig. 2). Sputum smears revealed the presence of *Paracoccidioides brasiliensis*. Treatment was started 1200 mg of sulfamethoxazole, plus 240 mg of trimethoprim twice a day. The seizures were controlled with phenobarbital 100 mg per day. One week after initiation of treatment with sulfamethoxazole-trimethoprim a definite improvement of the left hemiparesis was noted. After the first month, clinical improvement was remarkable but the contrasted CT scan (Fig 1 B) still showed the lesion, although there was evidence

---

Department of Neurology, University of Campinas, Brazil: \* Assistant Professor; \*\* Resident. *Acknowledgement*: The authors are indebted to Milton Medeiros, M.D. who helped with the English revision.

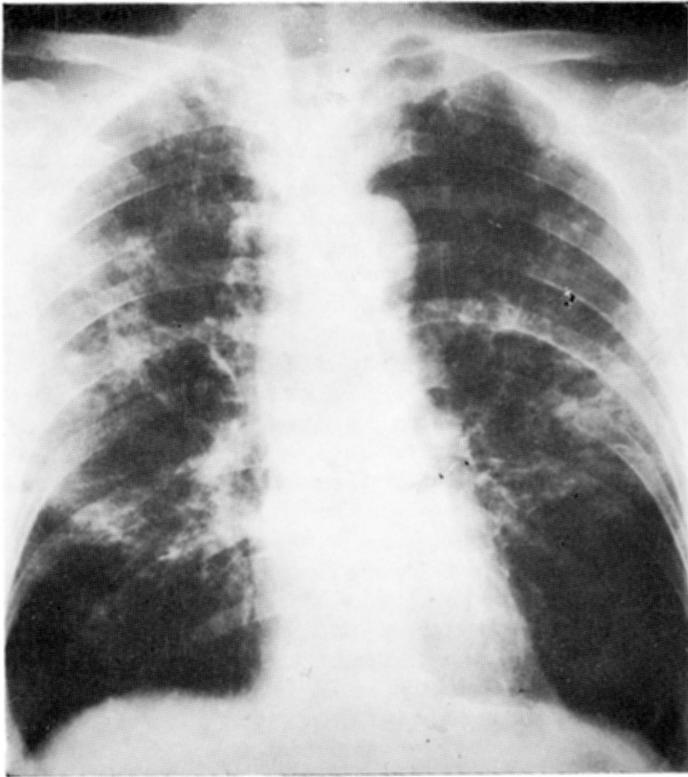
of less edema. After six months, the neurological recovery was almost complete, there remaining a mild disability with fine movements of the left fingers. After twelve months of treatment, the dosage was decreased to 800 mg of sulfamethoxazole and 160 mg trimethoprim twice a day, and this dosage was kept for the remainder of the twenty-six months follow-up. CT's were repeated at eight, seventeen and twenty-six months of treatment (Fig 1C, 1D, and 1E). The patient was kept on the same drug schedule and we followed him up for twenty-six months.



*Fig. 1 — Contrast-enhanced CT scans showing the lesion before (1 A) and after one (1 B), eight (1 C), seventeen (1 D) and twenty-six months (1 E) of treatment.*

#### COMMENTS

CNS involvement by paracoccidioidomycosis has been described since 1919<sup>10</sup>. The prevalence of neurological complication varies from 9,6%<sup>11</sup> to 12,5%<sup>4</sup>. Pathological studies revealed few cases without systemic lesions. Pereira et al. reported the following frequency of lesions: lungs 64,29%; lymph nodes 50%; adrenals 37,7%; skin and larynx 28,5%; mouth and pharynx 21,42%<sup>11</sup>. The EEG is normal in most cases, probably due to the chronicity of the lesions. Skull X-ray are usually normal, except when there is bone involvement<sup>5</sup>. The CSF is normal or reveals a nonspecific abnormality, such as pleocytosis and increased proteins and gamma-globulin. It is unusual to find the fungus in the



*Fig. 2 — Chest X-ray showing the parahilar involvement typical of the pulmonary paracoccidioidomycosis.*

CSF 8,12,14. CT scans may show pathology even in asymptomatic cases 4,7, usually a cystic lesion which must be differentiated from a tumor or an abscess 8,9,16.

The drugs most frequently used to treat South American blastomycosis are amphotericin B, the sulfonamides and ketoconazole. In severe neurological forms of this disease, surgical treatment and/or amphotericin B have considered the first choice therapy; sulfonamides are used to prevent relapses. The drug treatment we used in the reported case was proposed by Barbosa and Daher<sup>2</sup> for systemic forms of the disease.

Another patient with a paracoccidioidomycotic cerebellar granuloma was submitted to the same treatment, with good results. Unfortunately, the follow-up was not documented enough to be reported.

#### SUMMARY

A patient with a large paracoccidioid granuloma in the right fronto-parietal region was treated with sulfamethoxazole-trimethoprim alone, without the use of amphotericin B or any surgical measures. The authors stress the excellent therapeutic results through a twenty-six month follow-up, documented by repeated CT scans.

## RESUMO

*Novo tratamento para extenso granuloma paracoccidioidomicótico cerebral.*

Um paciente de 59 anos com grande granuloma paracoccidioidomicótico na região fronto-parietal direita submetido a tratamento com sulfametoxazol-trimetoprim apenas é apresentado. O paciente foi internado com história de crises epiléticas parciais motoras à esquerda secundariamente generalizadas há 4 meses, associadas a progressiva hemiparesia esquerda há 2 meses. O exame físico mostrou discreto descoramento da mucosa, diminuição de murmúrio vesicular e leve hepatomegalia. O exame neurológico revelou hemiparesia esquerda completa, predominando em membros superior, RX de crânio, exame do LCR e EEG mostraram-se normais. Tomografia computadorizada revelou grande área hipodensa na região fronto-parietal direita estendendo-se até o córtex; injeção do contraste acentuou a área central e mostrou formação de um anel ao redor da lesão. RX de tórax mostrou infiltrado pulmonar difuso e bilateral, mais proeminente nas regiões para-hilares, consistente com paracoccidioidomicose pulmonar. Exame do escarro mostrou a presença do *Paracoccidioides brasiliensis*. As crises epiléticas foram controladas com 100 mg de fenobarbital. Foi iniciado tratamento com 1200 mg de sulfametoxazole mais 240 mg de trimetoprim duas vezes ao dia. Uma semana após o início do tratamento começou a melhora da hemiparesia. Os controles tomográficos evidenciaram a regressão da lesão. Acompanhado por 26 meses, o paciente persiste assintomático usando 800 mg de sulfametoxazol e 160 mg de trimetoprim. Os autores discutem essa terapia para lesões extensas, até então considerada pela literatura consultada como de resolução cirúrgica e/ou pelo uso da anfotericina B.

## REFERENCES

1. ARAUJO, J.C.; WERNECK, L. & CRAVO, M.A. — South American blastomycosis presenting as a posterior fossa tumor. *J. Neurosurg.* 49:425, 1978.
2. BARBOSA, W. & DAHER, R.R. — Blastomicose sul-americana (paracoccidioidomicose). In R. Veronesi: *Doenças Infecciosas e Parasitárias*. Ed. 7 Guanabara - Koogan, Rio de Janeiro, 1982.
3. GONÇALVES, A.J.R.; PINTO, A.M.M.; MANSUR FILHO, J. & COSTA e SILVA FILHO, M. — Paracoccidioidomicose: forma linfoabdominal pseudotumoral e disseminada com abdômen agudo e manifestações neurológicas. *Arq. bras. Med.* 57:7, 1983.
4. HUTZLER, R.U.; BRUSSI, M.L.P.; CAPITANI, C.M. & LIMA, S.S. — Acometimento neurológico de paracoccidioidomicose avaliado pela tomografia computadorizada de crânio. *Rev. paul. Med.* 103:243, 1985.
5. KRIVOV, O.S.; BELFORT, E.A.; MONDOLFI, A.; WALZER, I.; ESSENFELD, E. & LANDAETA, T. — Paracoccidioidomycosis of the skull: case report. *J. Neurosurg.* 49:429, 1978.
6. LEMMI, O. & PIMENTA, A.M. — Granuloma paracoccidioidomicótico cerebral: a propósito de um caso operado. *Arq. Neuro-Psiquiat.* (São Paulo) 18:58, 1960.
7. MINGUETTI, G. & MADALOSSO, L.E. — Paracoccidioidal granulomatosis of the brain. *Arch. Neurol.* 40:100, 1983.
8. NOLETO, P.A.; LIMA, D.B.; PINTO, J.R.; SOARES, M.S.; MONTAGNA, N. & LACERDA, P.R.S. — Paracoccidioidomicose: diagnóstico diferencial com tumor cerebral. *Ars curandi* 16:88, 1983.
9. OKAMURA, M. & PIMENTA, L.H.M. — Abscesso intratemporal por *Paracoccidioides brasiliensis* simulando tumor cístico: relato de um caso. *Seara méd. neurocir* 13:61, 1984.
10. PEREIRA, J.M. & JACOBS, F. — Um caso de blastomycose cutanea com acessos epiléticos. *Ann. paul. med. Cirur* 10:216, 1919.

11. PEREIRA, W.C.; RAPHAEL, A. & SALLUM, J. — Lesões neurológicas na blastomicose sul americana: estudo anatomopatológico de 14 casos. *Arq. Neuro-Psiquiat* (São Paulo) 23:95, 1965.
12. PEREIRA, W.C.; TENUTO, R.A.; RAPHAEL, A. & SALLUM, J. — Localização encefálica da blastomicose sul americana: considerações a propósito de 9 casos. *Arq. Neuro-Psiquiat* (São Paulo) 23:113, 1965.
13. PIMENTA, A.M.; MARQUES, J.S. & SETTANI, F.A.P. — Blastomicose cerebral, forma tumoral. *Seara méd. neurocir.* 1:73, 1972.
14. RAPHAEL, A. — Localização nervosa da blastomicose sul americana. *Arq. Neuro-Psiquiat* (São Paulo) 24:69, 1966.
15. RITTER, F.H. — Tumor cerebral granulomatoso por paracoccidioide: a propósito de dois casos operados. *Arq. Neuro-Psiquiat.* (São Paulo) 6:352, 1948.
16. WEISBERG, L.A. — Cerebral computerized tomography in intracranial inflammatory disorders. *Arch. Neurol.* 37:137, 1980.
17. WITTIG, E.O.; KASTING, G. & LEAL, R. — Neuroblastomicose: registro de três casos. *Arq. Neuro-Psiquiat.* (São Paulo) 26:73, 1968.

*Departamento de Neurologia, FCM/UNICAMP — Caixa Postal 1170 - 13.080 - Campinas, SP - Brasil.*