






# Tumefactive primary central nervous system vasculitis mimicking a brain metastasis in a patient with kidney cancer

## *Vasculite primária tumefativa do sistema nervoso central mimetizando uma metástase cerebral em um paciente com câncer renal*

Leonardo Furtado Freitas<sup>1</sup>  Osorio Lopes Abath Neto<sup>2</sup>  Joan E. Maley<sup>1</sup>  Nitesh Shekhrajka<sup>1</sup>   
Bruno A. Policeni<sup>1</sup> 

<sup>1</sup>University of Iowa Hospitals and Clinics, Radiology Department, Neuroradiology Division, Iowa City Iowa, United States.

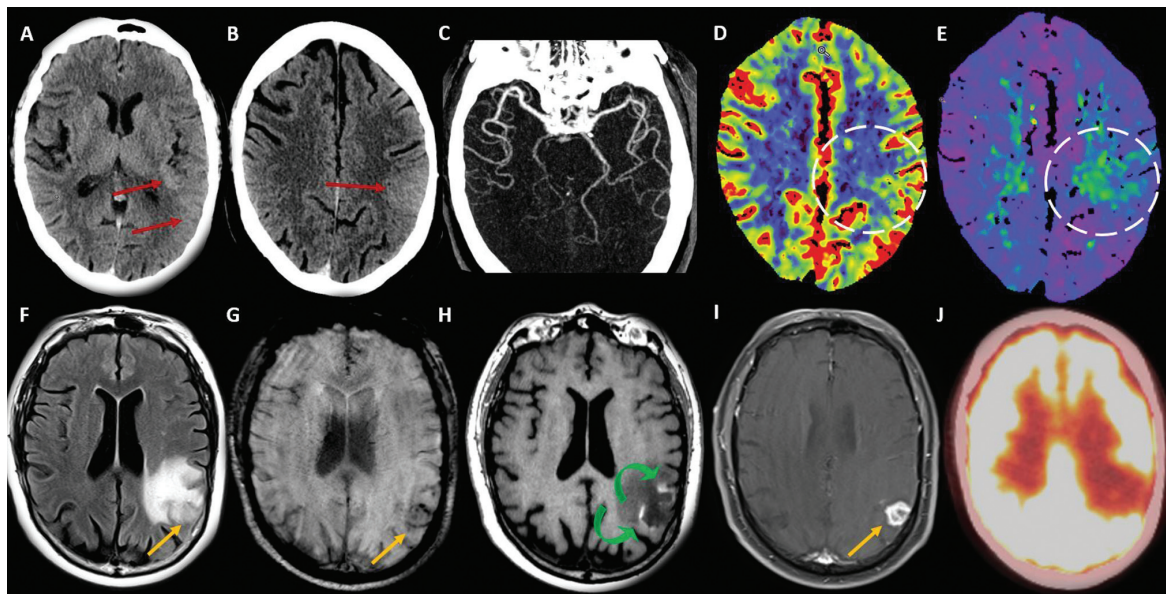
<sup>2</sup>University of Iowa Hospitals and Clinics, Pathology Department, Iowa City Iowa, United States.

Address for correspondence Leonardo Furtado Freitas (email: drleonardofurtado@gmail.com)

Arq. Neuro-Psiquiatr. 2024;82(7):s00441786762.

A 71-year-old male patient with papillary renal cell carcinoma (RCC) presented with confusion, right hemiparesis, and

aphasia. A Head computed tomography (CT) scan (► **Figure 1**) demonstrated a hyperdense swollen cortex on the left side,



**Figure 1** Head computed tomography (CT) stroke protocol (A-E) at the initial presentation. Subtle left parietotemporal and posterior insular hyperdense and swollen cortex (red arrows), with local sulci effacement. The head CT demonstrated normal left middle cerebral artery (MCA) opacification (C) and the perfusion maps showed mild increased cerebral blood flow (CBF) (D) and (time to drain) TTD (E). At the one-month follow-up a brain magnetic resonance imaging (MRI) scan (F-I) demonstrated a cortical/subcortical round lesion (orange arrows) with peripheral microbleeds (G) and irregular enhancement (I), surrounded by vasogenic edema and laminar cortical necrosis (curved green arrows in H). There was no high fluorodeoxyglucose (FDG) uptake in this area on the positron-emission tomography-computed tomography (PET-CT) scan (J).

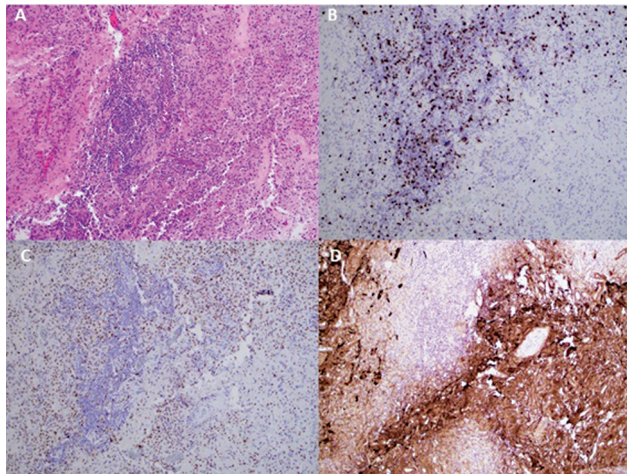
received  
January 9, 2024  
accepted  
February 25, 2024

DOI <https://doi.org/10.1055/s-0044-1786762>.  
ISSN 0004-282X.

Editor-in-Chief: Ayrton Roberto Massaro.  
Associate Editor: Antonio José da Rocha.

© 2024. The Author(s).

This is an open access article published by Thieme under the terms of the Creative Commons Attribution 4.0 International License, permitting copying and reproduction so long as the original work is given appropriate credit (<https://creativecommons.org/licenses/by/4.0/>).  
Thieme Revinter Publicações Ltda., Rua do Matoso 170, Rio de Janeiro, RJ, CEP 20270-135, Brazil



**Figure 2** Brain parenchyma containing a dense inflammatory infiltrate with a predominant perivascular distribution (A). The infiltrate was composed of an admixture of numerous CD8-positive T-cells (B), scattered CD20-positive B-cells (**not shown**), and diffusely distributed histiocytes highlighted by PU.1 (C). Glial fibrillary acidic protein (GFAP) (D) demonstrated extensive and marked reactive astrogliosis around the inflammatory infiltrates.

patent left middle cerebral artery (MCA), and abnormal perfusion. A brain magnetic resonance imaging (MRI) scan and a positron-emission tomography-computed tomography (PET-CT) scan (**►Figure 1**) at one month of follow-up

showed a round lesion with low fluorodeoxyglucose (FDG) uptake with enhancement and laminar cortical necrosis. The differentials included brain metastasis. After the surgery, the pathology (**►Figure 2**) favored vasculitis. This pseudotumoral presentation of central nervous system (CNS) vasculitis is always challenging,<sup>1</sup> especially in cancer patients.<sup>2</sup> The analysis enabled us to consider that it was an acute/subacute and progressive vascular injury, with an evolving enhancing necrotic lesion due to the blood-brain barrier disruption and laminar cortical necrosis.

#### Authors' Contributions

LFF, OLAN, JEM, and NS: manuscript composition. BAP: manuscript review.

#### Conflict of Interest

The authors have no conflict of interest to declare.

#### References

- 1 Vibha D, Singh RK, Garg A, Tripathi M. Focal CNS vasculitis masquerading as new-onset focal aware seizures. *BMJ Case Rep* 2023;16(09):e255535. Doi: 10.1136/bcr-2023-255535
- 2 Suthiphosuwana S, Bharatha A, Hsu CC, et al. Tumefactive Primary Central Nervous System Vasculitis: Imaging Findings of a Rare and Underrecognized Neuroinflammatory Disease. *AJNR Am J Neuroradiol* 2020;41(11):2075–2081. Doi: 10.3174/ajnr.A6736