

SPINAL MYOCLONUS

REPORT OF FOUR CASES

JAMES PITÁGORAS DE MATTOS *, ANA LÚCIA Z. ROSSO **,
ANTONIO J. V. CARNEIRO ***, SÉRGIO NOVIS ****

SUMMARY — Four cases of spinal myoclonus are described, three males and one female. The mean age was 51 years (28-75 years). The mean time between the onset of the myelopathy and the myoclonic jerks was 4.3 months (1-8 months). The involuntary movements were determined by trauma, Devic's disease, tuberculous myelopathy and tumor. Three patients had spastic paraplegia with bilateral myoclonus more evident on the right side. The fourth patient had a flaccid paraplegia with symmetrical jerks. The data suggest that different processes (trauma, demyelinating, infection and tumor) affecting the spinal cord may cause the same type of involuntary movements.

KEY WORDS: spinal myoclonus, paraplegia, spinal cord injury.

Mioclonia medular: relato de quatro casos.

RESUMO — Os autores apresentam quatro casos de mioclonia de origem medular. O primeiro, paciente masculino de 42 anos que, após secção traumática da medula, desenvolveu paraplegia espástica; a TC de coluna sugeriu lesão transversa parcial em T4; cinco meses após, surgiram abalos mioclônicos nos membros inferiores, especialmente à direita. O segundo paciente, mulher de 59 anos, internou-se por apresentar perda bilateral da visão e paraplegia flácida; houve remissão parcial somente do distúrbio visual; nos três meses seguintes, apresentou paraplegia espástica, com abalos mioclônicos, sem evidências de sinais de compressão medular; a imunoliberação observada no estudo do LCR sugeriu tratar-se de doença de Devic. O terceiro paciente, homem de 28 anos, usuário de drogas endovenosas e HIV positivo, internado há oito meses por mielopatia tuberculosa, apresentou mioclônias nos membros inferiores. O último paciente, homem de 75 anos com metástase medular de carcinoma de próstata, apresentou mioclônias nos membros inferiores um mês após a instalação de paraplegia. Nossos dados sugerem que diferentes processos (trauma, desmielinização, infecção e tumor) afetando a medula podem dar origem a abalos mioclônicos.

PALAVRAS-CHAVE: mioclonia medular, paraplegia, traumatismo raquimedular.

Myoclonic jerks may be classified according to their distribution as focal, multifocal and generalized⁶. Electrophysiological studies showed that the myoclonus may have cortical, reticular or spinal origin⁶. The latter has been rarely reported. The first description of spinal myoclonus was performed by Lhermitte in 1919, concerning a patient with a traumatic myelopathy³. According to Patel and Jankovic⁶, different etiologies for spinal myoclonus have been described such as trauma, viral and other infections, intra and extramedullary tumors, paraneo-

Serviço de Neurologia, Setor de Doenças Extrapiramidais, Hospital Universitário Clementino Fraga Filho, Universidade Federal do Rio de Janeiro (UFRJ): * Professor Adjunto, Chefe de Setor; ** Médica; *** Professor Auxiliar de Clínica Médica; **** Professor Titular, Chefe de Serviço. Aceite: 2-junho-1993.

Dr. James Pitágoras de Mattos — Av. São Sebastião 165/101 - 22291-070 Rio de Janeiro RJ - Brasil.

plastic syndromes, AIDS-related myelopathy, electrical injury, arteriovenous malformations, meningocele and neurodegenerative diseases. Myoclonus of spinal origin has a typical frequency of 1 to 3 Hz⁶. The pathophysiology is unclear. It has been suggested that it may arise from interneurons and motor neurons abnormal discharges (Fig. 1).

The purpose of this study is to report four cases of spinal myoclonus having different etiologies.

CASE REPORTS

Cases are summarized in Table 1.

Patient 1. TM, a 42-year-old man developed acute paraplegia following a horse fall. The CT scan suggested a partial transverse lesion of the spinal cord at T4 level. The neurologic examination disclosed paraplegia with pyramidal signs, sensory level at T6 and sphincter disturbance. Five months later, myoclonic jerks were observed, specially on the right leg. Clonazepam (6 mg/day) was given with satisfactory improvement.

Patient 2. TMA, a 59-year-old woman presented with bilateral visual loss and flaccid paraplegia. The visual deficit remitted partially but not the paraplegia. Three months later, she had a spastic paraplegia more evident on the left side and myoclonic jerks on the opposite leg. There was no spinal cord compression. The CSF showed elevated IgG, the EEG was normal and the EMG suggested anterior horn cell injury. The diagnosis of Devic's syndrome was made and she received pulsetherapy with methylprednisolone with no improvement of the paraplegia. The myoclonic jerks almost disappeared with baclofen 30 mg/day. Seven months later, the patient died from sepsis.

Patient 3. LMS, a 28-year-old drug-user man with anti-HIV test positive was admitted because of a tuberculous myelopathy. The neurologic examination showed a flaccid paraplegia, a sensory level at T10, bilateral Babinski sign, generalized deep areflexia and myoclonic jerks in the lower limbs. The EEG was normal. The ENMG study revealed a radiculopathy. The CSF study showed 15 cells (78% mononuclear), 257 mg% of proteins, 50 mg% of glucose. The

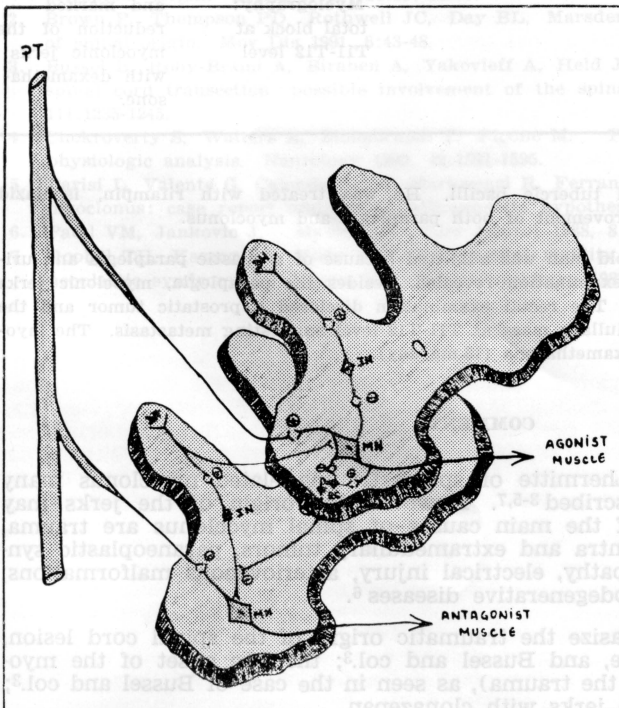


Fig. 1. Presumed structures involved on the pathophysiology of spinal myoclonus. PT, pyramidal tract; DH, dorsal horn; IN, interneuron; RC, Renshaw's cell; MN, motorneuron.

Table 1. Clinical features, diagnostic procedures and outcome of four patients with myelopathy and spinal myoclonus.

| Patient | Age | Sex | Myelopathy | Time of the onset of the myoclonus | Diagnostic procedures | Outcome |
|---------|-----|--------|---------------------------------|------------------------------------|---|---|
| 1 (TM) | 42 | Male | Traumatic | 5 months | X-Ray: fracture of the T4 vertebral body CT: transverse lesion at T4 level | Improvement of the myoclonus with Clonazepan |
| 2 (TMA) | 59 | Female | Demyelinating (Devic's disease) | 3 months | EEG: normal EMG: anterior horn injury SSEP: no cortical potentials CSF: IgG increase | Improvement of both spasticity and myoclonus with baclofen. Death occurred 7 months after. |
| 3 (LMS) | 28 | Male | Infectious (Tuberculosis) | 8 months | ENMG: myoclonic jerks EEG: normal CSF: AFS positive | Mild improvement of the paraplegia with antituberculous drugs. |
| 4 (PCS) | 75 | Male | Metastatic (Prostate) | 1 month | EMG: myoclonic jerks Myelography: total block at T11-T12 level | Improvement of the paraplegia and marked reduction of the myoclonic jerks with dexamethasone. |

bacteriologic study demonstrated tubercle bacilli. He was treated with rifampin, isoniazid and pyrazinamide with mild improvement of both paraplegia and myoclonus.

Patient 4. PCS, a 75-year-old man was admitted because of a spastic paraplegia and urinary retention. The neurologic examination revealed, besides the paraplegia, myoclonic jerks more evident on the right side. The rectal examination disclosed a prostatic tumor and the myelography showed an extramedullary mass at T11-T12 level suggesting metastasis. The myoclonic jerks disappeared with dexamethasone (16 mg/day).

COMMENTS

Since the report of Lhermitte of spinal trauma-related myoclonus many other causes have been described^{3-5,7}. However, the origin of the jerks may remain obscure^{1,2}. Some of the main causes of spinal myoclonus are trauma, viral and other infections, intra and extramedullary tumors, paraneoplastic syndromes, AIDS-related myelopathy, electrical injury, arteriovenous malformations, meningomyelocele and neurodegenerative diseases⁶.

In patient 1 we emphasize the traumatic origin of the spinal cord lesion, as in the cases of Lhermitte, and Bussel and col.³; the late onset of the myoclonic jerks (5 months after the trauma), as seen in the case of Bussel and col.³; and the improvement of the jerks with clonazepan.

Demyelinating diseases are known causes of spinal myoclonus, as seen in our patient 2 with Devic's disease. The diagnosis was based on clinical and laboratorial evidence. The onset of the myoclonus was also late, three months after the spinal injury. Baclofen was initiated for the treatment of the spasticity, but myoclonic jerks also diminished, reinforcing their spinal origin.

AIDS-related myelopathy and other infectious diseases were described as causes of spinal myoclonus⁶. In patient 3, it is tempting to believe that both factors could cause the myoclonic jerks. The use of antituberculous drugs lead to mild improvement of the paraplegia but not the myoclonus.

Spinal compression is a known cause of spinal myoclonus, as in patient 4. Myoclonic jerks appeared in the lower limbs one month after the onset of paraplegia. The spinal origin was reinforced by the great improvement after the use of dexamethasone, which probably alleviated the compression by reducing the perilesional edema.

We believe that our cases have myoclonic jerks of spinal origin because of the clinical pictures in association to laboratorial and neurophysiologic data. The jerks appeared later in the course of the paraplegia, with an average of four months.

Different injuries of the spinal cord may lead to a disconnection between the intrinsic structures of the spinal cord and higher influences. Abnormal discharges from interneurons and motor neurons may then give rise to myoclonic jerks.

Although it is rare, we believe that spinal myoclonus is more frequent than otherwise supposed, and may be underestimated or mistaken for spinal automatism.

REFERENCES

1. Brown P, Thompson PD, Rothwell JC, Day BL, Marsden CD. Axial myoclonus of propriospinal origin. *Brain* 1991, 114:197-214.
2. Brown P, Thompson PD, Rothwell JC, Day BL, Marsden CD. Paroxysmal axial spasms of spinal origin. *Mov Dis* 1991, 6:43-48.
3. Bussel B, Roby-Braml A, Biraben A, Yakovlev A, Held JP. Myoclonus in a patient with spinal cord transection: possible involvement of the spinal stepping generator. *Brain* 1988, 111:1235-1245.
4. Chokroverty S, Walters A, Zimmerman T, Picone M. Propriospinal myoclonus: a neurophysiologic analysis. *Neurology* 1992, 42:1591-1595.
5. Parisi L, Valente G, Calandriello E, Mariorenzi R, Ferrante L, Acqui M, Amabile G. Spinal myoclonus: case report and physiopathogenetic hypothesis. *Riv Neurol* 1990, 60:160-163.
6. Patel VM, Jankovic J. Myoclonus. *Curr Neurol* 1988, 8:109-156.
7. Roobol TH, Kazzaz BA, Vecht ChJ. Segmental rigidity and spinal myoclonus as a paraneoplastic syndrome. *J Neurol Neurosurg Psychiatry* 1987, 50:628-631.