

# CEREBRAL REVASCULARIZATION IN A CASE OF ISCHEMIC CEREBROVASCULAR DISEASE

Juan Antonio C. Flores<sup>1</sup>, Eberval Gadelha Figueiredo<sup>2</sup>, Edson Bor-Seng-Shu<sup>1</sup>, Rodrigo Carvalho<sup>1</sup>, Manoel J. Teixeira<sup>3</sup>, Milberto Scaff<sup>3</sup>

It is well established that patients with transient ischemic attacks (TIA) or minor strokes that are found to have occlusive lesions of major brain-supplying vessels are prone to develop subsequent significant stroke<sup>1-3</sup>. The underlying pathophysiology of cerebral ischemia within this large and heterogeneous group of patients remains matter of debate<sup>2</sup>. Considerable controversy exists on the relative importance of thrombembolic versus hemodynamic mechanisms<sup>4-10</sup>. Following the introduction of extracranial-intracranial (EC-IC) bypass, the procedure was rapidly accepted as a way to increase cerebral perfusion in patients with ischemic cerebrovascular disease. However, the disappointing results of the Cooperative Study on EC-IC Bypass in 1985, led to the virtual abandonment of this procedure for the management of occlusive cerebrovascular disease<sup>8</sup>.

With the advent of contemporary imaging methods and functional blood flow studies, it has been demonstrated that a subset of patients with occlusive cerebrovascular disease is characterized by a severely impaired hemodynamic status<sup>1,6</sup>. In such cases, the EC-IC bypass may represent an attractive and effective procedure to prevent cerebral hemodynamic failure<sup>10</sup>. Retrospective-

ly and particularly in view of new evidence on the pathophysiology of cerebral ischemia, the decision of the EC-IC trial of suggesting abandoning EC-IC bypass completely seems premature<sup>10</sup>.

We present a clinical case of an EC-IC bypass performed in a patient with proved cerebral hemodynamic impairment. Additionally, the current indications, surgical options and clinical outcome are discussed. These cases are rarely reported in the Brazilian literature and many patients who probably could benefit from this procedure are often overlooked.

## CASE

A 63 years-old male presented a history of a previous stroke. Neurological exam revealed a mild left hemiparesis. Angiograms disclosed a total occlusion of the right internal carotid artery (ICA) (Fig 1A) and stenosis of the contralateral ICA. Frequent TIA were reported even with optimal antiagregant therapy. Cerebral angiogram evidenced delayed filling of the contralateral circulation (Fig 1B). MRI disclosed an area of previous parieto-occipital ischemia (Fig 2). A transcranial Doppler ultrasonography at rest and after challenge (Breath Holding Test) revealed impair-

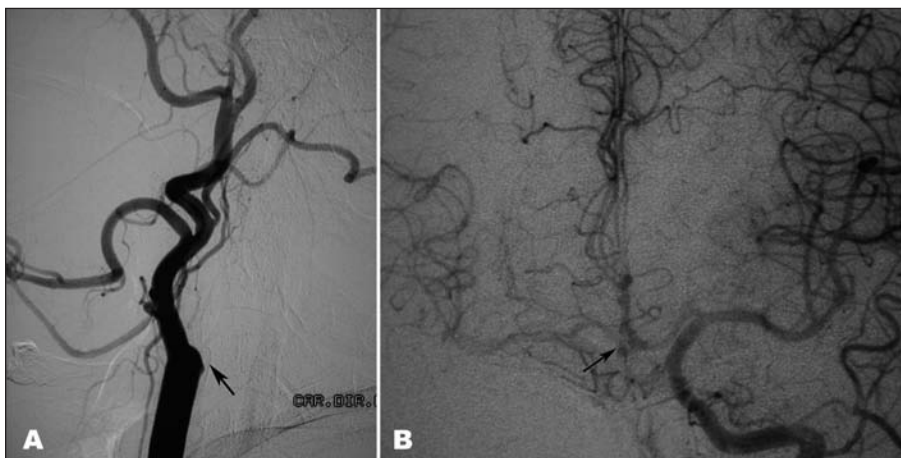


Fig 1. (A) Right common carotid artery angiogram depicting complete occlusion of internal carotid artery (Arrow). No distal filling of internal carotid artery is noticed. (B) Left internal carotid artery angiogram. Notice that the filling of the contralateral anterior circulation is slow and depends upon the left carotid artery, through the anterior communicating artery (arrow), illustrating hemodynamic failure in the right cerebral hemisphere.

## REVASCULARIZAÇÃO CEREBRAL EM UM CASO DE DOENÇA ISQUÊMICA CEREBRAL

Department of Neurology, Division of Neurological Surgery, University of Sao Paulo, School of Medicine, São Paulo SP, Brazil (FMUSP): <sup>1</sup>Assistant; <sup>2</sup>Supervisor; <sup>3</sup>Chairman.

Received 8 February 2008, received in final form 10 May 2008. Accepted 3 June 2008.

Dr. Eberval Gadelha Figueiredo – Rua Oscar Freire 1456 / 34 - 05409-010 São Paulo SP - Brasil. E-mail: ebgadelha@yahoo.com

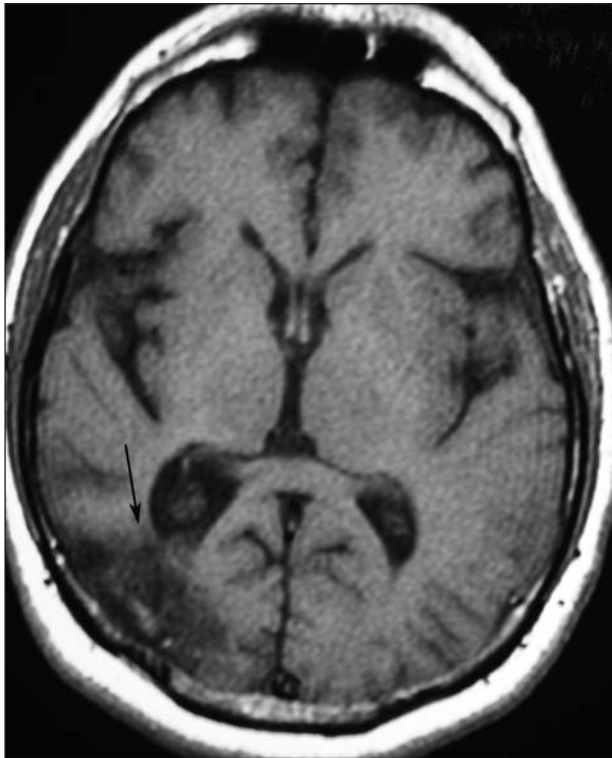


Fig 2. Axial MRI view showing an area suggestive of a previous ischemia in the right parieto-occipital region (arrow) and signs of brain atrophy.

ment in the cerebrovascular reserve. An EC-IC bypass was indicated. As the temporal superficial artery was tiny and insufficient to provide adequate inflow, a high flow anastomosis was carried out. A saphena vein graft was employed to anastomose the right external carotid artery (ECA) to the right middle cerebral artery (MCA). Temporary clipping of the proximal MCA was necessary for 41 minutes.

In the postoperative period, patient was awake and presented no worsening of the preoperative deficit. Postoperative radiological evaluation revealed a completely patent vein graft (Fig 3). At the third postoperative day, a mild paresis of IX cranial nerve was noticed. However, at late follow-up (six months) a total recovering was accomplished. No new episodes of TIA occurred after 12 months follow-up.

The patient has given permission for the publication of this case.

## DISCUSSION

The pathophysiology of stroke is still debated<sup>4,9</sup>. Embolic and hemodynamic mechanisms are implicated as causal factors. Severe atherosclerotic disease of ICA or their intracranial branches may cause reduced perfusion pressure in the distal cerebral circulation. The presence of reduced perfusion pressure (hemodynamic compromise) has long been implicated as a risk factor for ischemic stroke<sup>6</sup>. The relative role of hemodynamic factors

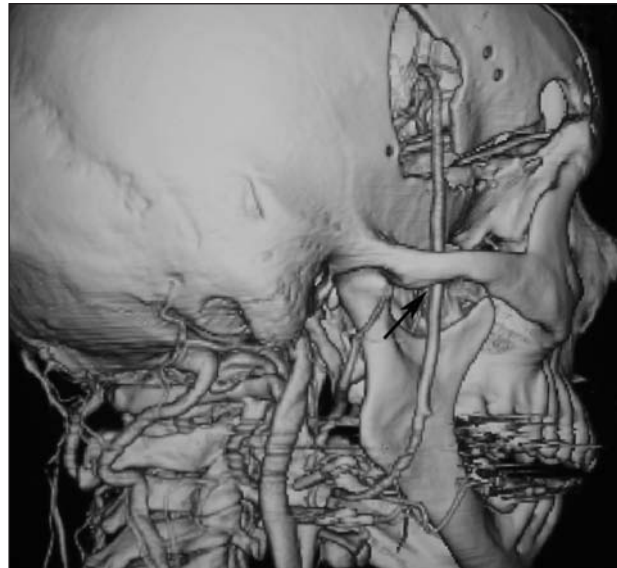

Fig 3. Postoperative angiogram showing the patency of the saphena vein graft. The graft is located underneath the zygomatic arch (arrow) and enters into the cranial cavity through burr holes appropriately located to avoid kinking.

in the pathogenesis and treatment of ischemic stroke is an important and unsolved issue for many patients with cerebrovascular disease<sup>7-10</sup>.

Over the last years, evidence has accumulated suggesting that in addition to thrombolysis, hemodynamic compromise plays an important role in the manifestation of ischemic deficits in patients with occlusive cerebrovascular disease. In these instances, cerebral ischemia is caused by an inadequate collateral blood flow via the circle of Willis.

The results of the International Cooperative Study did not demonstrate any benefit of the EC-IC anastomosis and discouraged the neurosurgical community to indicate this procedure<sup>8</sup>. Nonetheless, this trial had several flaws<sup>10</sup>. Selection errors occurred with asymptomatic patients being included, patients were not selected based on the pathophysiology because the modern exams were not then available, and the collateral flow and the cerebrovascular reserve were not assessed.

New methods of functional evaluation of blood flow have steadily improved our understanding about the importance of hemodynamic impairment in the pathophysiology of ischemic stroke. Abnormal hemodynamic parameters that were not identified in the "IC-EC bypass study" have been recently recognized in a subset of patients sustaining cerebrovascular disease. These parameters have shown to be improved after surgical revascularization<sup>2,5,7,9</sup>. Hence, there is a subset in the vast and heterogeneous group of patients with ischemic stroke that could benefit from an increase in the blood flow as that offered by an EC-IC bypass.

A recent review of literature on the benefits of EC-IC bypass in cerebral ischemia has demonstrated that neurological function and subsequent stroke attributable to haemodynamic insufficiency in patients with symptomatic carotid occlusion or severe stenosis are improved significantly by EC-IC bypass surgery<sup>11</sup>. The haemodynamic parameters observed for patients who experience improved neurological function or diminished stroke risk profile after EC-IC-bypass surgery globally improved<sup>11</sup>. Therefore haemodynamic profile represents an important indicator for EC-IC bypass surgery and gives a good rationale for new trials conducted in a subgroup of patients selected on the basis of their haemodynamic profile. The selection of the patients should also be based on the clinical history and neurological examination. Patients refractory to optimal antiagregant therapy and documented impairment in the cerebrovascular hemodynamic reserve constitute the best candidates to the procedure.

In conclusion, there is consistent evidence supporting clinical usefulness of the EC- IC by- pass in patients with ischemic cerebrovascular disease, particularly when hemodynamic impairment is present and there is no response to antiagregant therapy. Those patients with documented reduction in the cerebrovascular reserve should be considered candidates to the IC-EC bypass procedure,

mainly in reference centers for cerebrovascular surgery. Such reports are rare in the Brazilian literature and many patients who probably could benefit from this procedure are often overlooked.

## REFERENCES

1. McCormick PW, Tomecek FJ, McKinney J, Ausman JI. Disabling cerebral transient ischemic attacks. *J Neurosurg* 1991;75:891-901.
2. Powers WJ. Cerebral hemodynamics in ischemic cerebrovascular disease. *Ann Neurol* 1991;29:231-240.
3. Yonas H, Smith HA, Durham SR, Pentheny SL, Johnson DW. Increased stroke risk predicted by compromised cerebral blood flow reactivity. *J Neurosurg* 1993;79:483-489.
4. Gibbs JM, Wise RJ, Leenders KL, Jones T. Evaluation of cerebral perfusion reserve in patients with carotid-artery occlusion. *Lancet* 1984;1:310-314.
5. Nussbaum ES, Erickson DL. Extracranial-intracranial bypass for ischemic cerebrovascular disease refractory to maximal medical therapy. *Neurosurgery* 2000;46:37-42.
6. Ausman JI, Diaz FG. Critique of the extracranial-intracranial bypass study. *Surg Neurol* 1986;26:218-221.
7. Day AL, Rhoton AL Jr, Little JR. The extracranial-intracranial bypass study. *Surg Neurol* 1986;26:222-226.
8. EC/IC Bypass Study Group: failure of extracranial/intracranial arterial bypass to reduce the risk of ischemic stroke. Results of an international randomized trial. *N Engl J Med* 1985;313:1191-1200.
9. Gibbs JM, Wise RJ, Thomas DJ, Mansfield AO, Russell RW. Cerebral haemodynamic changes after extracranial-intracranial bypass surgery. *J Neurol Neurosurg Psychiatry* 1987;50:140-146.
10. Sundt TM Jr. Was the international randomized trial of extracranial-intracranial arterial bypass representative of the population at risk? *N Engl J Med* 1987;26:316-814.
11. Schaller B. Extracranial-intracranial bypass surgery to reduce the risk of haemodynamic stroke in cerebroocclusive atherosclerotic disease of the anterior cerebral circulation: a systematic review. *Neurol Neurochir Pol* 2007;457-471.