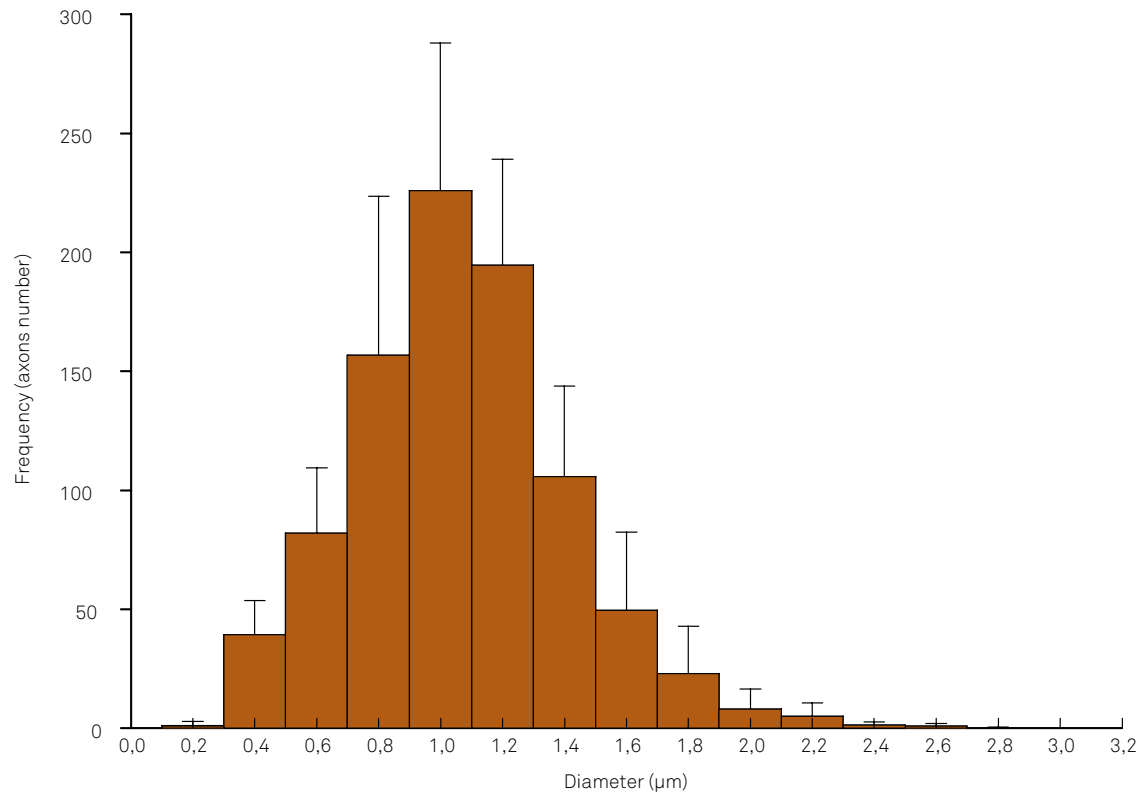


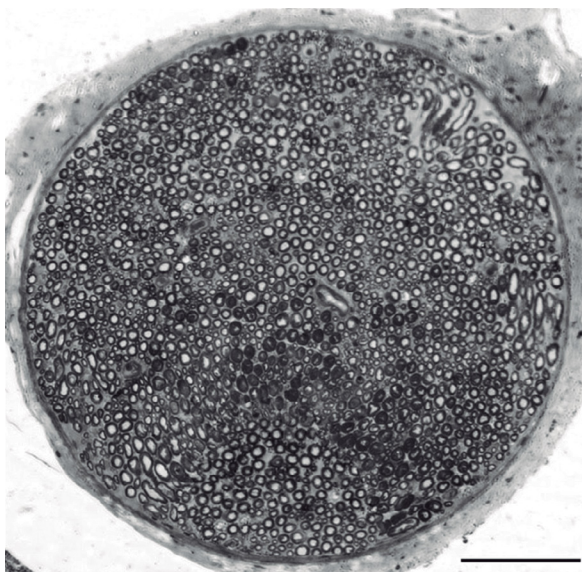
# Erratum

Arquivos de Neuropsiquiatria. 2016;74(5):367-72. doi:10.1590/0004-282X20160051

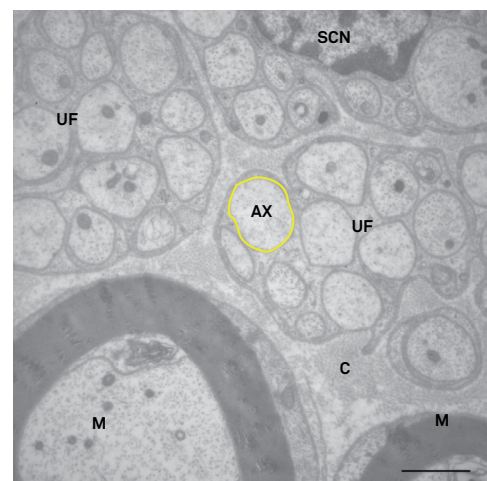
The correct legends for the Figures 4, 5 and 6 are:



**Figure 4.** Common fibular nerve histogram showing the distribution of unmyelinated axon diameters.



**Figure 5.** Transverse semithin section through the distal segment of the rat common fibular nerve. Toluidine blue. Bar = 100 µm.



**Figure 6.** Transverse section through the distal level of a Wistar rat fibular nerve. Images of the following structures can be seen: unmyelinated fibers (UF) and axons (ax) of varied diameters, a Schwann cell nucleus (SCN), myelinated fibers (M), and collagen fibers (C). Yellow line surrounds an unmyelinated axon. Transmission electron microscopy – 14,000X. Bar = 2 µm.