

Reverse crossed cerebellar diaschisis in status epilepticus: case report

Diásquise cerebelar cruzada relacionada a um estado de mal focal: relato de caso

Marcelo Houat DE BRITO¹, Ronnyson Susano GRATIVVOL¹, Leandro Tavares LUCATO², Lécio Figueira PINTO¹

A 53-year-old female with history of ischemic stroke eleven years before was admitted to the emergency room with recurrent few seconds duration head turning seizures in the past two weeks. Electroencephalogram confirmed focal status epilepticus and Brain MRI disclosed restricted diffusion over left hemisphere regions, together with signs of reverse crossed cerebellar diaschisis (Figure 1).

Diaschisis is a transient neuronal shock modality attributable to depression of distant parts of the brain, connected to an injured area¹. In focal status epilepticus, cerebellar injury is hypothesized to be due to an excessive excitatory neuronal transmission in the cortico-pontine-cerebellar tract².

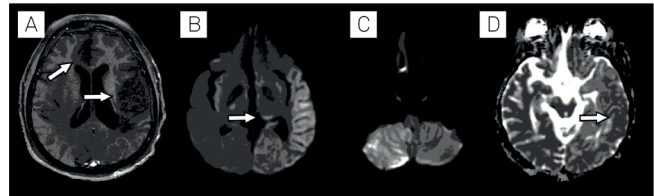






Figure 1. Axial postcontrast T1-weighted image (A) shows two chronic infarcts (arrows); axial DWI (B and C) demonstrate restricted diffusion in the cerebral cortex in the vicinity of the infarction in the territory of the left middle cerebral artery, due to status epilepticus. The involvement of left thalamic pulvinar (arrow in B) and right cerebellar hemisphere (C), (reverse crossed cerebellar diaschisis) can also be noticed. ADC map (D) discloses true cortical restricted diffusion (arrow).

References

- Engelhardt E, Gomes MM. Shock, diaschisis and von Monakow. *Arq Neuropsiquiatr*. 2013 Jul;71(7):487-9. <http://dx.doi.org/10.1590/0004-282X20130067>
- Samaniego EA, Stuckert E, Fischbein N, et al. Crossed cerebellar diaschisis in status epilepticus. *Neurocrit Care*. 2010 Feb;12(1):88-90. <https://doi.org/10.1007/s12028-009-9312-y>

¹Universidade de São Paulo, Hospital das Clínicas, Departamento de Neurologia, São Paulo SP, Brazil.

²Universidade de São Paulo, Hospital das Clínicas, Departamento de Radiologia, São Paulo SP, Brazil.

Marcelo Houat DE BRITO  <https://orcid.org/0000-0001-7521-1388>; Ronnyson Susano GRATIVVOL  <https://orcid.org/0000-0001-8136-900X>; Leandro Tavares LUCATO  <https://orcid.org/0000-0001-9181-5245>; Lécio Figueira PINTO  <https://orcid.org/0000-0002-2694-5120>

Correspondence: Marcelo Houat de Brito; Departamento de Neurologia / HC-FMUSP; Av. Dr Enéas de Carvalho Aguiar, 255; 05403-000 São Paulo SP, Brazil; E-mail: marcelohbrito@gmail.com

Conflict of interest: There is no conflict of interest to declare.

Received on August 28, 2019; Accepted on October 16, 2019.

