

Acute ischemic stroke resembling Saturday night palsy

Acidente vascular cerebral isquêmico mimetizando a síndrome do sábado à noite

José Luiz Pedroso^{1,2}, Marcos Knobel², Rodrigo Meirelles Massaud², Elias Knobel²

A 90-year-old man woke-up with dropped hand. Examination showed weakness in left hand: inability to extend wrist and fingers. National Institutes of Health Stroke Scale (NIHSS): zero. He had left ventricular hypokinesia. Radial neuropathy was suspected. Considering age and risk for embolism, brain MRI was performed, and disclosed minor acute ischemic stroke in left frontal cortex (Figure).

Upper extremities monoparesis rarely occur in cerebral cortex lesions, and may mimic peripheral nerve injuries^{1,2}. Saturday night palsy is a colloquial term which describes radial nerve injuries from falling asleep with the arm under the body³. Neurologists should be aware that cerebral cortex lesions in old patients with cardiovascular risk factors may present with motor paralysis limited to the upper extremities.

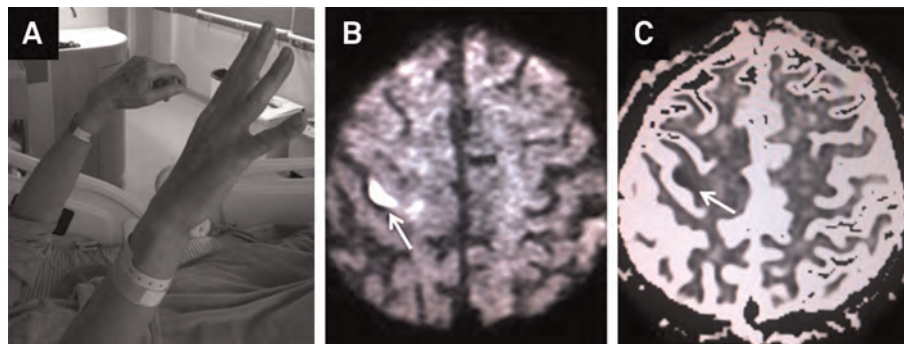


Figure. Patient with dropped hand and inability to extend left wrist, thumb and fingers (A). Diffusion-weighted brain MRI showing a small area of restricted diffusion in the left frontal cortex (B). ADC map-weighted brain MRI disclosing an hypointense signal in left frontal cortex supporting the diagnosis of acute ischemic stroke (C).

References

1. Edlow JA, Selim MH. Atypical presentations of acute cerebrovascular syndromes. *Lancet Neurol* 2011;10:550-560.
2. Takahashi N, Kawamura M, Araki S. Isolated hand palsy due to cortical infarction: localization of the motor hand area. *Neurology* 2002;58:1412-1414.
3. Spinner RJ, Poliakoff MB, Tiel RL. The origin of "Saturday night palsy"? *Neurosurgery* 2002;51:737-741.

¹Departamento de Neurologia, Universidade Federal de São Paulo, São Paulo SP, Brazil;

²Hospital Israelita Albert Einstein, São Paulo SP, Brazil.

Correspondence: José Luiz Pedroso; Rua Botucatu, 740; 04023-900 São Paulo SP, Brasil; E-mail: jlpedroso.neuro@gmail.com

Conflict of interests: There is no conflict of interest to declare.

Received 04 July 2013; Received in final form 20 December 2013; Accepted 13 January 2014.