

FURTHER DISCUSSION ON THE "NEW-GROWING" NERVE-FIBRES WHICH REPOPULATE THE DISTAL SEGMENT OF NERVES COMPLETELY SEPARATED FROM THE PROXIMAL STUMP FOR MORE THAN SIX MONTHS

EROS ABRANTES ERHART *

CECIL JOSÉ REZZE **

The scope of this paper is to present and discuss the different histological findings, recently reported by us before the VIII International Congress of Anatomists, Wiesbaden, Germany and the V International Congress of Neuropathology, Zurich, which were identified among the nerve-fibres that repopulate the distal and intermediate segments of nerves, maintained undisturbed in their natural connective tissue bed, and completely separated from the proximal stump for more than six months (Erhart and Erhart ^{6, 7}, Erhart ⁸, Erhart and Rezze ^{9, 10, 11}).

The above referred histological findings resemble some of the progressive stages of the Wallerian degeneration and, for what we have seen in our experimental observations, they show up as a suggestive sequence of stages which seem to indicate a possible gradual reorganization and further regeneration of nerve-fibres in isolated stumps.

MATERIAL AND METHODS

The serial histological preparations, longitudinally sectioned 8 μ , silver impregnated by De Castro, considered in the present report were selected from the material we have recorded and analysed during these last nine years while studying the nerve fibres which repopulate, under different experimental conditions, the distal and intermediate segments of dog fibular, intercostal, phrenic and ulnar nerves completely separated from the proximal stump for more than six months. Obviously the slide selection was based on the presence of the particular histological pictures in which we were interested. They were identified in the intermediate and or distal nerve segments of eleven different dogs.

RESULTS

While studying the nerve fibres which repopulate, under different experimental conditions, isolated nerve segments, we observed now and then in the silver preparations, six and eight months post-operatively, among the nerve fibres with

Departamento de Anatomia da Faculdade de Medicina da Universidade de São Paulo (Prof. O. Machado de Sousa): * Professor Assistente, Docente-Livre, Chefe da Secção de Neur Anatomia; ** Professor Assistente.

normal appearance, different histological pictures resembling some stages of the Wallerian degeneration, but of whose nature or significance we had no idea. A suggestive sequence of these histological findings showed up clearly, for the first time, in two specially well impregnated, completely isolated nerve stumps, twelve months post-operatively. With a schedule established the revision of our experimental material was done, and the formerly isolated findings could be put together. They demonstrated the existence of suggestive progressive stages of something as a development and maturation which would explain, perhaps, a possible gradual reorganization and regeneration of nerve-fibres in isolated nerve segments, maintained undisturbed on their natural environment and completely separated from the proximal stump for more than six months.

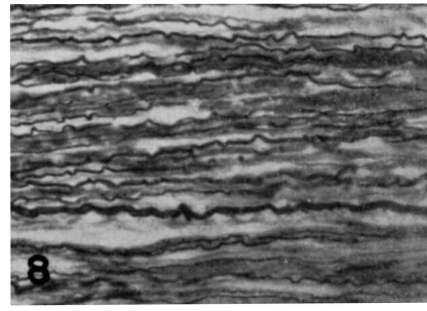
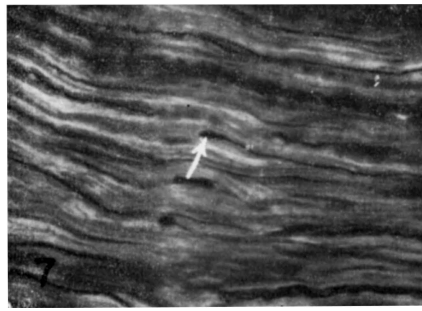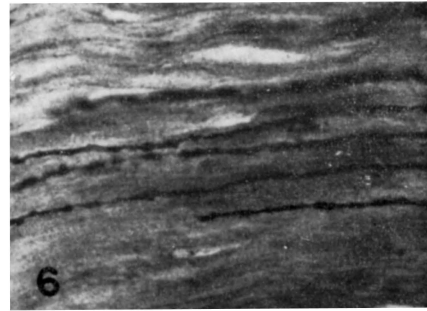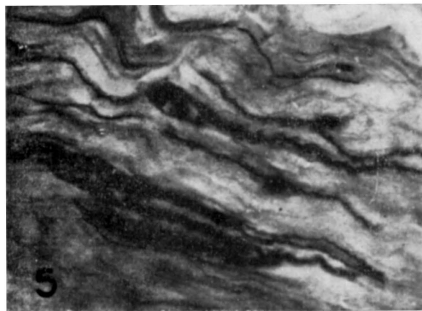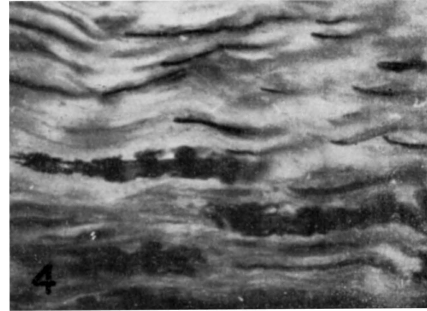
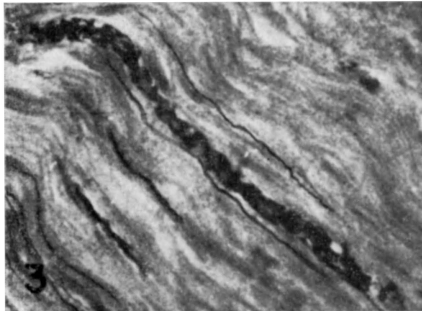
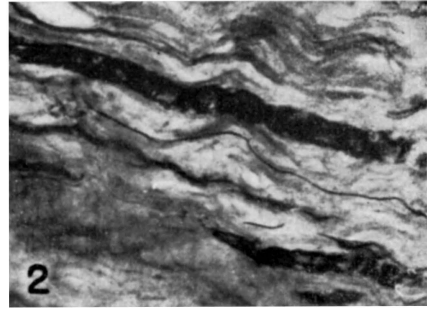
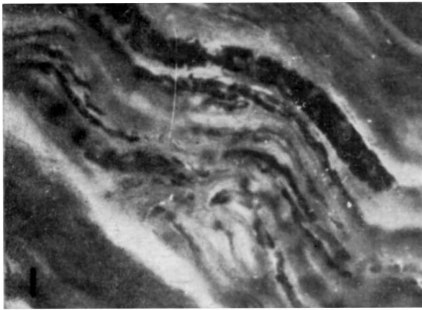
Figures 1-5 depict examples of what could be considered as some of the main stages of the suggested progressive reorganization referred above. Figure 1 shows just narrow elongated parallel strands with a light concentration of a silver impregnated "material" evenly distributed along them. In Figures 2 to 5 the concentration of the silver impregnated "material" is progressively higher, first at irregular than at regular intervals and there is, furthermore, a tendency for a maturation of the linear strands; the boundaries become gradually more distinct; axons with normal appearance are seen side by side to these suggestive stages of nerve-fibres in "reorganization". In Figures 6 and 7 are seen new-growing axons with their characteristic beaded appearance because of the irregular enlargements; in one of them (arrow Fig. 7) a typical growing bud is evident. Figure 8 shows normal nerve-fibres with different diameters in the distal segment of a dog ulnar nerve completely separated from the proximal stump for fifteen months.

DISCUSSION

The technical difficulties encountered in demonstrating the origin of the nerve fibres which repopulate the distal and intermediate segments of nerves completely separated from the proximal stump for more than six months, constitute a limiting factor in studying possible patterns of new-forming isolated nerve-fibres.

It seems based on our former observations that these fibres must have arisen from a source other than the proximal stump, neighbour nerves or *nervi-vasorum* (Erhart and Rezze⁹).

Before the end of the fifth month after nerve transection no remnants of nerve-fibres could be found in the serial silver preparations of the intermediate or distal segments completely separated from the proximal stump, because of the Wallerian degeneration. But, from the sixth month on, very few axons with normal appearance were evident. They were progressively thicker, longer and greater in number in the isolated nerve stumps examined eight, twelve, fifteen, eighteen, twenty-four and thirty months post-operatively. They formed inclusively the neuroma-like structures (Erhart and Rezze¹⁰). These nerve-fibres, as referred formerly, were never close to the *vasa-nervorum* nor were disposed close to the periphery of a nerve fascicle in relation to the peri or epineurium. They were always disposed as "lost" among the neurilemma bands of proliferated Schwann cells and were more numerous in the smaller nerve fascicles. Although carefully followed in serial sections, as said before, we were never able to find nerve-cells related to them.



Figures 1-8 are photomicrographs of 8 μ longitudinal sections of distal and intermediate segments of dog ulnar nerves completely separated from the proximal stump for more than six months. De Castro silver impregnation ($\times 480$). For description see text.

The different histological pictures, which are now being presented as suggestive progressive stages of perhaps a certain kind of development and maturation of nerve-fibres in reorganization, were easier identified in the elder isolated stumps (twelve or more months post-operatively) than in the more recent ones (six or eight months post-operatively). May be, because in the latter, still poor in nerve-fibres, the "biological recovery" of the whole system is just beginning, and in the former, usually rich in nerve-fibres, the "biological recovery" is plain.

These findings and data suggest the existence of something to be investigated.

It is accepted that the protein synthesis of neurons seems to occur exclusively in the cell bodies, not in the axons (Hydén¹², Droz and Leblond⁵) and there are conclusive evidences for the axoplasmic flow theory of Weiss (Weiss et al.¹⁷). A retrograde axoplasmic flow also occurs in accordance with the observations of Lubinska et al.¹⁴ and Dahlström³, who states: — "Whether or not this centripetally directed transport occurs normally or is caused by the axonal trauma cannot be decided at present".

If there is a retrograde axoplasmic flow where should be its protein synthesis? De Robertis⁴ suggests that there is some in the nerve terminals and, after a transection or constriction, even locally in the axons. Courtey² stated: — "Le bout distal se présente comme une portion de neurite isolé du péricaryon, avec une arborisation terminale à chaque extrémité, douée chacune d'une activité propre qui permet l'allongement de la fibre synchroniquement en directions distale et proximale". Furthermore, Shanthaveerappa and Bourne¹⁶ reported observation based on histochemical results that the proximal and distal stumps have equivalent metabolism.

Based on such statements and comparing our observation and histological findings reproduced in the present paper with those of Pinner and Campbell¹⁵ and Dahlström³ we would suggest for other investigators, working on the field with specialized histochemical methods, to prove or deny this proposed eventual progressive reorganization and regeneration of nerve-fibres in isolated (intermediate and distal) segments completely separated from the proximal stump for more than six months, but maintained in their natural connective tissues beds.

Presenting this hypothesis based on experimental evidences we are absolutely not arguing against the neuron theory or trying to return back to the old ideas much discussed at the beginning of the century. The axon originates from a nerve-cell body, there is no doubt about it. But, when mature with its definite connections (motor and sensory) established, may be it has still unknown biological properties and characteristics, intimately related to its natural environment, which are responsible for its normal maintenance and perhaps, also, for a "self reorganization and regeneration" when injured or completely separated from its original cell body for six or more months. Remembering, our observation were done in transected dog nerves.

Cajal¹ in 1928 stated: — "The axon is protected and perhaps nourished by the cells of Schwann and it lives in a *milieu* of connective tissues rich in plasma and in capillaries". "In order that the nutritional process should be kept up, it is absolutely necessary that some dynamic thing, of whose nature we have no idea, should constantly be radiated from the neuronal soma so as to stimulate the protoplasm and prevent withering".

From Cajal's unknown "dynamic thing", something is known now a days: the cell protein synthesis, the axoplasmic flow, Levi Montalcini¹³ "nerve growth factor". But is that all?!...

The Wallerian degeneration is another reality. Nevertheless, if our supposition is true, it should be more properly nominated *Wallerian des-organization*, because what is seen by the usual optical methods, by electron microscopy and has been demonstrated biochemically, is a desintegration of the normal nerve structures. But what happens with the ultrastructure constituters once organized and optically identified as axon, myelin, incisures, nodes, neurilemma and so on?...

Has Levi-Montalcini¹³ protein "nerve growth factor" something to do in such isolated axon regeneration processes?

Whether or not these questions are just theoretical or will have definite answers in a near future we cannot decide.

SUMMARY

Based on experimental data previously published is presented and discussed a progressive sequence of histological findings (figs. 1-8) which suggest a possible gradual reorganization and regeneration of nerve-fibres in the distal and intermediate nerve segments, completely separated from the proximal stump for more than six months, but maintained undisturbed in their natural connective tissues beds.

RESUMO

Novas observações sôbre as fibras nervosas que repopulam o segmento distal de nervos com mais de seis meses de secção completa

Com base em dados experimentais, publicados em trabalhos anteriores, são apresentados e discutidos, aspectos histológicos que, analisados em seqüência (figs. 1 a 8), sugerem uma possível via de reorganização progressiva com conseqüente regeneração de fibras nervosas, nos segmentos intermédio e distal de nervos, completamente separados por transecção, entre si e do côto proximal, há mais de seis meses, mas mantidos em seus leitos conectivos naturais.

REFERENCES

1. CAJAL, S. RAMON y — Degeneration and regeneration of the nervous system. Translated and edited by Raoul M. May. Oxford Univ. Press, London, 1928.
2. COURTEY, B. — Observations en contraste de phase de la régénération "per primam intentionem" des fibres nerveuses en culture chez l'embryon de poulet. Comptes Rendus de l'Ass. Anat. 117:458-473, 1963.
3. DAHLSTRÖM, A. — Observations on the accumulation of noradrenaline in the proximal and distal parts of peripheral adrenergic nerves after compression. J. Anat. 99:677-689, 1965.
4. DE ROBERTIS, E. — Histophysiology of Synapses and Neurosecretion. Pergamon Press, Oxford-London-New York-Paris, 1964.
5. DROZ, B. & LEBLOND, C. P. — Axonal migration of proteins in the central nervous system and peripheral nerves as shown by autoradiography. J. Comp. Neurol. 121:325-346, 1963.
6. ERHART, M. B. & ERHART, E. A. — Sobre o comportamento das fibras nervosas no côto distal de nervo fibular de *Canis familiaris* após transecção total. Folia Clinica et Biologica (São Paulo) 28:98, 1958.
7. ERHART, E. A. & ERHART, M. B. — Normal axis-cylinders in the distal segment of nerves completely separated from the proximal stump for up to 24 years. Anat. Rec. 136:189, 1960.
8. ERHART, E. A. — Normal nerve-fibres in the distal segment of nerves completely separated from the proximal stump for more than six months. Arq. Neuro-psiquiat. (São Paulo) 20:289-306, 1962.
9. ERHART, E. A. & REZZE, C. J. — Nerve fibres in isolated segments of dog ulnar nerve after complete brachial plexotomy and periaxial artery sympathectomy. Arq. Neuro-siquit. (São Paulo) 23:82-90, 1965.
10. ERHART, E. A. & REZZE, C. J. — The neuroma-like structure of the long-time severed and isolated nerve stumps. Arq. Neuro-psiquiat. (São Paulo) 23:91-94, 1965.
11. ERHART, E. A. & REZZE, C. J. — Experimental data and practical results which modify the present concepts of peripheral nerve fibres degeneration and regeneration. Proceedings of the V International Congress of Neuropathology: 667-671, 1965. Published by Excerpta Medica.
12. HYDEN, H. — The Neuron. In The Cell, IV, 215-323. Edited by Brachet and Mirsky. Academic Press. New York-London, 1960.
13. LEVI-MONTALCINI, R. — Growth control of nerve cells by a protein factor and its antiserum. Science 143:105-110, 1964.
14. LUBINSKA, L. et al. — Bidirectional movements of axoplasm in peripheral nerve fibres. Acta Biol. Exp. Var. 23:239-247, 1963. (Quoted from Dahlström³).
15. PINNER, B. & CAMPBELL, J. B. — Alkaline phosphatase activity of incisures and nodes during degeneration and regeneration of peripheral nerve fibres. Exp. Neurol. 12:159-172, 1965.
16. SHANTHAVEERAPPA, T. R. & BOURNE, G. H. — The effects of transection of the nerve trunk on the perineural epithelium with special reference to its role in nerve degeneration and regeneration. Anat. Rec. 150:35-50, 1964.
17. WEISS, P.; TAYLOR, A. C. & PILLAI, P. A. — The nerve fibres as a system in continuous flow: microcinematographic and electron microscopic demonstrations. Science 136:330, 1962.

Departamento de Anatomia. Faculdade de Medicina da Universidade de São Paulo — Caixa Postal 2921 — São Paulo, SP — Brasil.