

Proximal limb weakness and amyotrophy in a man with silicosis

Fraqueza muscular proximal e amiotrofia em um homem com silicose

Paulo Victor Sgobbi de Souza¹, Thiago Bortholin¹, Fernando George Monteiro Naylor¹, Wladimir Bocca Vieira de Rezende Pinto¹, Beny Schmidt¹, Acary Souza Bulle Oliveira¹

A 55-year-old man presented with four-year history of progressive muscle wasting and weakness. His medical history disclosed advanced stage silicosis. The examination revealed flaccid quadriplegia with proximal amyotrophy. Serum creatine-kinase levels and screening for metabolic and inflammatory disorders were unremarkable. Muscle biopsy showed myopathic findings and the presence of abnormal amorphous and heterogeneous intracytoplasmic and subsarcolemmal content (Figure).

Toxic myopathies can result from environmental and occupational exposure to toxic agents¹. Silicosis results from the deposition of crystalline silicon dioxide (silica) in lung and is associated with different systemic involvement, including osteoporosis, susceptibility to autoimmune disorders, constrictive pericarditis² and, rarely, myopathy.

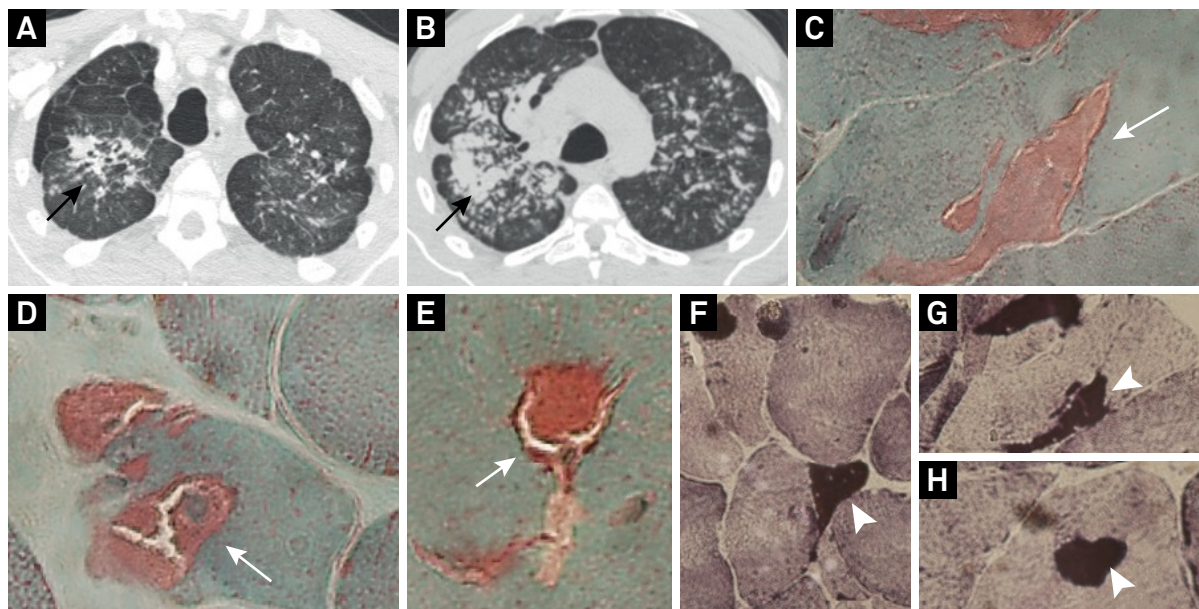


Figure. Chest CT-scan and muscle biopsy findings in silicosis. (A, B) Axial chest CT-scan showing bilateral severe advanced stage interstitial lung disease with marked lung architectural distortion (black arrow). Deltoid muscle biopsy showing abnormal subsarcolemmal and intracytoplasmic content disclosed in red in trichrome Gomori stain (C-E; white arrow) and black in NADH-TR histochemistry (F-H; white arrow-head).

References

1. Dalakas MC. Toxic and drug-induced myopathies. *J Neurol Neurosurg Psychiatry*. 2009;80(8):832-8. <https://doi.org/10.1136/jnnp.2008.168294>
2. Leung CC, Yu ITS, Chen W. Silicosis. *Lancet*. 2012;379(9830):2008-18. [https://doi.org/10.1016/S0140-6736\(12\)60235-9](https://doi.org/10.1016/S0140-6736(12)60235-9)

¹Universidade Federal de São Paulo, Divisão de Doenças Neuromusculares, Departamento de Neurologia e Neurocirurgia, São Paulo SP, Brasil.

Correspondence: Wladimir Bocca Vieira de Rezende Pinto; Departamento de Neurologia e Neurocirurgia da UNIFESP; Rua Estado de Israel, 899; 04022-002 São Paulo SP, Brasil; E-mail: wladimirbvrpinto@gmail.com

Conflict of interest: There is no conflict of interest to declare.

Received 15 February 2017; Accepted 04 October 2017.