

Nucleoplasty as a therapeutic option for lumbar disc degeneration related pain: a retrospective study of 396 cases

Nucleoplastia como opção terapêutica para dor relacionada à degeneração do disco lombar: um estudo retrospectivo de 396 casos

José Lourenço Kallás^{1,2}, Bruno Loyola Godoy¹, Cesar Fantezia Andraus¹, Felipe Gonçalves de Carvalho¹, Maria Emilia Cosenza Andraus³

ABSTRACT

Objectives: To make a retrospective analysis and evaluate a clinical response to the control of disc degeneration related pain of 396 patients submitted to percutaneous lumbar nucleoplasty; and to make a record of visual analogical scale (VAS) up to a three-year follow-up after the surgical procedure. **Methods:** Analysis of VAS score in 396 patients with lumbar disc degeneration related pain, according to anamnesis, clinical examination and magnetic resonance imaging (MRI), without improvement of previous clinical treatment, submitted to percutaneous nucleoplasty. **Results:** A total of 26% of the patients presented 100% remission of pain or paresthesia, of whom 75% showed at least 50% of pain improvement. The median VAS pain improvement was about 67%. **Conclusions:** The median VAS improvement in inferior disc levels was higher than four points. The VAS showed improvement of the pain and paresthesia up to a three-year follow up after the surgical procedure.

Key words: nucleoplasty, disc degeneration, lumbar disc herniation, thermic discectomy, radiculopathy, low back pain, percutaneous discectomy.

RESUMO

Objetivos: Analisar retrospectivamente a resposta clínica no controle da dor relacionada à degeneração discal em 396 pacientes submetidos à nucleoplastia percutânea lombar; e fazer um registro da escala analógica visual (EAV) com seguimento de três anos após a cirurgia. **Métodos:** Análise da EAV de 396 pacientes com diagnóstico de hérnia de disco, de acordo com anamnese, exame clínico e imagens por meio de ressonância magnética (RM), sendo que nenhum deles apresentou melhora com tratamento clínico prévio. Estes pacientes foram submetidos à nucleoplastia percutânea. O estudo utilizou, para avaliação, o registro de escala analógica visual (EAV) durante seguimento de até três anos após o procedimento cirúrgico. **Resultados:** Um total de 26% apresentou 100% de remissão da dor ou parestesia; 75% apresentaram pelo menos 50% de melhora da dor. A mediana da EAV de melhora da dor foi de aproximadamente 67%. **Conclusões:** Houve melhora da EAV, com mediana maior do que quatro pontos nos pacientes com acometimento nos níveis discais inferiores. A EAV mostrou melhora da dor e parestesia num período de seguimento de até três anos após o procedimento cirúrgico.

Palavras-Chave: nucleoplastia, degeneração discal, hérnia de disco lombar, discectomia térmica, radiculopatia, dor lombar, discectomia percutânea.

The management of the lumbar disc degeneration related pain is a common and yet controversial issue in the neurosurgical practice. Since its first description by Dandy¹, at the beginning of last century, the surgical strategies have continued to improve, providing a myriad of different therapeutic options. Despite a faster relief of an acute attack by surgical discectomy compared with the conservative treatment, there

is no clear evidence in the literature of a long-term benefit². There is also a paucity of data showing consistent evidence of benefits with the many described minimally invasive techniques for disc herniation³.

The first papers about percutaneous thermic discectomy were published in 1985⁴ and the term nucleoplasty was defined by Chen in 2003, using a patent required technology

¹Neurosurgery Service, Hospital Universitário Clementino Fraga Filho, Universidade Federal do Rio de Janeiro (HUCFF/UFRJ), Rio de Janeiro RJ, Brazil;

²Master in Science Program in Surgical Sciences Student, UFRJ, Rio de Janeiro RJ, Brazil;

³Neurology Service, Santa Casa da Misericórdia do Rio de Janeiro; Permanent Professor of *Strictu Sensu* Postgraduation Program in Neurology, Universidade Federal do Estado do Rio de Janeiro (UNIRIO), Rio de Janeiro RJ, Brazil.

Correspondence: José Lourenço Kallás; Rua Camaragibe 12; 20520-130 Rio de Janeiro RJ - Brasil; E-mail: joselourencokallas@uol.com.br

Conflict of interest: This study was partially supported by Optika/Arthrocare® Corporation.

Received 04 April 2012; Received in final form 05 September 2012; Accepted 12 September 2012

called Coblation (ArthroCare® – Sunnyvale, California, USA)⁵. Al-Zain et al.⁶, in a prospective study with 69 patients, presented that 58% of them had an improvement of the radicular pain for more than 50% after one year. Manchikanti et al.⁷ published a systematic review based on Cochrane Library criteria, showing a level II-III (multiple type series with or without intervention) evidence of benefit for mechanical lumbar percutaneous disc decompression for treatment of radicular pain.

This technology was approved for using in the USA by the Food and Drug Administration (FDA) and by the *Agência Nacional de Vigilância Sanitária* (ANVISA) in Brazil. It has been used by the neurosurgery authors since 2004, at the *Hospital Universitário Clementino Fraga Filho, Universidade Federal do Rio de Janeiro* (HUCFF-UFRJ) and in the private practice, with satisfactory results and low incidence of complications.

This work intended to analyze retrospectively a total of 396 cases submitted to percutaneous lumbar nucleoplasty with Coblation Technology (ArthroCare® – Sunnyvale, CA, USA), showing the procedure effects in the control of lumbar disc herniation related pain.

METHODS

We performed a retrospective analysis of 396 patients, with lumbar disc herniation related pain, and no improvement after previous conservative clinical treatment. All of them were submitted to percutaneous nucleoplasty, performed from August 2004 to February 2008.

The patients were included when they presented pain with clinical-radiological correlation; magnetic resonance imaging (MRI) showed disc protrusions or contained hernia; at least 2/3 of intervertebral space height preservation; and previous treatment with short rest period, pain medications and motor physiotherapy, without satisfactory improvement.

Cases were excluded: in the presence of obvious disc fragment sequestration (with or without longitudinal migration); loss of more than 1/3 of the intervertebral space height; diffuse or multilevel degenerative disc changes on imaging exams; no signs of radicular involvement or axial pain associated with the degenerated level; patients previously diagnosed or with antecedents of psychological and/or psychiatric disorders, or in cases of its suspicion by the history; uncontrolled systemic diseases, as well as active infection or neoplasm.

Surgical technique

The procedures were performed in the operation room (OR) with continuous heart and respiratory monitoring, peripheral venous access punctured by an anesthesia staff member familiar with that surgical routine. All patients were previously informed that they would need to be awake during the procedure and kept in the same position. They were

prepared in the prone position, without cushioning, except for some hyperlordotic cases, where cushions were used to augment the entry space.

After monitoring and positioning, the access point of the disc was marked on the skin, using the safe triangular working zone, as well as the middle line and those of projection of the intervertebral spaces targeted forming an orthogonal angle. The radioscopy device was used for that purpose. The triangular safety zone for lumbar disc access is shaped like a rectangle triangle, limited by the facet articulations, the superior *plateau* of the inferior vertebrae, and the lateral projection of the nerve root. Lateral incidence images of the lumbar spine were made for measuring the distance between the lumbar superficial limit and the geometric center of the disc. This distance was then plotted in the horizontal disc line first marked, laterally from the middle line, providing the exact point of the needle entrance in the skin. The special disc puncture needle (Arthrocare® – Sunnyvale, CA, USA) penetrated the skin and the subcutaneous tissue at a 45° targeting the disc space (Fig 1). The progression of the access was guided by radioscopy in the posteroanterior and lateral incidences, and alternated with local anesthesia of the tissues with lidocaine 2% (without vasoconstrictors). Multiple X-ray incidences were necessary for providing safety in the needle guidance in order to avoid the main vessels, neural roots, and spinal dura mater.

With the tip of the needle at the center of the disc, the inner guide wired was retrieved, the inner radiofrequency delivering needle was inserted, and its position was checked (Fig 2). The first incursion was then executed, 1 cm in length in the ablation function, intensity 1, followed by a correspondent 1 cm withdrawal of the needle, in the coagulation function (each one taking in 12 seconds). If the patient complained about pain or paresthesias, the needle was repositioned to a more central point of the disc. Otherwise, the

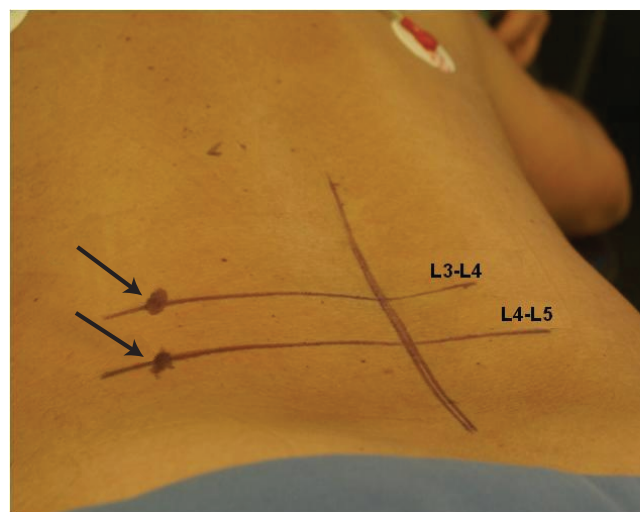


Fig 1. Entry point to L4-L5 space with the needle insertion at a 45° to the posterior horizontal plane, directing it to the center of the intervertebral disc.

procedure went on, by repeating six incursions with the same methodology, and only this time in intensity 2.

As the radiofrequency needle was pulled out, about 0.5 mL (20 mg) of methylprednisolone succinate was administered to the periradicular foraminal area of that level, according to preconized standard techniques⁸.

Once the nucleoplasty was finished, the patient was sent to his/her room to remain in bed rest, with local cold compresses for about 20 minutes in three-hour breaks, with constipation prevention diet and hospital discharge scheduled for the next 12 hours.

Data collection and statistical analysis

The clinical results were measured by the visual analogical scale (VAS), first on treatment day 1, and then regularly up to a 36-month follow-up, with an average of a one-year follow-up. Statistical analysis was carried out with the Statistical Package for Social Sciences (SPSS) software, version 13.0.

Exploratory analysis used frequencies of categorical variables (age group and disc level) and measures (mean, median, and interquartile range) to describe the continuous variable (VAS). In the association analysis between the different disc levels and the age groups (over or under 45 years-old), the exact test of Fisher was used. The existence of difference in the post-treatment VAS scores between each disc level and age group was verified by the nonparametric Mann-Whitney's test. The use of a nonparametric test had been indicated before by the Kolmogorov-Smirnov test, which rejected the hypothesis of normality in the VAS scores. The p-values lower than 0.05 indicated statistical significance in those tests.

This study was approved by the Ethic Committee Research of the hospital and all patients included signed an informed consent term.

RESULTS

The statistical analysis showed that the most frequent affected level was L4-L5, followed by L5-S1, and then the association L4-L5/L5-S1. The levels L3-L4, L2-L3 and L1-L2 had very low frequency. The best clinical results also came from L4-L5 level. There was no clear relation between age and clinical benefit, as well as the measurement time.

The age distribution among the patients was symmetric: mean age of 45 to 87 years-old, median age of 46, and range of 17 to 79 years-old. All of the 396 patients included answered the post-treatment VAS questionnaire, and the distribution was asymmetric and non-normal, with a mean of 21.29 points, a median of 10 points, and an interquartile range from 0 to 30 points.

The disc level was related to the age group, at a 10% significance level. Discs L2/3, L3/4, L4/5 were more frequently

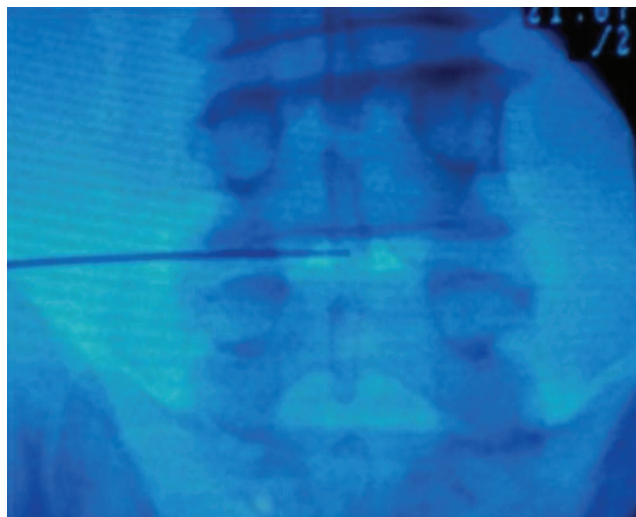


Fig 2. Needle placed at the center of intervertebral L4-L5 disc, anteroposterior incidence.

Table. Complications related to the procedure (396 patients).

| Complications | Patients | Incidence (%) |
|------------------------------------|----------|---------------|
| Radicular paresthesia | 02 | 0.50 |
| Bradycardia | 04 | 1.00 |
| Discitis | 01 | 0.25 |
| Worsening of pain | 01 | 0.25 |
| Convulsive crisis | 01 | 0.25 |
| No improvement after the procedure | 25 | 6.30 |

protruded in the older group, while disc L5/S1 was more protruded in the younger one (under 45 years-old).

The analysis of the distribution of the VAS scores according to the age group and disc levels showed that there was significant difference only in the discs L2/3 and L4/5.

Among all the patients, 26% presented a 100% (complete) pain remission or paresthesia; 13% had a 90% pain improvement; 15% had an 80% pain improvement; and 75% showed at least 50% of pain improvement in the VAS. The median pain improvement was about 67% according to the VAS scores.

There was an incidence of 2% of morbid complications. All bradycardia episodes were related to poor tolerance to minor pain by the patients. There were no complications related to toxic side effects of local anesthetics. The one convulsive episode occurred as a consequence of prolonged pain-induced bradycardia in a patient receiving dexmedetomidine as sedative, which led us to avoid any bradycardia inducing sedatives for this procedure. A total of 25 (6%) patients had no improvements with the treatment. If we also consider 'no improvement' as a type of complication, this provides us an 8% complication rate (Table), which we consider acceptable, and it proves that nucleoplasty is quite a safe procedure when performed by an experienced surgeon, with the anesthesiologist giving sedation on an on-demand basis.

DISCUSSION

Lumbar disc diseases (prolapse, protrusion, or extrusion) account for less than 5% of all low back complains, however they are the most common causes of nerve root pain and surgical interventions⁷. Although the standard treatment for lumbar disc herniation is lumbar microdiscectomy, percutaneous nucleoplasty offers a relatively new technique with encouraging results in well-selected cases, especially if the conservative treatments have failed and the patients are not considered good candidates for open surgery⁹. This procedure is minimally invasive and manages intradiscal herniation through energy-based removal of part of the nucleus pulposus^{6,9-17}.

Few medical or surgical procedures show such a high number of papers with good clinical results as the microdiscectomy for the lumbar disc herniation, which one can describe as the total or partial removal of the intervertebral disc by open microscopic surgery technique¹⁰. Some authors had already shown that patients treated with partial disc removal present the same, if not better, clinical pain improvement compared with total disc removal⁶. It seems that the intradiscal pressure variations in patients with lumbar degenerative disc disease have a close relation with lumbar nociceptive pain by the activation of annular nociceptors, which is similar to the radicular pain caused by root direct compression against neural foramen due to annulus fibrosus insufficiency. The best results were achieved in the inferior lumbar levels, for they bear more weight than the superior ones, with a median improvement of more than four points in the VAS scores.

Percutaneous nucleoplasty complications are directly related to puncture of the disc, the surgeon's expertise as well as to the aseptic procedures care. Infection of the disc can occur, but that can be prevented when the procedure is carried out in a fully equipped surgical room with all the routine care taken for a regular surgery. Lesions of neural and vascular structures are quite rare, but they can also happen. Accidental nerve root lesion or puncture is frequently associated with a reflex increase in the vagal tonus, which may cause profound bradycardia and even asystole. Extreme care should be taken with the needle introduction, which should always be slowly and with the patient frequently being asked about any different symptoms arising. Intradural lesions are

possible if the needle crosses the middle line. There is a risk of abdominal vascular injury if the needle is positioned beyond the limit of the vertebral disc. In order to prevent that, continuous fluoroscopy is mandatory.

Bleeding and infection can follow the introduction of the cannula¹⁸. The most common complications reported by Bhagia et al.¹⁹ at the procedure after 24 hours in 49 patients were: soreness at the needle insertion site in 76%; new numbness in 26%; increased intensity of pre-procedure back pain in 15% and new areas of back pain in 15% of the patients. At two weeks post-procedure, no patient had soreness at the needle insertion site nor new areas of back pain, but new numbness was present in 15% of the patients. Two patients (4%) had increased intensity of the back pain. Many of these complications may be remitted with anti-inflammatory medication²⁰. Anesthetic complications are mainly related to the act of sedating the patient in prone position, which may result in hypoxemia (especially in the obese) and agitation²⁰. It is also important to monitor toxic effects of local anesthetics, respecting the anesthetic dosage limit for each patient. Many of our patients do not receive any sedation, and we generously infiltrate the entire needle route with 1% lidocaine.

The high and growing prevalence of lumbar degenerative disc disease in modern society brings the need for fast, safe, minimally invasive, efficient, and low cost treatment procedures, like nucleoplasty has proved to be^{15,17}. The advantages of this method include percutaneous access, local anesthesia and intravenous sedation, reducing surgery time and avoiding the epidural scarring risk²⁰. This procedure can be repeated at the same level or at adjacent levels and it does not contraindicate the open surgery if it will be considered²⁰.

The authors conclude, from this retrospective analysis of 396 cases, that radiofrequency percutaneous nucleoplasty may be a safe and efficient therapeutic option for patients with leg and lumbar pains, after a conservative treatment (for a period not inferior to 30 days) has failed. The median VAS improvement in inferior disc levels was higher than four points. The VAS showed improvement of the pain and paresthesia in these studied patients, up to a three-year follow-up after the surgical procedure.

Prospective randomized comparative trials are needed to determine its real safety and efficacy. The authors hope to add important evidence to such a common issue in neurosurgical practice.

References

1. Dandy WE. Loose cartilage from intervertebral disk simulating tumor of spinal cord. *Arch Surg* 1929;19:660-672.
2. Gibson JN, Waddell G. Surgical interventions for lumbar disc prolapse. *Cochrane Database Syst Rev* 2007;CD001350.
3. Mixer WJ, Barr JS. Rupture of intervertebral disc with involvement of the spinal canal. *N Engl J Med* 1934;211:210-215.
4. Ascher PW. Status quo and horizons of laser therapy in neurosurgery. *Lasers Surg Medical* 1985;5:499-506.
5. Chen YC, Lee SH, Chen D. Intradiscal pressure study of percutaneous disc decompression with nucleoplasty in human cadavers. *Spine* 2003;28:661-665.
6. Al-Zain F, Lemcke J, Killeen T, Meier U, Eisenschenk A. Minimally

- invasive spinal surgery using nucleoplasty: a 1-year follow-up study. *Acta Neurochir* 2008;150:1257-1262.
7. Manchikanti L, Derby R, Benyamin RM, Helm S, Hirsch JA. A systematic review of mechanical lumbar disc decompression with nucleoplasty. *Pain Physician* 2009;12:561-572.
 8. Gerszten PC, Smuck M, Rathmell JP, et al. Plasma disc decompression compared with fluoroscopy-guided transforaminal epidural steroid injections for symptomatic contained lumbar disc herniation: a prospective, randomized, controlled trial. *J Neurosurg Spine* 2010;12:357-371.
 9. Azzazi A, Almekawi S, Zein M. Lumbar disc nucleoplasty using coblation technology: clinical outcome. *J Neurointerv Surg* 2011;3:288-292.
 10. Yasargil MG. Microsurgical operations for herniated lumbar disc. *Adv Neurosurg* 1977;4:81-82.
 11. Karaman H, Tufek A, Kavak OG, et al. Effectiveness of nucleoplasty applied for chronic radicular pain. *Med Sci Monit* 2011; 17:461-466.
 12. Gerges FJ, Lipsitz SR, Nedeljkovic SS. A systematic review on the effectiveness of the nucleoplasty procedure for discogenic pain. *Pain Physician* 2010;13:117-132.
 13. Masala S, Massari F, Fabiano S, et al. Nucleoplasty in the treatment of lumbar diskogenic back pain: one year follow-up. *Cardiovasc Intervent Radiol* 2007;30:426-432.
 14. Sharps LS, Isaac Z. Percutaneous disc decompression using nucleoplasty. *Pain Physician* 2002;5:121-126.
 15. Caspar W, Campbell B, Barbier DD, Kretschmer R, Gotfried Y. The Caspar microsurgical discectomy and comparison with a conventional standard lumbar disc procedure. *Neurosurgery* 1991;28:78-87.
 16. Singh V, Piryani C, Liao K, Nieschulz S. Percutaneous disc decompression using coblation (nucleoplasty) in the treatment of chronic discogenic pain. *Pain Physician* 2002;5:250-259.
 17. Sinan T, Sheikh M, Buric J, Dashti K, Al-Mukhaimi A. Percutaneous coblation nucleoplasty in patients with contained lumbar disc prolapse: 1 year follow-up in a prospective case series. *Acta Neurochir I* 2010;108:S107-S112.
 18. Rathmell JP, Saal JS, Saal J. Discography, IDET, percutaneous discectomy, and nucleoplasty: complications and their prevention. *Pain Medicine* 2008;9:S73-S81.
 19. Bhagia S, Slipman CW, Nirschl M, et al. Side effects and complications after percutaneous disc decompression using coblation technology. *Am J Phys Med Rehabil* 2006;85:6-13.
 20. Adam D, Pevzner E, Gepstein R. Nucleoplasty. *Roman Neurosurgery* 2010;17:159-165.