

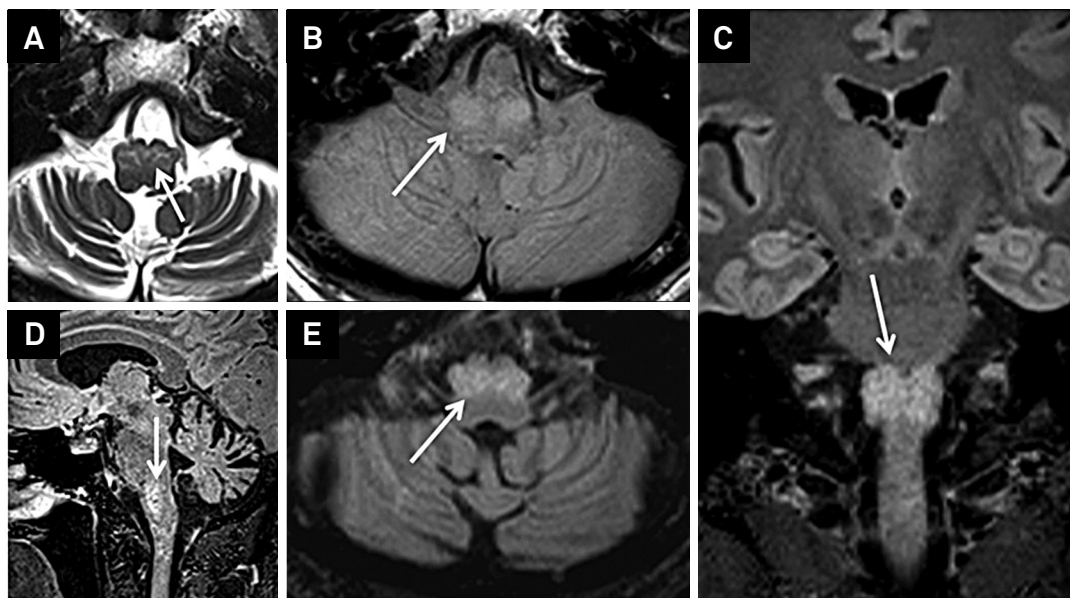
# Neuroimaging features of progressive ataxia and palatal tremor

Achados de neuroimagem da ataxia progressiva com tremor palatal

José Luiz Pedrosa<sup>1</sup>, Wladimir Bocca Vieira de Rezende Pinto<sup>1</sup>, Paulo Victor Sgobbi de Souza<sup>1</sup>, René Leandro Magalhães Rivero<sup>2</sup>, Orlando Graziani Povoas Barsottini<sup>1</sup>

A 56-year-old man complained about a 6-year-history of gait disturbance and bilateral tinnitus. His neurological family history was unremarkable. Physical examination disclosed gait ataxia, slowly horizontal saccadic pursuit and a 2Hz frequency palatal tremor. Neuroimaging unveiled inferior olivary complex hypertrophy bilaterally and mild cerebellar atrophy

(Figure), highly suggestive of progressive ataxia and palatal tremor (PAPT). PAPT represents a rare idiopathic neurodegenerative disease characterized mainly by progressive cerebellar ataxia, variable bulbar dysfunction and symptomatic palatal tremor<sup>1</sup> with the peculiar neuroimaging finding of hypertrophy and variable hyperintensity of the inferior olivary complex<sup>2</sup>.



**Figure.** Different brain MRI sequences (A-E) showing cerebellar atrophy and bilateral hypertrophy with hyperintensities of the inferior olivary complex (white arrows), a frequently described finding in sporadic tremor ataxia and palatal tremor (PAPT).

## References

1. Brinar VV, Barun B, Zadro I, Ozretic D, Habek M. Progressive ataxia and palatal tremor. *Arch Neurol*. 2008;65(9):1248-9. <http://dx.doi.org/10.1001/archneur.65.9.1248>
2. Samuel M, Torun N, Tuite RJ, Sharpe JA, Lang AE. Progressive ataxia and palatal tremor (PAPT): clinical and MRI assessment with review of palatal tremors. *Brain*. 2004;127(6):1252-68. <http://dx.doi.org/10.1093/brain/awh137>

<sup>1</sup>Universidade Federal de São Paulo, Unidade de Ataxia, Departamento de Neurologia e Neurocirurgia, São Paulo SP, Brazil;

<sup>2</sup>Universidade Federal de São Paulo, Departamento de Radiologia, São Paulo SP, Brazil.

**Correspondence:** Wladimir Bocca Vieira de Rezende Pinto; Departamento de Neurologia e Neurocirurgia, UNIFESP; Rua Pedro de Toledo, 650; 04023-900 São Paulo SP, Brasil. E-mail: wladimirbvrpinto@gmail.com

**Conflict of interest:** There is no conflict of interest to declare.

Received 05 July 2014; Received in final form 19 January 2015; Accepted 06 February 2015.