

## RECURRENT SPINAL ADHESIVE ARACHNOIDITIS

### A CASE REPORT

JAMES PITÁGORAS DE MATTOS \* — CHARLES ANDRÉ \*  
BERNARDO ANTONIO MURTINHO COUTO \*

---

**SUMMARY** — Spinal adhesive arachnoiditis is not an uncommon disease, usually having a monophasic course. We studied an atypical patient with recurrent spinal adhesive arachnoiditis nine years after intrathecal anesthesia and the first attack of the disease. Also noteworthy was the favorable evolution after surgery.

**Aracnoidite adesiva medular recidivante: registro de caso.**

**RESUMO** — Aracnoidite adesiva medular não é doença incomum e habitualmente apresenta-se com curso monofásico. Estudamos o caso atípico de paciente com aracnoidite adesiva medular recidivante nove anos após raqui-anestesia e do primeiro episódio da doença. Também é digno de nota a evolução favorável que se seguiu após conduta neurocirúrgica.

---

Spinal adhesive arachnoiditis (ASA) affects preferentially adults of both sexes, most often following intraspinal use of various agents, being thus an important medical social problem. Its course is usually monophasic either progressing unrelentlessly or stabilizing, and even recovering to a variable degree. We report a case with atypical evolution, consisting of prolonged remission followed by a second subacute attack nine years later.

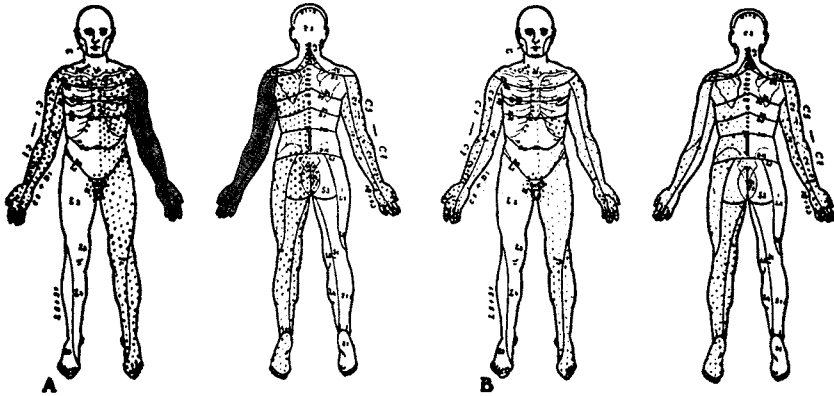
### CASE REPORT

A Caucasian man 33 years old had an unremarkable clinical history until age 24. One day after being submitted to intrathecal anesthesia for a postectomy, he developed progressive paraparesis, fecal and urinary incontinence and sexual impotence. Four months later he was paraplegic. A myelographic diagnosis of ASA was made, and the patient was treated with 21 cisternal injections of Depo-Medrol (R.) followed by prednisone in low oral doses, without benefit. The course remained stable for six months, followed by slight bilateral arm weakness. The patient then started an intensive physiotherapy program. During the following year he recovered almost to normal, regaining muscular power and sphincteric continence. The patient got married and had a child, now 19 months old. He was doing quite well until one month before admission, when sphincteric incontinence, sexual impotence and tetraparesis of rapid evolution all recurred, along with paresthesias around the cervical column. Several lumbar punctures were tried unsuccessfully, and the patient was treated with parenteral dexamethasone, without benefit. Past medical history disclosed hilar tuberculosis during adrenocorticosteroid therapy, which was discontinued, four years ago. The patient was treated successfully with para-aminosalicylic acid, streptomycin and isoniazid for one year. Three years ago, he had acute viral hepatitis, with total resolution and

---

\* Instituto de Neurologia Deolindo Couto, Federal University of Rio de Janeiro.

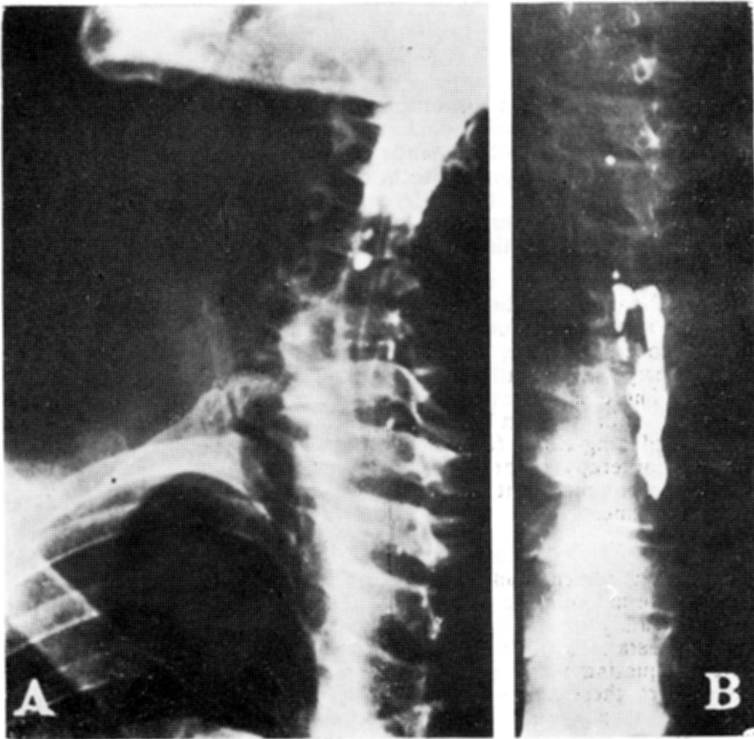
without sequellae. General physical examination was unremarkable. Neurological examination disclosed, at inspection, shoulder-girdle fasciculations and amyotrophy, specially of the left limbs. There were also bilateral foot drop and left side hypothermia. Upright posture was possible only with aid, and supported gait was parietataxic. There was tetraparesis, with muscular power more markedly reduced in distal segments and at the right side. Tonus was increased in both legs and the right arm, and reduced in the left arm. The four limbs were ataxic, with obvious deterioration after eye closure. Superficial reflexes were abolished, and Babinski sign was present bilaterally. Muscle stretch reflexes were brisk at the right side and abolished at the left one. Patellar and ankle clonus were readily



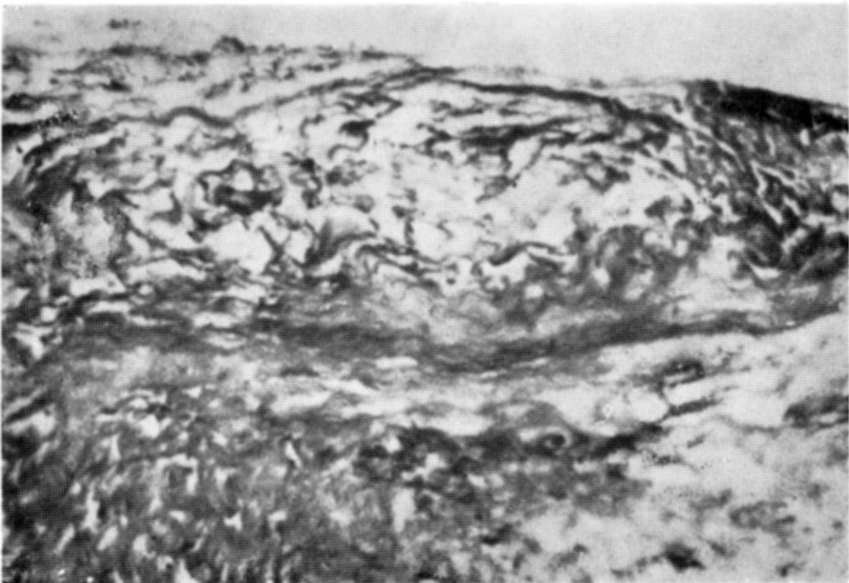
*Fig. 1 — Cutaneous sensation chart. A, at admission: left arm anesthesia with hypoesthesia of the right arm and the left side. B, postoperative period: note the partial relieve of cutaneous anesthesia of the left limb.*

elicited at the right side. Cutaneous sensation was altered (Fig. 1A). Deep sensation was bilaterally reduced in the lower limbs. There were fecal and urinary incontinence. Cranial nerves and mental status were normal. Syphilis screening tests were negative as were normal routine studies, except for mild pyuria and hematuria. Cerebrospinal fluid (CSF) obtained by cisternal puncture revealed 1.4 cells and total protein level of 13mg per mm<sup>3</sup>, with negative V.D.R.L. and globulin qualitative tests. Radiological examination of the cranium, vertebral column and thorax was normal, except for the presence of minute residual amounts of liposoluble contrast agent in the cervical column and at the base of the skull. Cisternal descending and lumbar ascending myelographies showed total obstruction to contrast flow at the mid-cervical and mid-thoracic levels respectively (Fig. 2). Partial obstruction and typical candle-guttering appearance were also present in a lumbar myelography done nine years before, specially at the thoracic level.

With an assumed diagnosis of ASA, and considering the rapid deterioration and total CSF block, the patient was submitted to cervical laminectomy from C<sub>3</sub> to C<sub>5</sub> with extensive release of adhesions and exploration of the spaces immediately above and below (Fig. 3). Following surgery, the patient was treated with parenteral dexamethasone for 20 days, and was started on a physiotherapy and rehabilitation program. By the third day he referred slight recovery of muscular power and equilibrium. Sphincteric control was partial on the fifth day and total on the ninth day. Reexamination in the seventh postoperative day disclosed disappearance of myofasciculations and great relief of limb hypothermia. Muscular power improved, specially in the lower limbs. Hypertonus was relieved but left arm hypotonia was unaltered. Ataxia was less evident, specially at the right side. Patellar and ankle jerks in the left side returned, brisk and reduced respectively. Clonus could not be elicited anymore. Left arm sensation also reappeared, although still reduced (Fig. 1B). The patient was discharged in the fifteenth post operative day, and traveled to his native town. After two months, he reported on the telephone that he was presenting progressive recovery, without any medication and still doing his best in the rehabilitation program.



*Fig. 2 — Myelographic findings. A, total obstruction of the cervical canal at the C<sub>3</sub> level. B, typical candel-guttering of the dye and total spinal block at the mid-thoracic level.*



*Fig. 3 — Photomicrograph of surgical material: great connective tissue overgrowth resulting in thickening of arachnoid membranes, without any evidence of arachnoid inflammation. (Gomori trichrome; original magnification OC 10 $\times$ , OBJ 24 $\times$ ).*

## COMMENTS

The introduction of spinal anesthesia in the first half of this century was soon followed by experimental studies and case reports of its potential neurological complications. Among these, ASA stands out as a potentially preventable disease<sup>9</sup>, usually related to either direct toxic effects or late immune reaction to the administered drugs. Causal agents may be the different anesthetics per se<sup>2</sup>, contaminant residues of detergents used in the sterilizing process of syringes and vials of anesthetic solutions<sup>3</sup>, or a synergistic action of both substances<sup>6</sup>.

Surgical management of spinal adhesive arachnoiditis is restricted, as in this case, to disease of rapid evolution, specially in the presence of signs of a progressive lesion in a limited region with documented spinal block<sup>7</sup>. Systemic adrenocorticosteroids are also of controversial value, but widely used in cases of recent onset and rapid evolution. Obviously, its intrathecal use following the first attack was ineffective, if not harmful. There is increasing evidence that these drugs may cause potentially serious meningeal inflammation<sup>1,8</sup>. Long-action drugs of this class possess polyethylene glycol and long-chain fatty acids, thought to be responsible for this effect<sup>5</sup>. The role of physiotherapy in promoting a favorable evolution is difficult to evaluate, although it was an important factor in maintaining the motivation and patient commitment to treatment.

This report of a single case of ASA is justified by its atypical, biphasic course with long remission, which was never found among patients previously admitted to our institution. The monophasic evolution of the disease is well documented<sup>3,10</sup>. It may either progress steadily or remit with sequella of variable degrees. In a study of the radiological manifestations of the disease, Lombardi et al.<sup>4</sup> disagree with this general view, specifically quoting many cases of remission, even for long periods. Meanwhile, they do not report these cases and paradoxically mention the serious evolution of their ten nonsurgical patients. Further, they specifically excluded the postanesthetic group of patients from the study. Anyway, this case report should attract attention of neurologists to our poor knowledge of the natural history of remitting ASA. We probably should be a little more cautious in stating the long-term prognosis of patients who have an initial good outcome, until studies are made which specifically address this matter.

## REFERENCES

1. Bernat JL — Intraspinial steroid therapy. *Neurology* 31:168, 1981.
2. Davis L, Haven H, Givens JH, Emmett J — Effects of spinal anesthetics on the spinal cord and its membranes. *JAMA* 97:1781, 1931.
3. Kennedy F, Efron AS, Perry G — The grave spinal cord paralyzes caused by spinal anesthesia. *Surg Gynecol Obstet* 91:385, 1950.
4. Lombardi G, Passerini A, Migliavacca F — Spinal arachnoiditis. *Br J Radiol* 35:314, 1962.
5. Margolis G, Hall HE, Nowill WK — An investigation of Efocaine, a long-acting local anesthetic agent: I. Animal studies. *Arch Surg* 67:715, 1953.
6. Paddison RM, Alpers BJ — Role of intrathecal detergents in pathogenesis of adhesive arachnoiditis. *Arch Neurol Psychiat* 71:87, 1954.
7. Plum F, Olson ME — Myelitis and myelopathy. In Baker AB & Baker LH, eds: *Clinical Neurology*. Harper & Row, Philadelphia, 3:1, 1981.
8. Sehgal AD, Tweed DC, Gardner WJ — Laboratory studies after intrathecal steroids. *Arch Neurol* 9:64, 1963.
9. Vandam LD, Dripps RD — Exacerbation of pre-existing neurologic disease after spinal anesthesia. *N Engl J Med* 255: 843, 1956.
10. Winkelman NW — Neurologic symptoms following accidental intraspinal detergent injection. *Neurology* 2:284, 1952.