

The remarkable pioneering contribution of Gaspar Vianna to the study of the neuropathology of Chagas disease

A notável contribuição pioneira de Gaspar Vianna para o estudo da neuropatologia da doença de Chagas

José Eymard Homem Pittella¹

ABSTRACT

Gaspar Vianna is considered one of the great names in Medicine and Science in Brazil. Yet, little prominence has been given to his studies in Neuropathology. He was the first to describe, in 1911, the histopathology and pathogenesis of chagasic encephalitis in the acute phase of Chagas disease, as well as the intracellular life cycle of *Trypanosoma cruzi*. Over 100 years have elapsed and Gaspar Vianna's pioneering study remains an example of a meticulous and still up-to-date description of central nervous system involvement in the acute phase of Chagas disease.

Keywords: Chagas disease; neuropathology; history.

RESUMO

Gaspar Vianna é considerado um dos grandes nomes da Medicina e da Ciência no Brasil. Contudo, pouco destaque tem sido dado aos seus estudos em Neuropatologia. Ele foi o primeiro a descrever a histopatologia e a patogênese da encefalite chagásica na fase aguda da doença de Chagas, bem como o ciclo evolutivo intracelular do *Trypanosoma cruzi*, em 1911. Passados mais de 100 anos, o estudo pioneiro de Gaspar Vianna permanece como exemplo de descrição minuciosa e ainda atual do envolvimento do sistema nervoso central na fase aguda da doença de Chagas.

Palavras-chave: Doença de Chagas; neuropatologia; história.

This article describes the remarkable pioneering contribution of Gaspar Vianna to the knowledge of the neuropathology of Chagas disease, as described in one of his works, *Contribuição para o estudo da anatomia patológica da Moléstia de Carlos Chagas*¹ (Contribution to the study of the pathological anatomy of Carlos Chagas disease), published in 1911. Although recognized as one of the great names in Medicine and Science in Brazil^{2,3,4,5,6}, little prominence has been given to his fundamental study on central nervous system (CNS) involvement in the acute phase of Chagas disease.

GASPAR VIANNA – A SHORT BIOGRAPHY

Gaspar de Oliveira Vianna (Figure 1) was born on May 11, 1885, in the city of Belém do Pará³. In 1903,

shortly before turning 18, he moved to Rio de Janeiro and enrolled in the Faculty of Medicine. In 1907, still a student, Gaspar Vianna was assigned as an assistant to Bruno Álvares da Silva Lobo (1884 – 1945), director of the Laboratório Anátomo-Patológico of the Hospital Nacional de Alienados, working under the supervision of psychiatrist Juliano Moreira (1873 – 1933), the hospital's director. After his graduation from medical school in 1908, although asked by Juliano Moreira to continue his work at the Laboratório Anátomo-Patológico, Gaspar Vianna chose to accept an invitation, in 1909, from Oswaldo Cruz (1872 – 1917), to work in the pathologic anatomy sector of the Instituto Oswaldo Cruz. In the period between 1909 and 1914, the tirelessly hard-working scientist published 21 works, reporting notable findings in the areas of protozoology, microbiology, pathologic anatomy, and

¹Universidade Federal de Minas Gerais, Faculdade de Medicina, Departamento de Anatomia Patológica e Medicina Legal, Belo Horizonte MG, Brasil.

Correspondence: José Eymard Homem Pittella; Av. Winter Bianchardi, 269, Condomínio Jardim dos Flamboyants; 14805-294 Araraquara SP, Brasil; E-mail: jehpittella@hotmail.com

Conflict of interest: There is no conflict of interest to declare.

Received 18 April 2018; Received in final form 18 July 2018; Accepted 18 September 2018.



chemotherapy³. Gaspar Vianna died on June 15, 1914, at the premature age of 29, as a result of an acute tuberculosis infection acquired while performing an autopsy on an infected patient.




Figure 1. Gaspar Vianna (1885-1914) at the Instituto Oswaldo Cruz. Reproduced from reference 2 with the permission of the editor of the Memórias do Instituto Oswaldo Cruz.

HISTOPATHOLOGY AND PATHOGENESIS OF CHAGASIC ENCEPHALITIS

Following the clinical description, in 1909⁷, of the new human disease caused by *Trypanosoma cruzi*, Carlos Chagas (1879-1934) invited Gaspar Vianna to write a histopathologic description of this new entity. Working hard and with dedication, Gaspar Vianna studied organ specimens from 10 patients autopsied by Carlos Chagas, one of whom, a three-month-old infant, was the first fatal case in the acute phase of the disease. His findings were published in 1911¹. Below is a summary of the description by Gaspar Vianna of the chagasic encephalitis observed in the three-month-old infant.

Irregularly distributed inflammatory foci of leukocytic infiltration of variable size were seen in all examined regions of the CNS. The parasite, round-shaped, and containing a nucleus and a kinetoplast (amastigote form), was identified in variable numbers in many of the inflammatory foci, sometimes distending the parasitized cell. Based on the position of the parasitized cell in the nerve tissue, the structure of its nucleus, and its relation to the other components of this tissue, the author concluded that the parasitized cell was a neuroglial cell.

Parasite multiplication occurs by successive binary divisions of the amastigotes, followed by transformation of these into trypomastigotes, still inside the parasitized cell.

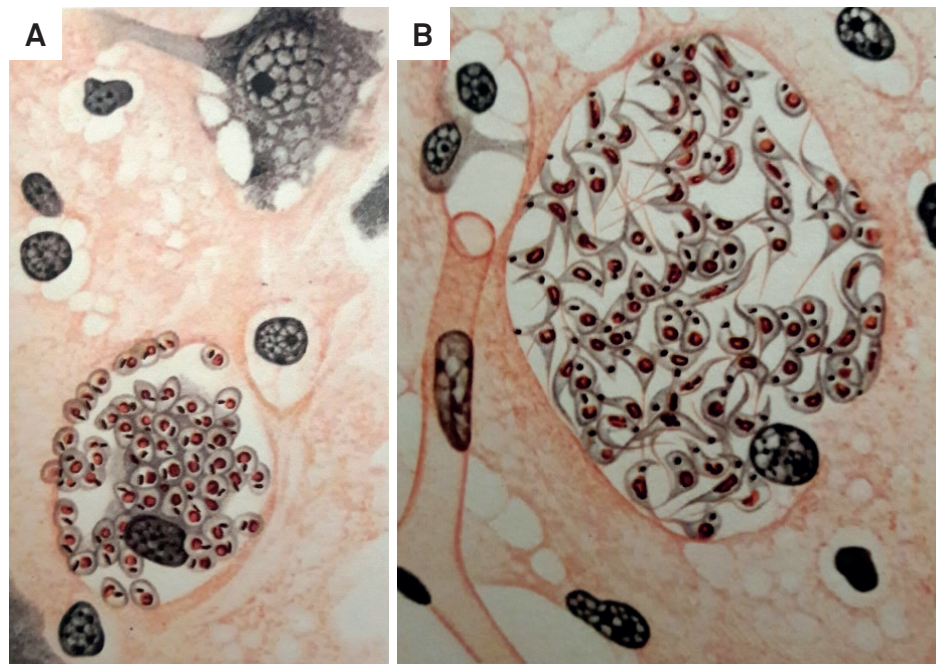


Figure 2. A. Chagasic encephalitis. A neuroglial cell distended by numerous amastigotes (parasites containing a nucleus and a kinetoplast). The nucleus of the parasitized cell is observable amidst the parasites. A neuron can be seen in the upper part of the figure. Reproduced from reference 1 with the permission of the editor of the Memórias do Instituto Oswaldo Cruz. B. Chagasic encephalitis. Neuroglial cell distended by a few amastigotes and numerous trypomastigotes (parasites containing a nucleus, a kinetoplast, and a flagellum). The nucleus of the parasitized cell is observable in the lower right of the figure. Reproduced from reference 1 with the permission of the editor of the Memórias do Instituto Oswaldo Cruz.

With rupture of the parasitized cell membrane, the trypomastigotes are released and become capable of invading other cells. It is upon rupture of the parasitized cell membrane that the inflammatory reaction is observed, leading to progressive disappearance of the parasite in these foci. Also found are cells containing a large number of parasites, but with no inflammatory reaction surrounding them, a finding that, according to the author, corresponds to the early phases of CNS involvement in Chagas disease (Figure 2).

Over 100 years have elapsed, but very little has been added to Gaspar Vianna's observations⁸. Chagasic encephalitis is characterized by multiple foci of microglia, macrophages, and neutrophils arranged in a nodular pattern ("microglial nodes"). When examined under an electron microscope, the amastigote nests are located within the cellular bodies and astrocyte processes, indicating that these are the main target cells for *T. cruzi*⁹ invasion and proliferation. The perivascular arrangement of the astrocyte processes could facilitate invasion by the parasite.

The pathogenesis of CNS involvement, as described by Gaspar Vianna, was confirmed by subsequent studies. It consists of an inflammatory reaction produced by rupture of the membrane of the parasitized cells. Macrophages from the blood or activated microglia, along with neutrophilic granulocytes, are the cells responsible for phagocytosis and removal of the parasites. Kinetic studies of experimental *T. cruzi* infection in rats show that the greater number of microglial nodes occurs one week after the finding of an increased number of amastigote nests, indicating that the microglial nodes are a reaction to the rupture of the parasitized cells⁹. The inflammatory nodes tend to disappear as the acute phase ends.

The first case of chagasic encephalitis in a chronic chagasic patient with chronic lymphocytic leukemia (reactivated acute form)¹⁰ was described in 1969. Other cases in immunodeficient individuals were subsequently reported, particularly after the emergence of AIDS in 1981, many of whom presented with the tumoral form of the disease (brain *chagoma*). This form is characterized by multifocal necrotizing encephalitis, abundant amastigotes within astrocytes, apart from isolated forms dispersed through the cerebral parenchyma, microglial nodules, and exudates of macrophages, lymphocytes and plasma cells and, to a lesser degree, neutrophilic granulocytes within the nerve tissue and perivascular spaces⁹.

These pathological changes can also be explained by the pathogenic mechanism proposed by Gaspar Vianna in 1911. In immunocompetent individuals, a robust cellular and humoral immune response controls parasite replication during the acute phase¹¹. However, if for any reason the immune system fails, reactivation of the acute phase may occur: the amastigotes will be able to reproduce, differentiate into bloodstream trypomastigotes that are released upon rupture of the host cell membrane, and extensively invade the neighboring cells, which may result in necrosis of the nerve tissue, producing the brain *chagoma*.

Gaspar Vianna deserves prominence as a rare example of a scientist who, in a single publication involving the study of a single patient, made such an important contribution to the knowledge of new aspects of a new human disease that had been discovered only two years earlier. Also remarkable is that his description of the intracellular life cycle of *T. cruzi*, and the histopathology and pathogenesis of CNS involvement in *T. cruzi* infection remains accurate and up to date.

References

- Vianna G. Contribuição para o estudo da anatomia patológica da "Moléstia de Carlos Chagas": esquizotripanose humana ou tireoidite parasitária. Mem Inst Oswaldo Cruz. 1911;3(2):276-94. <https://doi.org/10.1590/S0074-02761911000200004>
- Dr. Gaspar de Oliveira Vianna. Mem Inst Oswaldo Cruz. 1914;6(2):I-III. <https://doi.org/10.1590/S0074-02761914000200001>
- Falcão EC. Opera Omnia de Gaspar Vianna. São Paulo: Empresa Gráfica da Revista dos Tribunais; 1962.
- Deane LM. Gaspar Vianna, no centenário de seu nascimento. Mem Inst Oswaldo Cruz. 1985 Apr-Jun;80(2):253-5. <https://doi.org/10.1590/S0074-02761985000200020>
- Fraiha Neto H. O centenário de nascimento de Gaspar Vianna. Rev Soc Bras Med Trop. 1986 Apr-Jun;19(2):111-3. <https://doi.org/10.1590/S0037-86821986000200013>
- Suassuna I. Brasileiros pioneiros na história da microbiologia médica 2. Gaspar Vianna (1885-1914). Rev Para Med. 2006;20(2):71-3.
- Chagas C. Nova tripanossomíase humana: estudos sobre a morfologia e o ciclo evolutivo do *Schizotrypanum cruzi* n. gen., n. sp., agente etiológico de nova entidade mórbida do homem. Mem Inst Oswaldo Cruz. 1909;1(2):159-218. <https://doi.org/10.1590/S0074-02761909000200008>
- Pittella JEH. Central nervous system involvement in Chagas disease: a hundred-year-old history. Trans R Soc Trop Med Hyg. 2009 Oct;103(10):973-8. <https://doi.org/10.1016/j.trstmh.2009.04.012>
- Da Mata JR, Camargos MR, Chiari E, Machado CR. *Trypanosoma cruzi* infection and the rat central nervous system: proliferation of parasites in astrocytes and the brain reaction to parasitism. Brain Res Bull. 2000 Sep;53(2):153-62. [https://doi.org/10.1016/S0361-9230\(00\)00326-9](https://doi.org/10.1016/S0361-9230(00)00326-9)
- Mattosinho-França LC, Fleury RN, Ramos Junior HA, Lemos S, Melaragno Filho R, Pasternak J. Moléstia de Chagas crônica associada a leucemia

linfática: ocorrência de encefalite aguda como alteração do estado imunitário [in Portuguese]. *Arq Neuropsiquiatr.* 1969;27(1):59-66. <https://doi.org/10.1590/S0004-282X1969000100005>

11. Machado FS, Dutra WO, Esper L, Gollob KJ, Teixeira MM, Factor SM et al. Current understanding of immunity to *Trypanosoma cruzi* infection and pathogenesis of Chagas disease. *Semin Immunopathol.* 2012 Nov;34(6):753-70. <https://doi.org/10.1007/s00281-012-0351-7>