

Neurocysticercosis presenting with stroke

Humberto Castro-Lima, Irina Raicher,
Hae Won Lee, Paulo Euripedes Marchiori

A 59 years old woman with arterial hypertension presented, for the last six months, depression, memory complaints, gait disturbance and frequent falls. One day prior to hospitalization, she had difficulty to move the left side of her body. Neurological examination revealed Mini-Mental State Examination (MMSE) 22/30, left hemiparesis with hyperactive reflexes and Babinski sign. MRI showed a ischemic le-

sion in right hemisphere, as well as hydrocephalus, and multiple cystic lesions suggestive of neurocysticercosis. Cerebrospinal fluid analysis showed 46 cells (1% eosinophils), protein 205 mg/dL, glucose 10 mg/dL, ADA 10 IU and cysticercosis immunoenzymatic test (ELISA) positive. She received dexametasone and underwent ventriculoperitoneal derivation with a good response.

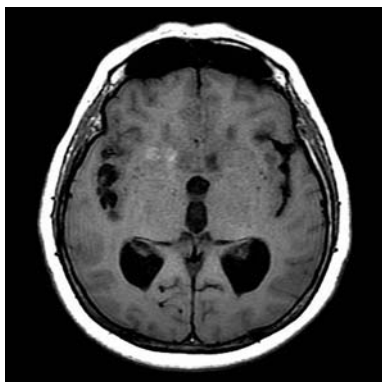


Fig 1. T1-weighted image showing hypointense lesions suggestive of cystic lesions.

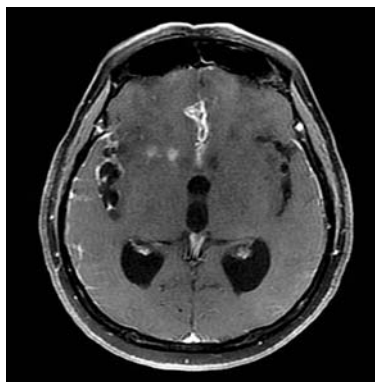


Fig 2. Contrasted T1-weighted image showing inflammation with contrast enhancement.

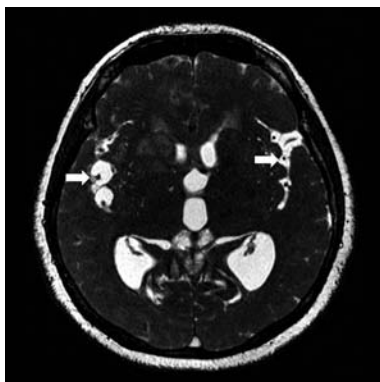


Fig 3. Fiesta sequence. White arrows point to branches of middle cerebral artery (between cysts in the right side).

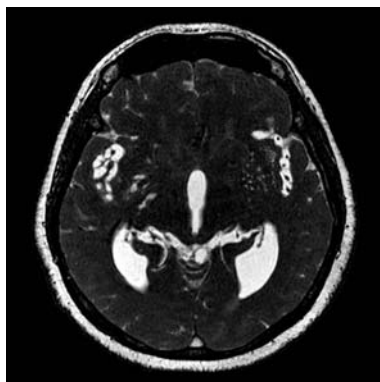


Fig 4. Fiesta sequence showing blood vessels occlusion (right side).

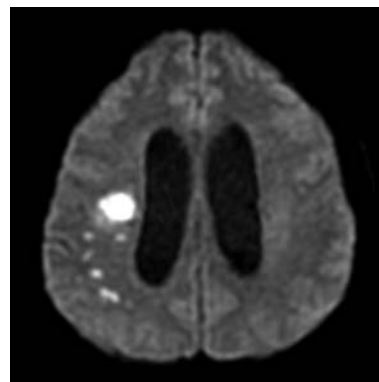


Fig 5. Diffusion sequence showing restricted diffusion lesion in right hemisphere, characteristic of stroke.

Correspondence

Irina Raicher
Rua Prof Filadelfo de Azevedo 555
04508-011 São Paulo SP - Brasil
E-mail: iriraicher@gmail.com

Received 20 November 2009
Accepted 14 December 2009

NEUROCISTICERCOSE APRESENTANDO-SE COMO ACIDENTE VASCULAR CEREBRAL

Department of Neurology and Institute of Radiology, Medicine School, University of São Paulo, São Paulo SP, Brazil.