

# Convexity subarachnoid hemorrhage: clinical features and etiology of an Argentinian cohort

## Hemorragia subaracnóidea da convexidade: características clínicas e etiologia de uma coorte argentina

Aníbal Chertcoff<sup>1</sup>, Lucrecia Bando<sup>1</sup>, Fátima Pantiu<sup>1</sup>, Luciana León Cejas<sup>1</sup>, Sol Pacha<sup>1</sup>, Claudia Uribe Roca<sup>1</sup>, Manuel Fernández Pardal<sup>1</sup>, Ricardo Reisin<sup>1</sup>, Pablo Bonardo<sup>1</sup>

### ABSTRACT

Nontraumatic convexity subarachnoid hemorrhage is an increasingly recognized subtype of subarachnoid bleeding. **Objective:** Our aim was to describe the etiology and clinical features of a cohort of patients with convexity subarachnoid hemorrhage. **Methods:** We retrospectively analyzed all cases of convexity subarachnoid hemorrhage admitted to our hospital between January 2012 and April 2017. Demographic features, clinical characteristics, complementary investigations, etiology and mortality were assessed. Twenty patients (65% females) were identified. Mean age: 53 years (range, 15-86 years). **Results:** Symptoms on admission: headache (65%), sensory and/or motor symptoms (50%) and seizures (35%). Commonest causes: cerebral vein thrombosis (20%), reversible cerebral vasoconstriction syndrome (20%) and cerebral amyloid angiopathy (20%). Two patients died. **Conclusion:** Convexity subarachnoid hemorrhage may be related to a wide spectrum of etiologies. In our patients, an increased prevalence of cerebral vein thrombosis was observed. Mortality was low and not related to the bleeding itself.

**Keywords:** cerebral amyloid angiopathy, etiology; sinus thrombosis, intracranial; subarachnoid hemorrhage.

### RESUMO

A hemorragia subaracnóidea não traumática da convexidade é um subtipo cada vez mais reconhecido de sangramento subaracnóideo. **Objetivo:** Nosso objetivo foi descrever a etiologia e as características clínicas de uma coorte de pacientes com hemorragia subaracnóidea da convexidade. **Métodos:** Foram analisados retrospectivamente todos os casos de hemorragia subaracnóidea da convexidade admitidos em nosso hospital entre janeiro de 2012 e abril de 2017. Foram avaliados os aspectos demográficos, características clínicas, investigações complementares, etiologia e mortalidade. Vinte pacientes (65% mulheres) foram identificados. Média de idade: 53 anos (intervalo, 15-86). **Resultados:** Sintomas na admissão: dor de cabeça (65%), sintomas sensitivos e/ou motores (50%) e convulsões (35%). Causas mais comuns: trombose venosa cerebral (20%), síndrome de vasoconstrição cerebral reversível (20%) e angiopatia amilóide cerebral (20%). Dois pacientes morreram. **Conclusão:** A hemorragia subaracnóidea da convexidade pode estar relacionada a um amplo espectro de etiologias. Em nossos pacientes, observou-se uma maior prevalência de trombose venosa cerebral. A mortalidade foi baixa e não relacionada à própria hemorragia.

**Palavras-chave:** angiopatia amilóide cerebral, etiologia; trombose dos seios intracranianos; hemorragia subaracnóidea.

Nontraumatic nonaneurysmal convexity subarachnoid hemorrhage (cSAH) is an increasingly recognized subtype of subarachnoid bleeding localized in one or more cortical sulci of the brain without involvement of the neighboring parenchyma or extension to the interhemispheric fissure, basal cisterns or ventricles<sup>1</sup>. These features help to distinguish cSAH from aneurysmal bleeding and nontraumatic perimesencephalic subarachnoid hemorrhage. Recently, many case series have described the clinical features, etiology and outcome of this entity although information concerning Latin American populations is scarce<sup>2</sup>. We therefore consider it valuable to describe the etiology and clinical features of cSAH in a hospital-based Argentinian cohort.

### METHODS

All consecutive patients admitted to our hospital with nontraumatic nonaneurysmal subarachnoid hemorrhage, evaluated by the Department of Neurology from January 2012 to April 2017, were identified from hospital records. Patients with evidence of blood in the interhemispheric fissures, basal cisterns or adjacent brain parenchyma were excluded. Demographic features, clinical characteristics, complementary investigations, etiology and mortality were retrospectively assessed. Diagnosis of cerebral amyloid angiopathy (CAA) was performed according to the modified Boston

<sup>1</sup>Hospital Británico de Buenos Aires, Department of Neurology, Perdriel, Buenos Aires, Argentina.

**Correspondence:** Aníbal Chertcoff; Department of Neurology, Hospital Británico de Buenos Aires; Perdriel 74, 1280, Buenos Aires, Argentina; E-mail: anibalchertcoff@gmail.com

**Conflict of interest:** There is no conflict of interest to declare.

Received 07 May 2017; Received in final form 17 August 2017; Accepted 25 September 2017.

criteria<sup>3,4</sup>. Reversible cerebral vasoconstriction syndrome (RCVS) was diagnosed under current criteria<sup>5</sup>. All other diagnoses were recorded in accordance to medical records. The ethics committee of the institution approved the study.

We identified 31 patients with cSAH. Six were excluded due to cisternal, interhemispheric or adjacent parenchymal bleeding. Information on five patients was missing. Accordingly, data from 20 patients was analyzed. The Figure shows representative images of cSAH. The demographics and medical history of our population is summarized in Table 1. Thirteen (65%) were females. The mean age was 53 years (range: 15–86 years). The most common comorbid conditions were arterial hypertension and dyslipidemia (30% and 25% respectively). Only two patients had a history of previous cerebrovascular disease: one had an ischemic stroke and the second an intracerebral hemorrhage and the second an intracerebral hemorrhage. Two patients had acute oncohematological diseases at cSAH presentation. Four patients were taking antiplatelets, one was on oral anticoagulation and one received vasoconstrictors (ergotamine and pseudoephedrine).

## RESULTS

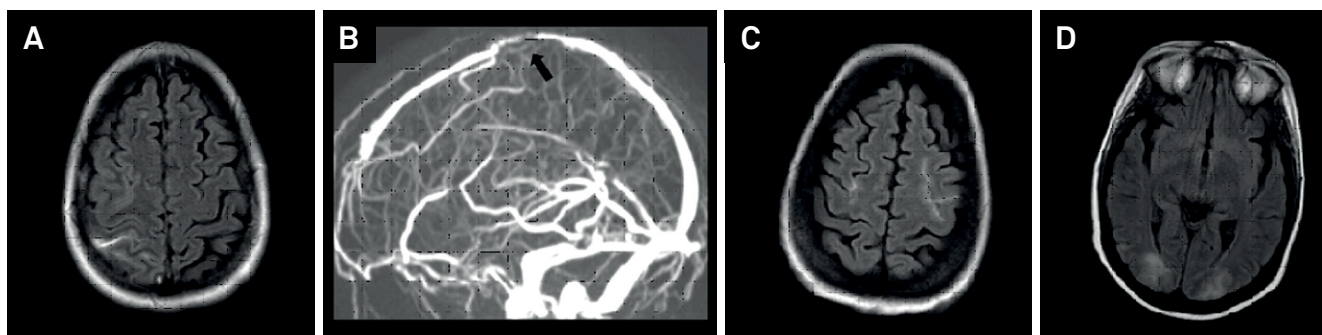
Results are summarized in Table 2. A comparison with recent series is performed.

### Clinical features

The most common presenting symptom was headache in 13 patients. Among these, thunderclap headache was reported in five. Four had progressive and severe headache and four had mild headache. Other frequent symptoms were sensory-motor symptoms in 10 patients and seizures in seven.

### Complementary investigations

Nineteen patients had a head CT scan. Brain MRI with MR-angiography was performed in 19 patients. Seven patients underwent conventional brain angiogram and two had a CT-angiography. Regarding the localization of the subarachnoid hemorrhage, frontal lobe was the most frequently affected in 15 patients, parietal lobe in six, occipital in six and temporal in three. Ten patients had bilateral bleeding.



**Figure.** Representative images of cSAH. A, B: MRI (Axial FLAIR sequence) of a 35-year-old female with headache and seizures due to cerebral vein thrombosis with right frontal cSAH. MR-venography exhibited partial thrombosis of the superior sagittal sinus (arrow). C, D: MRI (Axial FLAIR sequence) of a 40-year-old female with acute myeloid leukemia and bilateral cSAH due to posterior reversible encephalopathy syndrome. This patient died due to underlying disease.

**Table 1.** Demographics and medical history of 20 patients with convexity subarachnoid hemorrhage.

Variable	No.
Age, years*	53 ± 20 (15–86)
Female	13
Previous medical history	
Smoking	7
Arterial Hypertension	6
Dyslipidemia	5
Diabetes mellitus	2
Coronary artery disease	3
Previous ischemic stroke	1
Previous intracerebral hemorrhage	2
Current oncohematological disease	2
Current antiplatelet therapy	4
Current oral anticoagulation	1
Current vasoconstrictors use	1

\*values indicate mean ± SD (range); SD: standard deviation

**Table 2.** Clinical characteristics, complementary investigations, etiology and mortality of cSAH.

Variable	Our cohort	Graff-Radford et al. <sup>6</sup>	Bruno et al. <sup>2</sup>	Kumar et al. <sup>1</sup>	Beitzke et al. <sup>7</sup>
Patients	20	88	34	29	24
Age (years)*	53	64	64	58	70
Presenting symptom					
Headache	13 (65%)	37 (42%)	19 (56%)	18 (62%)	10 (42%)
Thunderclap headache	5 (25%)	28 (31%)	17 (50%)	10 (34%)	4 (17%)
Sensory-motor symptoms	10 (50%)	24 (27%)	16 (47%)	8 (27%)	10 (42%)
Seizures	7 (35%)	6 (6%)	3 (9%)	0 (0%)	5 (21%)
Complementary investigations					
Plain head CT	19 (95%)	NA	26 (76%)	29 (100%)	24 (100%)
MRI with MRA	19 (95%)	79 (89%)	34 (100%)	28 (96%)	20 (83%)
CT-angiography	2 (10%)	NA	1 (2%)	14 (48%)	9 (37%)
Conventional angiogram	7 (35%)	NA	27 (79%)	16 (55%)	8 (33%)
cSAH localization					
Frontal	15 (75%)	NA	NA	15 (51%)	NA
Parietal	6 (30%)	NA	NA	6 (20%)	NA
Occipital	6 (30%)	NA	NA	1 (3%)	NA
Temporal	3 (15%)	NA	NA	1 (3%)	NA
Bilateral	10 (50%)	24 (27%)	10 (30%)	5 (18%)	2 (9%)
Diagnosis at discharge					
RCVS	4 (20%)	26 (29%)	13 (38%)	11 (37%)	NA
CAA	4 (20%)	23 (26%)	7 (21%)	10 (35%)	NA
CVT	4 (20%)	4 (4%)	1 (2%)	0 (0%)	NA
Others	8 (40%)	35 (41%)	13 (38%)	8 (28%)	NA
Mortality	2 (10%)	NA	0 (0%)	3 (10%)	5 (20%)

\*values indicate mean. NA: not available, cSAH: convexity subarachnoid hemorrhage. CT: computed tomography; MRI: magnetic resonance imaging; MRA: magnetic resonance angiography, RCVS: reversible cerebral vasoconstriction syndrome, CAA: cerebral amyloid angiopathy, CVT: cerebral vein thrombosis.

## Etiology

The most common causes of cSAH were cerebral vein thrombosis (CVT), RCVS and CAA each one of them in four patients. Other causes were posterior reversible encephalopathy syndrome in two patients, central nervous system vasculitis in two, infectious endocarditis in two, anticoagulation-related in one and undetermined in one patient.

## Mortality

Two patients died. In both cases, cSAH was due to posterior reversible encephalopathy syndrome and both had acute oncohematological diseases. The cause of death was unrelated to the cSAH.

## DISCUSSION

Although several etiologies have been suggested as causes for cSAH, RCVS and CAA seem to be the most frequent in nearly all series. Previous studies have shown that the etiology and the clinical presentation of cSAH is mainly related to age at presentation: younger patients (less than 60 years old) present with headache with a thunderclap pattern commonly due to RCVS and older patients typically complain about sensory-motor symptoms secondary to CAA. Our study showed a higher prevalence of CVT in comparison with other studies<sup>1,2,6,7</sup>. In our population, CVT was as frequent as

RCVS and CAA. Cerebral vein thrombosis is an increasingly recognized cause of cSAH and some authors suggest that this might be related to technological advances made in noninvasive diagnostic radiology during the last decades<sup>8,9</sup>. Another possible explanation may be that our cohort was younger than other series and had a female predominance; CVT is more frequent in such populations<sup>10</sup>. Likewise, we think that the higher frequency of seizures reported in our series was also probably related to the increased prevalence of CVT. Regarding clinical presentation in CAA and RCVS patients, two out of four patients with CAA presented with transient paresthesias commonly known as 'amyloid spells'<sup>11</sup>. Three out of four patients with RCVS experienced thunderclap headache. Only one CAA patient presented with headache but it was described as mild.

Concerning diagnostic investigations, brain MRI with noninvasive MR-angiography seems to be the imaging modality of choice for cSAH. Some authors consider that cSAH pattern of bleeding is not related with aneurysmal rupture and that procedural risks do not justify performing a catheter angiography in these patients<sup>12</sup>. In accordance, conventional angiogram was carried out only in 35% of our patients and solely for excluding aneurysmal bleeding. Like previous reports, the frontal lobe was the primary site of bleeding. Bilateral bleeding was as frequent as unilateral<sup>1,2,6,7</sup>.

With regard to outcome, although some studies suggest that cSAH has a worse prognosis than other types of

nonaneurysmal SAH (e.g. perimesencephalic SAH), this did not seem to be the case for our cohort and other series<sup>2,13</sup>. One such study that exhibited a poorer prognosis of cSAH, had an older population (mean age: 70 years), with 83% of the patients being over 60 years old. In this cohort, neurological disease was identified as the direct or indirect cause of death in 80% of the patients suggesting that older populations have a worse outcome with cSAH<sup>7</sup>. The mean age of our cohort was 53 years and only 45% of them were over 60 years old. Only two of our patients died and in both cases death was unrelated to the cSAH but to progression of underlying onco-hematological disease. We believe that mortality in cSAH is low and probably linked to underlying disease and not the bleeding itself as opposed to aneurysmal or traumatic SAH.

Our study, however, presents certain drawbacks. First of all, this is a single center retrospective cohort. This design is likely to cause significant selection bias as patients are selected by admission to a specific hospital and from a radiological sign, which may be subtle, especially on CT. In addition to the younger age of this cohort, many patients with CAA and cSAH often present with transient ischemic symptoms and, without MRI as the standard work up in transient ischemic stroke, it is unlikely that the cSAH would be identified in this population, as symptoms might not be alarming.

To conclude, according to our findings, in young and female patients with cSAH, physicians should consider CVT as one of the main differential diagnosis among others such as CAA and RCVS.

## References

1. Kumar S, Goddeau RP Jr, Selim MH, Thomas A, Schlaug G, Alhazzani A et al. Atraumatic convexal subarachnoid hemorrhage: clinical presentation, imaging patterns, and etiologies. *Neurology*. 2010;16;74(11):893-9. <https://doi.org/10.1212/WNL.0b013e3181d55efa>
2. Bruno VA, Lereis VP, Hawkes M, Ameriso SF. Nontraumatic subarachnoid hemorrhage of the convexity. *Curr Neurol Neurosci Rep*. 2013;13(4):338. <https://doi.org/10.1007/s11910-013-0338-3>
3. Knudsen KA, Rosand J, Karluk D, Greenberg SM. Clinical diagnosis of cerebral amyloid angiopathy: validation of the Boston criteria. *Neurology* 2001;56(4):537-9. <https://doi.org/10.1212/WNL.56.4.537>
4. Rooden S, Grond J, Boom R, Haan J, Linn J, Greenberg SM et al. Descriptive analysis of the Boston criteria applied to a Dutch-type cerebral amyloid angiopathy population. *Stroke* 2009;40(9):3022-7. <https://doi.org/10.1161/STROKEAHA.109.554378>
5. Ducros A. Reversible cerebral vasoconstriction syndrome. *Lancet Neurol* 2012; 11(10):906-17. [https://doi.org/10.1016/S1474-4422\(12\)70135-7](https://doi.org/10.1016/S1474-4422(12)70135-7)
6. Graff-Radford J, Fugate JE, Klaas J, Flemming KD, Brown RD, Rabinstein AA. Distinguishing clinical and radiological features of non-traumatic convexal subarachnoid hemorrhage. *Eur J Neurol*. 2016;23(5):839-46. <https://doi.org/10.1111/ene.12926>
7. Beitzke M, Gattringer T, Enzinger C, Wagner G, Niederkorn K, Fazekas F. Clinical presentation, etiology, and long-term prognosis in patients with nontraumatic convexal subarachnoid hemorrhage. *Stroke*. 2011;42(11):3055-60. <https://doi.org/10.1161/STROKEAHA.111.621847>
8. Bittencourt LK, Palma-Filho F, Domingues RC, Gasparetto EL. Subarachnoid hemorrhage in isolated cortical vein thrombosis: are presentation of an unusual condition. *Arq Neuropsiquiatr*. 2009;67(4):1106-8. <https://doi.org/10.1590/S0004-282X2009000600029>
9. Benabu Y, Mark L, Daniel S, Glikstein R. Cerebral venous thrombosis presenting with subarachnoid hemorrhage: case report and review. *Am J Emerg Med*. 2009;27(1):96-106. <https://doi.org/10.1016/j.ajem.2008.01.021>
10. Saposnik G, Barinagarrementeria F, Brown RD Jr, Bushnell CD, Cucchiara B, Cushman M et al. Diagnosis and management of cerebral venous thrombosis: a statement for healthcare professionals from the American Heart Association/American Stroke Association. *Stroke*. 2011;42(4):1158-92. <https://doi.org/10.1161/STR.0b013e31820a8364>
11. Charidimou A, Linn J, Vernooij MW, Opherk C, Akoudad S, Baron JC et al. Cortical superficial siderosis: detection and clinical significance in cerebral amyloid angiopathy and related conditions. *Brain*. 2015;138(Pt 8):2126-39. <https://doi.org/10.1093/brain/awv162>
12. Patel KC, Finelli PF. Nonaneurysmal convexity subarachnoid hemorrhage. *Neurocrit Care*. 2006;4(3):229-33. <https://doi.org/10.1385/NCC.4.3.229>
13. Nayak S, Kunz AB, Kieslinger K, Ladurner G, Killer M. Classification of non-aneurysmal subarachnoid haemorrhage: CT correlation to the clinical outcome. *Neuroradiol J*. 2011;24(5):715-25. <https://doi.org/10.1177/197140091102400508>