

Metastatic seeding after a stereotactically-guided biopsy followed by gamma knife surgery

Diseminación metastásica luego de una biopsia guiada por estereotaxia, seguida por cirugía con bisturí de rayos gamma

Oscar H. Del Brutto¹, Guillermo Paulson², Iván X. Mena³

Gamma knife surgery is often used for treatment of brain metastases. A stereotactically-guided biopsy is performed to confirm the diagnosis in doubtful cases. Tumor cells that may spread as a result of the biopsy may survive and grow after gamma knife surgery, leaving a metastatic seeding through the biopsy tract. In this 45-year-old man,

with a biopsy-proven metastatic adenocarcinoma, seeding was noticed after gamma knife surgery (Figure). This rare complication should be kept in mind when evaluating patients with brain metastases undergoing stereotactic biopsy followed by gamma knife surgery and not conventional radiation¹.

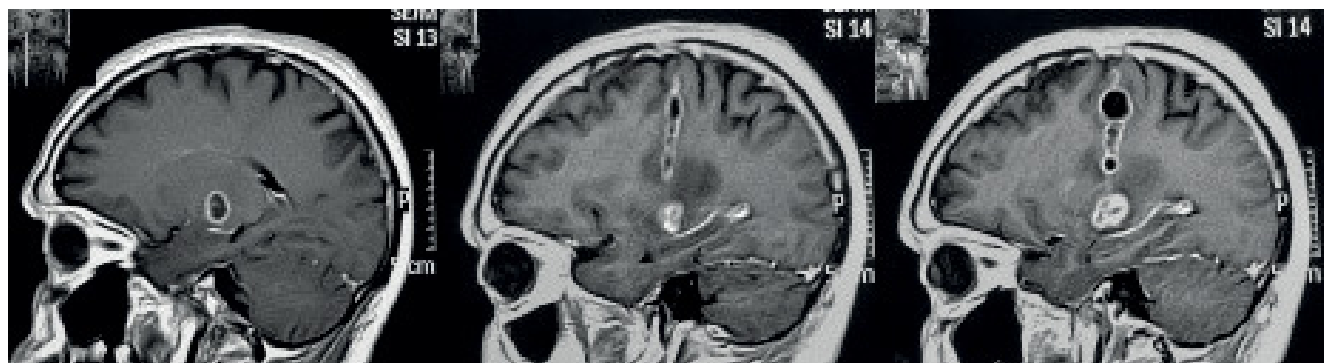


Figure. Tumor seeding developing within the tract of a stereotactically-guided biopsy in a patient with metastatic adenocarcinoma from lung cancer further submitted to gamma knife surgery. Basal MRI shows a thalamic metastasis (*left*). Increasing tumor seeding along the surgical tract was noted four (*center*) and six months (*right*) after the procedure.

References

1. Karlsson B, Ericson K, Kihlstrom L, Grane P. Tumor seeding following stereotactic biopsy of brain metastases. *J Neurosurg* 1997 Aug;87(2):327-30. <https://doi.org/10.3171/jns.1997.87.2.0327>

¹Universidad Espíritu Santo, School of Medicine, Samborondón, Ecuador;

²Instituto Oncológico Nacional, Department of Clinical Oncology, Guayaquil, Ecuador;

³Hospital-Clinica Kennedy, Department of Neurological Sciences, Guayaquil, Ecuador.

Oscar H. Del Brutto  <https://orcid.org/0000-0003-1917-8805>

Correspondence: Oscar H. Del Brutto; Air Center 3542, PO Box 522970, Miami, FL 33152-2970; E-mail: oscardelbrutto@hotmail.com

Conflict of interest: There is no conflict of interest to declare.

Received 27 August 2018; Accepted 11 September 2018.