

# PINEAL YOLK SAC TUMOR

## Correlation between neuroimaging and pathological findings

Táisa Davaus<sup>1</sup>, Emerson L. Gasparetto<sup>2</sup>, Arnolfo de Carvalho Neto<sup>3</sup>,  
Juliana Elizabeth Jung<sup>4</sup>, Luiz Fernando Bleggi-Torres<sup>5</sup>

**ABSTRACT** - A 17-year-old boy presented with somnolence and mental confusion. Physical examination demonstrated motor disturbances. Laboratorial investigation showed elevated levels of alpha-fetoprotein in serum and cerebrospinal fluid. The CT scan revealed a heterogeneous mass at the pineal region. At the MRI, this lesion was hypointense on T1 and hyperintense on T2-weighted images, enhancing after contrast administration. The patient underwent a surgical biopsy, which defined the diagnosis of yolk sac tumor. We emphasize the correlation of neuroimaging and pathological findings of this rare pineal region tumor.

**KEY WORDS:** yolk sac tumor, pineal region, magnetic resonance imaging.

### **Tumor do seio endodérmico da pineal: correlação entre os achados patológicos e de neuroimagem**

**RESUMO** - Um menino de 17 anos de idade apresentou-se com sonolência e confusão mental. O exame físico demonstrou distúrbios motores. A investigação laboratorial revelou aumento dos níveis de alfafetoproteína no soro e no líquido. A TC de crânio revelou massa heterogênea na região pineal. À RM, a lesão era hipointensa em T1 e hiperintensa em T2, com realce após a administração de contraste. O paciente foi submetido a biópsia cirúrgica, a qual definiu o diagnóstico de tumor do seio endodérmico. Enfatizamos a correlação entre os achados patológicos e de neuroimagem deste raro tumor da região pineal.

**PALAVRAS-CHAVE:** tumor do seio endodérmico, região pineal, ressonância magnética.

Pineal region tumors are rare, comprising 3.8% of intracranial tumors in children and 0.4% to 1% of adult brain tumors. The three major categories of neoplasms arising in this site are germ cell tumors, primitive neuroectodermal cell tumors, and neoplasms of the supporting tissues (glial tumors)<sup>1</sup>. Tumors of germ cell origin include germinomas, teratomas, and less commonly, embryonal carcinoma, pineal yolk sac tumor and choriocarcinoma<sup>2</sup>. Pineal yolk sac tumors are rare, even among the germ cell tumors of the pineal gland. They usually occur in the second decade of life and are associated to extremely poor prognosis<sup>3</sup>. There are rare reports of the imaging aspects of this tumor, which usually showed findings similar to the other germ cell tumors<sup>3-6</sup>. However, no previous studies intended to correlate neuroimaging and pathological features of this entity.

We present a case of pineal yolk sac tumor, em-

phasizing the correlation of neuroimaging and pathological findings.

### **CASE**

A 17-year-old boy presented with somnolence and mental confusion beginning 40 days earlier. Neurological physical examination showed dysfunction of the eye movement (II and IV cranial nerves), dysmetria, dysidiadochokinesia and symmetric hyporeflexia in both superior and inferior extremities. Laboratory examinations demonstrated elevated serum alpha-fetoprotein (AFP) (6900 ng/mL - normal values: 0-15 ng/mL) and human chorionic gonadotropin (HCG) (51.9 mIU/mL - normal values <5.0 mIU/mL), and high levels of cerebrospinal fluid (CSF) AFP (172.78 ng/mL).

A CT scan performed at the emergency room showed signs of hydrocephalus, and a heterogeneous low-density lesion affecting the pineal region and mesial portions of both thalami. After that, the patient underwent a ventriculoperitoneal shunt.

The MRI showed an extra-axial lobulated mass in the

Universidade Federal Paraná School of Medicine, Curitiba, PR, Brazil: Departments of Diagnostic Radiology and Pathology; DAPI - Diagnóstico Avançado Por Imagem, Curitiba, PR, Brazil: <sup>1</sup>MD; <sup>2</sup>MD, PhD; <sup>3</sup>MD; <sup>4</sup>MD; <sup>5</sup>MD, PhD.

Received 20 July 2006, received in final form 8 November 2006. Accepted 9 January 2007.

Dra. Táisa Davaus - Rua Fernando Amaro 89 / 61 - 80050-020 Curitiba PR - Brasil. E-mail: taisadavaus@hotmail.com

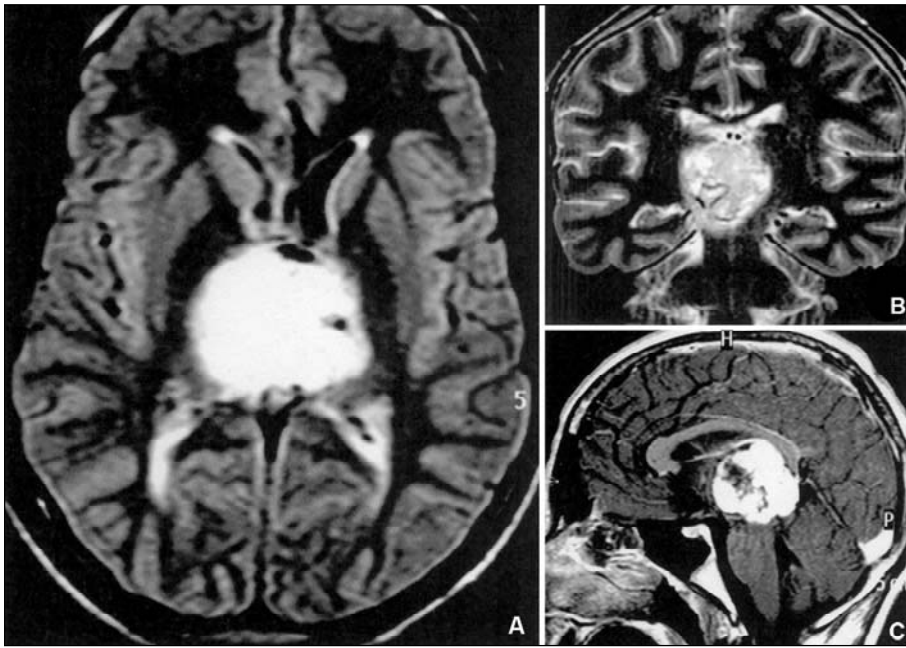


Fig 1. (A) Coronal T2-weighted image demonstrates a midline mass with heterogeneous high-signal. (B) FLAIR image shows a pineal region mass with high signal intensity, which is compressing both thalami and the third ventricle. (C) Coronal T1-weighted image after contrast administration reveals intense and heterogeneous lesion enhancement.

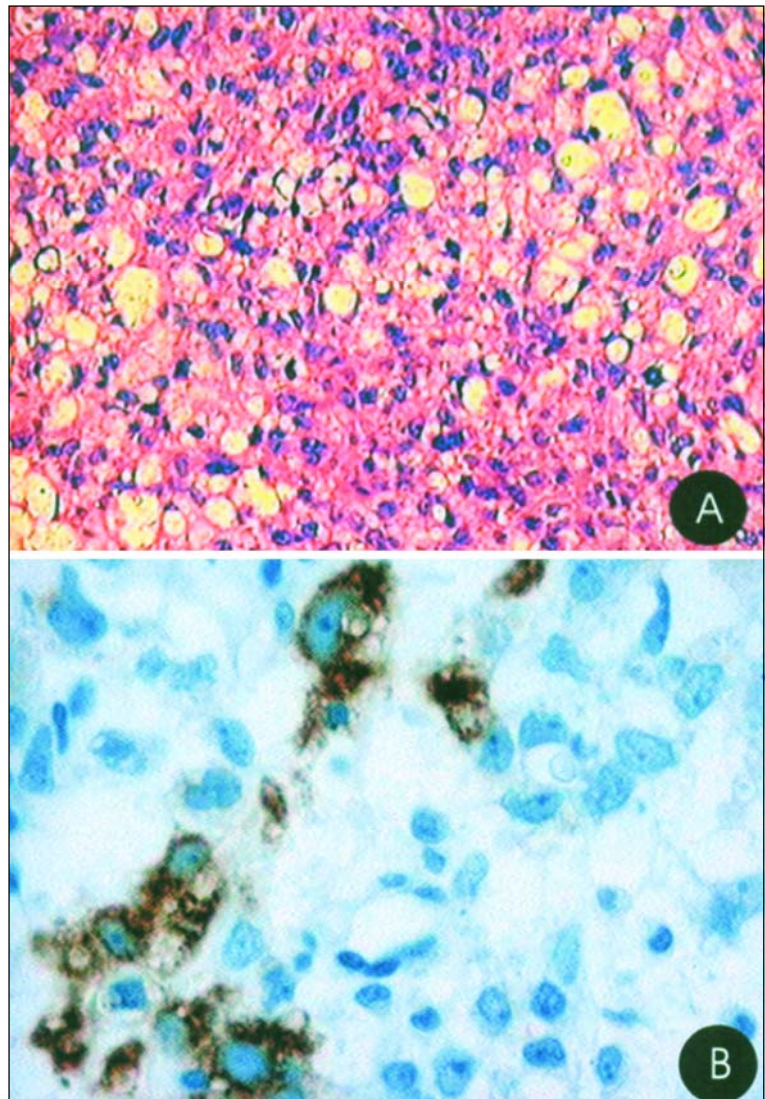


Fig 2. (A) Photomicrography of the histological section demonstrates a neoplasm composed by large cells with anaplastic characteristics and prominent nucleoli (HE x20). (B) Immunohistochemical section shows positivity for AFP antibodies in the neoplastic cells (DAB x100).

pineal region, extending into the third ventricle and right mesencephalon, sizing 3.5 x 3.0 x 3.0 cm in diameter. The lesion had low signal on T1 and high signal on T2-weighted images, showing intense enhancement after contrast administration (Fig 1).

The patient underwent surgical biopsy and the histological examination demonstrated a neoplasm composed of large cells, which showed anaplastic characteristics, prominent nucleoli, and significant mitotic activity (Fig 2). The typical Schiller-Duval bodies were not identified and no periodic acid Schiff (PAS)-diastase resistant globules were present. The immunohistochemical study showed AFP and cytokeratins reactivity, focal reactivity for vimentin, and negative expression for CD30 (K1-antigen), defining the diagnosis of yolk sac tumor.

After his clinical improvement, the patient was discharged from the hospital. A total of 32 sessions of radiotherapy was initiated and followed by chemotherapy consisting of 5 cycles of Carbo-Pei (carboplatin 600-1020 mg/m<sup>2</sup>, etoposide 100-170 mg/m<sup>2</sup>, and ifosfamide 1800-3061 mg/m<sup>2</sup>, per cycle), beginning a half-dose and progressing to a full-dose.

Five months later, a follow-up MRI showed partial regression of the tumor, with only a small enhancing lesion remaining (1.5 x 0.7 x 0.5 cm). At that time, written informed consent was obtained from the parents.

## DISCUSSION

Tumors of the pineal region are uncommon, ranging from 0.5 to 2% of all intracranial neoplasms<sup>4</sup>. The clinical presentation is usually related to the compression of adjacent structures and includes hydrocephalus and dysfunction of the eyes movements<sup>1</sup>. Our patient presented with hydrocephalus, intracranial hypertension signs, dysfunction of the eyes movement, dysmetria, dysdiadochokinesia and symmetric hyporeflexia in both superior and inferior members.

Several markers are assayed in patients with pineal region tumors. Among of them, HCG and AFP can be demonstrated in serum, CSF, and tissue specimens by immunohistochemical techniques<sup>4</sup>. AFP is produced by the yolk sac tumor in the early stage of development, and HCG is synthesized by the choriocarcinoma. Embryonal carcinomas, which contain multiple differentiated extraembryonic structures, produce both AFP and HCG<sup>2</sup>. In the present case, only AFP level was increased in the CSF assay, and both markers had elevated levels in the serum.

CT scan and MRI are very useful in the investigation of pineal region tumors<sup>1,2,4</sup>. These lesions are usually variable in shape, irregular, larger than 20 mm, and frequently compress and infiltrate neighboring structures<sup>1</sup>. The complex origin of the pineal region tumors makes the imaging characteristics usu-

ally nonspecific<sup>2,4</sup>. According to Chang et al.<sup>2</sup>, the pineal yolk sac tumors have a CT scan appearance similar to the other pineal germ-cell tumors. Usually they present high density, calcifications, and intense homogeneous contrast enhancement. Tien et al.<sup>4</sup>, in a study stressing the MRI findings of pineal tumors, described a case of yolk sac tumor. This patient presented a round mass isointense to the white matter on T1 and hyperintense on T2-weighted images. The CT scan of our case demonstrated a low density mass at the pineal region and mesial portions of thalamus. The MRI showed an extra-axial lobulated mass in the pineal region, with low signal on T1 and high signal on T2-weighted images, and intense enhancement after contrast administration.

The histological classification of germ cell tumors is usually similar to their gonadal counterparts<sup>6</sup>. Yolk sac tumors are known to exhibit a variety of microscopic patterns. Though inconstant, some diagnostically useful characteristics of these tumors are the presence of PAS-diastase positive hyaline globules and Schiller-Duval bodies. On immunohistochemical investigation, hyaline globules immunoreactive for AFP are a diagnostic feature, but they are not always positive. Broad panels of immunohistochemical stains are usually necessary to indicate the diagnosis of yolk sac tumor<sup>6,7</sup>. Our case showed unspecific histological findings, and the diagnosis was defined by the immunohistochemical study.

In conclusion, although MRI is essential to investigate pineal region yolk sac tumor characteristics and its relationship to the neural and vascular structures, these imaging findings are usually nonspecific. Correlation of the clinical data and tumor markers significantly improves the diagnostic accuracy, although the definitive diagnosis depends on the histological and immunohistochemical examinations.

## REFERENCES

1. Gasparetto EL, Warszawiak D, Adam GP, Bleggi-Torres LF, Carvalho A Neto. Glioblastoma multiforme of the pineal region: case report. *Arq Neuropsiquiatr* 2003;61:468-472.
2. Chang T, Teng MM, Guo WY, Sheng WC. CT of pineal tumors and intracranial germ-cell tumors. *Am J Roentgenol* 1989;153:1269-1274.
3. Kirikae M, Arai H, Hidaka T, et al. Pineal yolk sac tumor in a 65-year-old man. *Surg Neurol* 1994;42:253-258.
4. Tien RD, Barkovich AJ, Edwards MSB. MR imaging of pineal tumors. *Am J Roentgenol* 1990;155:143-151.
5. Osumi AM, Tien RD. MR findings of pineal yolk sac tumor in a patient with testicular embryonal carcinoma. *Clin Imaging* 1994;18:203-208.
6. Tan HW, Ty A, Goh SG, Wong MC, Hong A, Chuah KL. Pineal yolk sac tumour with a solid pattern: a case report in a Chinese adult man with Down's syndrome. *J Clin Pathol* 2004;57:882-884.
7. Hirato J, Nakazato Y. Pathology of pineal region tumors. *J Neurooncol* 2001;54:239-249.