

BICKERSTAFF'S ENCEPHALITIS, GUILLAIN-BARRÉ SYNDROME AND IDIOPATHIC INTRACRANIAL HYPERTENSION

Are they related conditions ?

Alfredo Damasceno¹, Marcondes C. França Jr¹, Daniel S. Pimenta²,
Leonardo de Deus-Silva¹, Anamarli Nucci¹, Benito P. Damasceno¹

Miller Fisher syndrome (MFS), considered a clinical variant of Guillain-Barré syndrome (GBS), is characterized by ophthalmoplegia, ataxia and areflexia¹. Antecedent of respiratory and/or gastrointestinal symptoms is frequent (up to 70%), with an average symptom-free interval of 10 days and the immune-mediated process is often associated with acute phase anti-GQ1b IgG antibodies in up to 95% of all cases². A closely related condition is Bickerstaff's brainstem encephalitis (BBE), which presents additionally alteration of consciousness or long tract signs, but is less frequently associated with anti-GQ1b antibodies³. Their relation and nosological position have been subject of extensive discussion in the literature. Idiopathic intracranial hypertension (IIH) comprises signs of increased intracranial pressure occurring in the absence of obvious cerebral pathology⁴. Some studies have reported cases of intracranial hypertension associated with GBS, very few with MFS, but none with BBE.

We describe a distinct patient presenting initially with typical IIH findings but developing later signs of BBE, MFS and GBS. We also review evidence toward the possible link among MFS, BBE and GBS.

CASE

An obese 15 year-old female presented with a 5-days history of frontal headache, nausea, vomiting and diplopia. Two weeks earlier she had had flu-like symptoms and diarrhea. Examination disclosed normal consciousness, right sixth nerve palsy and bilateral papilledema (Fig 1) with normal visual acuity. Cerebral CT and MRI were normal. Lumbar puncture performed in the first hospitalization day revealed an opening pressure of 100 cm H₂O, and 25 mL of cerebrospinal fluid (CSF) were withdrawn. CSF protein and cell count were 15 mg/dL and two cells per mm³, respectively (Table). Despite a transient relief, the symptoms relapsed and acetazolamide-corticosteroid combination was begun for the hypothesis of IIH. Two days later she devel-

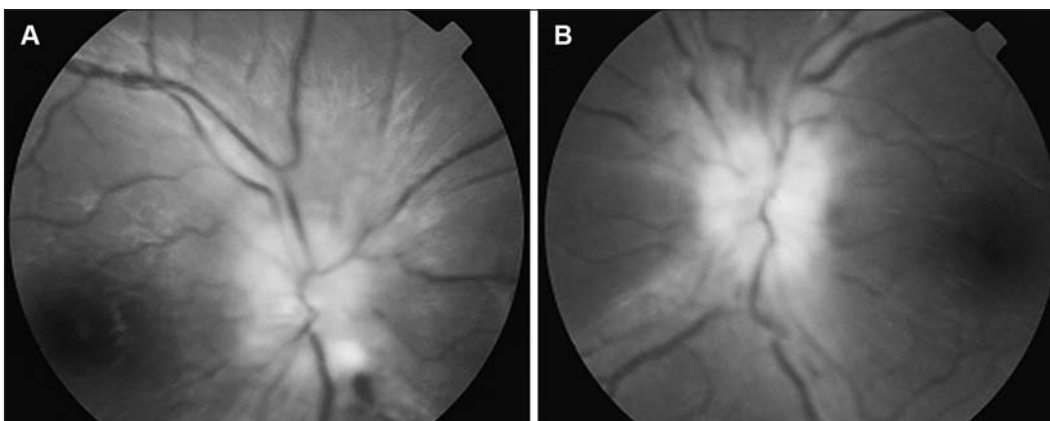


Fig 1. Papilledema at presentation: right (A) and left (B) eye.

ENCEFALITE DE BICKERSTAFF, SÍNDROME DE GUILLAIN-BARRÉ E HIPERTENSÃO INTRACRANIANA IDIOPÁTICA: SÃO CONDIÇÕES RELACIONADAS ?

School of Medicine, State University of Campinas (UNICAMP), Campinas SP, Brazil: ¹Department of Neurology, ²Department of Ophthalmology.

Received 8 April 2008, received in final form 17 June 2008. Accepted 14 July 2008.

Dr. Alfredo Damasceno – Departamento de Neurologia / FCM / UNICAMP - Caixa Postal 6111 - 13083-970 Campinas SP - Brasil. E-mail: alfredodamasceno@hotmail.com

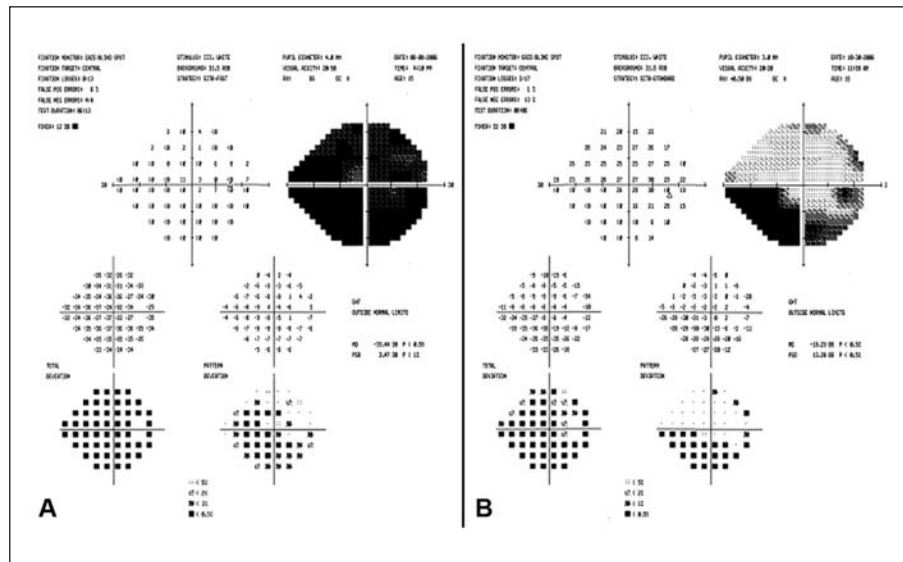


Fig 2. Right eye campimetry performed at the fourth (A) and the thirtieth (B) day of hospitalization.

oped incomplete left third nerve palsy with affected visual acuity and visual field (Fig 2A). On the next day, drowsiness was observed. The symptoms worsened and on the sixth day she had a Glasgow Coma Scale (GCS) score of 11, areflexia, muscle weakness (grade 4 on the Medical Research Council scale), urinary retention and mild cerebellar ataxia. Normal laboratorial investigation excluded metabolic encephalopathy. New CSF analysis (at the 10th hospitalization day) showed increased protein with minimal pleocytosis. Serology for acute viral and bacterial infection was negative. Anti-GQ1b antibodies were not detected. Electrophysiology disclosed reduction in the amplitude of muscle action potential in facial nerves, right median and right ulnar nerves, besides slowed motor nerve conduction velocity in right ulnar nerve and diffusely absent F-responses and H-reflex. She was diagnosed with BBE and treated with intravenous gamma-globulin (0.4g/Kg/day for 5 days). One week later she had a GCS of 15 and recovered almost completely from her ataxia, muscle weakness and urinary retention. One month later she had only a mild right sixth nerve palsy and areflexia with improved visual acuity and campimetry (Fig 2B). Five months later the Achilles reflex was present, though decreased.

A written informed consent to publish the case report was given by the patient and her legal responsible.

DISCUSSION

The initial clinical picture of this patient fulfilled the modified Dandy criteria for IHH. This syndrome, first described more than 100 years ago, is particularly frequent in overweight adolescent girls and is associated with different conditions such as medications, polycystic ovary syndrome and menstrual dysfunction⁴. The pathophysiology of increased CSF pressure has not yet been completely elucidated and different mechanisms have been

Table. Cerebrospinal fluid parameters through disease evolution.

CSF parameters	D1	D4	D10	D25	D90
Opening pressure (cm H ₂ O)	100	95	37	15	ND
Total protein (mg/L)	15	ND	70	88	39
Glucose (mg/L)	63	ND	99	70	54
Cell count (cells/mm ³)	2	ND	5	4	5

ND, not done; D1, D4, D10, D25, and D90, days of hospitalization; numbers 1, 4, 10, 25, and 90, respectively.

proposed, such as increased cerebral volume, CSF production rate and cerebral venous pressure, but impaired CSF outflow into the venous system does play an important role⁵. The course is usually benign, though sometimes it can be complicated with visual loss⁴.

Our patient, however, showed an atypical evolution. Within 1-week period she developed weakness, drowsiness and ophthalmoplegia, features of GBS, BBE and MFS, respectively. In GBS, co-occurrence of intracranial hypertension has been documented, with papilledema found in about 4% of affected children, and less frequently in adults⁶. Although high protein content has been related to the mechanism of pseudotumor in GBS, it does not always play a major role⁷, since intracranial hypertension has also been observed in patients with only mildly or moderately elevated CSF protein content, as in our case. Other mechanisms such as an immune-mediated impairment of CSF outflow into the venous system may also be related. In MFS, few cases showing signs of elevated intracranial pressure have been documented in the literature⁸, but, to our knowledge, it has never been described with BBE. This association may be under recognized since ophthalmoscopy and CSF pressure are not routinely assessed in MFS, BBE or GBS.

The classic triad of ophthalmoplegia, ataxia and areflexia was first described in 1956 by Fisher, who regarded it as an unusual variant of GBS resulting from peripheral nerve injury⁹. Interestingly, one of his patients had drowsiness. One year later, Bickerstaff continued his previous work and reported eight patients with acute ophthalmoplegia, ataxia and altered consciousness, considering this syndrome as a form of encephalitis¹⁰. Four of his patients had areflexia. Due to the similarities of these syndromes, much begun to be debated in literature, from being or not variants of the same spectrum to their nosological position as either peripheral or central¹¹. An important contribution was the finding of an antibody that reacts with peripheral nerve ganglioside GQ1b in a great number of patients with MFS¹² and some with BBE³. Further observations related this antibody to the presence of ophthalmoplegia and ataxia. Greater amounts of ganglioside GQ1b have been found in cranial nerves III, IV and VI¹² and these nerves were enhanced by gadolinium on MRI in patients with MFS¹³. A selective staining of the cerebellar molecular layer by serum IgG antiGQ1b has also been observed¹⁴. Although the presence of this antibody could be a secondary phenomenon due to destruction of neurons, some evidence points to a pathogenetic role, with blocking effects on the neuromuscular transmission¹⁵. The appearance of this antibody has been related to cross reactivity with lipopolysaccharide in the bacterial coat of *Campylobacter jejuni*, especially those with a particular polymorphism (Asn51) of *cst-II* gene¹⁶. The anti-GQ1b antibodies were not detected in our patient, pointing more to the BBE side of the possible "MFS-BBE spectrum".

Another valuable contribution came from studies with brain imaging describing abnormalities in some cases of BBE. In about 30% of the patients, high-signal lesions on T2-weighted scans were found in the brainstem, thalamus, cerebellum and cerebrum³. A study with PET scan also found involvement of brainstem and cerebellum¹⁷. Similar findings have also been reported in patients diagnosed with MFS¹⁸, even in the absence of drowsiness or long tract signs, pointing to a central involvement in both MFS and BBE. Also supporting the spectrum hypothesis has been the evidence of concomitant central and peripheral abnormalities described by Ogawara et al.¹⁹. More, symptoms of central involvement in MFS, such as a mild somnolence, may not always be recognized.

The relation of these syndromes to GBS has been proposed since the first description of Bickerstaff and Fisher, and supported by several overlapping cases³ describing the presence of muscle weakness and albuminocytologic dissociation in addition to the classic triad of Fisher and/or altered consciousness or extensor plantar responses. The prognosis, however, is usually benign, especially in the "classic" MFS², and while in GBS treatment with plasmapheresis

or immunoglobulin is widely recommended¹, in MFS they are not always necessary². In BBE or MFS/BBE overlapping cases, this treatment has been associated with beneficial effects, but randomized controlled trials are needed to establish the value of immunotherapies or other treatments²⁰. Our patient received a 5-days course of immunoglobulin, but her improvement may be attributed either to the natural history of the disease or to the treatment.

Finally, this case shows a remarkable presentation of BBE with intracranial hypertension, a condition previously associated with GBS or MFS alone. It also contributes to the understanding of the "MFS-BBE spectrum" or acute inflammatory encephaloradiculoneuritis, which may be considered as a variant of GBS, presenting both peripheral and central involvement.

REFERENCES

1. Hughes RA, Cornblath DR. Guillain-Barré syndrome. *Lancet* 2005;366:1653-1666.
2. Overell JR, Willison HJ. Recent developments in Miller Fisher syndrome and related disorders. *Curr Opin Neurol* 2005;18:562-566.
3. Odaka M, Yuki N, Yamada M, et al. Bickerstaff's brainstem encephalitis: clinical features of 62 cases and a subgroup associated with Guillain-Barré syndrome. *Brain* 2003;126:2279-2290.
4. Ball AK, Clarke CE. Idiopathic intracranial hypertension. *Lancet Neurol* 2006;5:433-442.
5. Walker RW. Idiopathic intracranial hypertension: any light on the mechanism of the raised pressure? *J Neurol Neurosurg Psychiatry* 2001;71:1-5.
6. Weiss GB, Bajwa ZH, Mehler MF. Co-occurrence of pseudotumor cerebri and Guillain-Barré syndrome in an adult. *Neurology* 1991;41:603-604.
7. Ropper AH, Marmarou A. Mechanism of pseudotumor in Guillain-Barré syndrome. *Arch Neurol* 1984;41:259-261.
8. Putiliano S, Viola L, Genovese O, et al. Miller-Fisher syndrome mimicking intracranial hypertension following head trauma. *Childs Nerv Syst* 2005;21:473-476.
9. Fisher M. An unusual variant of acute idiopathic polyneuritis (syndrome of ophthalmoplegia, ataxia and areflexia). *N Engl J Med* 1956;255:57-65.
10. Bickerstaff ER. Brain-stem encephalitis; further observations on a grave syndrome with benign prognosis. *Br Med J* 1957;1:1384-1387.
11. Al-Din AN. The nosological position of the ophthalmoplegia, ataxia and areflexia syndrome: "the spectrum hypothesis". *Acta Neurol Scand* 1987;75:287-294.
12. Chiba A, Kusunoki S, Obata H, et al. Serum anti-GQ1b IgG antibody is associated with ophthalmoplegia in Miller Fisher syndrome and Guillain-Barré syndrome: clinical and immunohistochemical studies. *Neurology* 1993;43:1911-1917.
13. Nagaoka U, Kato T, Kurita K, et al. Cranial nerve enhancement on three-dimensional MRI in Miller Fisher syndrome. *Neurology* 1996;47:1601-1602.
14. Kornberg AJ, Pestronk A, Blume GM, et al. Selective staining of the cerebellar molecular layer by serum IgG in Miller Fisher and related syndromes. *Neurology* 1996;47:1317-1320.
15. Lo YL, Chan LL, Pan A, Ratnagopal P. Acute ophthalmoparesis in the anti-GQ1b antibody syndrome: electrophysiological evidence of neuromuscular transmission defect in the orbicularis oculi. *J Neurol Neurosurg Psychiatry* 2004;75:436-440.
16. Yuki N, Koga M. Bacterial infections in Guillain-Barré and Fisher syndromes. *Curr Opin Neurol* 2006;19:451-457.
17. Kwon HM, Hong YH, Sung JJ, et al. A case of Bickerstaff's brainstem encephalitis; the evidence of cerebellum involvement by SPM analysis using PET. *Clin Neurol Neurosurg* 2006;108:418-420.
18. Urushitani M, Udaka F, Kameyama M. Miller Fisher-Guillain-Barré overlap syndrome with enhancing lesions in the spinocerebellar tracts. *J Neurol Neurosurg Psychiatry* 1995;58:241-243.
19. Ogawara K, Kuwabara S, Yuki N. Fisher syndrome or Bickerstaff brainstem encephalitis? Anti-GQ1b IgG antibody syndrome involving both the peripheral and central nervous systems. *Muscle Nerve* 2002;26:845-849.
20. Overell JR, Hsieh ST, Odaka M, et al. Treatment for Fisher syndrome, Bickerstaff's brainstem encephalitis and related disorders. *Cochrane Database Syst Rev* 2007;1:CD004761.