

# ISCHEMIC CEREBRAL CHANGES IN THE CHRONIC CHAGASIC CARDIOPATHY

*JOSÉ EYMARD HOMEM PITELLA \**

Several papers have studied non-specific morphological central nervous system changes in the chronic form of Chagas' disease caused by: 1) thromboembolic complications in chronic chagasic cardiopathy (cerebral infarcts 6,18,19,21); 2) hypoxemia secondary to congestive heart failure in patients with the chronic cardiac form (reduction of the number of cerebellar Purkinje cells 5,10,21; atrophy of the cerebral cortex 3,4,21). Other non-specific findings in chronic chagasic patients are: neural depopulation of the vagus dorsal and the hypoglossus nuclei<sup>17</sup> and of the supra-optical hypothalamic nucleus<sup>13</sup>. These changes are not explained adequately by congestive heart failure hypoxemia alone<sup>17</sup>, and acute phase cellular destruction is suggested as a possible mechanism<sup>10,13</sup>.

The systematic study of the brain of chronic chagasic patients has not been undertaken, even considering these findings. This paper is an attempt to describe the frequency and patterns of central nervous system morphological changes that could be related to chronic chagasic cardiopathy.

## MATERIAL AND METHODS

Thirty-one random cases of the chronic form of Chagas' disease with pathological diagnosis of chronic chagasic carditis were chosen, 24 cases having been autopsied at the Department of Pathology and Forensic Medicine of Minas Gerais University Medical School, in Belo Horizonte, and 7 at the Department of Pathology of the Triangulo Mineiro Medical School, in Uberaba. Twenty-six cases had died due to congestive heart failure, three had sudden death being previously asymptomatic, and two died of other causes not related directly to cardiac disease. Clinical neurological data were consulted in all cases. Brains were fixed in totum by immersion in formaldehyde at 10% and, following macroscopic examination, fragments were taken from the frontal, parietal, temporal, occipital and insular cerebral cortex, the hippocampus, basal ganglia, thalamus, midbrain, pons, medulla, cerebellar cortex and dentate nucleus. In 20 cases,

---

Division of Neuropathology, Department of Pathology, Federal University of Minas Gerais Medical School, Belo Horizonte, Brazil: \* Associate Professor. Work partially supported by FINEP and by Grant 201103/79 from CNPq. *Acknowledgements:* The author wishes to thank Prof. P. Mehraein, Head of the Abteilung für Neuropathologie, Medizinische Hochschule Hannover, who permitted this research in that Institution, as well as for suggestions related to the analysis and interpretation of pathological findings. The author also wishes to thank Profs. E. Chapadeiro and E. R. Lopes, who made possible the study of the brain of seven cases from the Department of Pathology of the School of Medicine of the Triangulo Mineiro in Uberaba, Brazil.

sections of the supra-optical, tuberal and mammillary hypothalamus were examined. Fragments were embedded in paraffins in all cases. Celloidin inclusion was also performed: 1) from frontal sections of the two cerebral hemispheres in at least three distinct levels for the analysis of the frontal, parietal and temporal lobes, basal ganglia and thalamus (14 cases), the mammillary bodies being examined in 6 cases; 2) from sections of the two cerebellar hemispheres (9 cases); 3) from the pons (8 cases); 4) from the medulla (3 cases). Stained sections were obtained using the Nissl, elastic van Gieson and Woelcke (myelin) methods.

## RESULTS

Tables 1, 2 and 3 present the identification and pathological data of the 31 cases (24 male and 7 female patients). Age varies from 21 to 66 years, 11 (35.5%) cases being in the 31-40 age group and 18 evenly distributed in the 21-30, 41-50 and 51-60 age

Case	Sex	Age (years)	Congestive heart failure	Intra- cardiac thrombosis	Infarct		Brain weight (grams)
					Kidney	Spleen	
1	F	34	+	—	—	—	1200
2	M	35	+	—	+	—	1180
3	F	25	+	—	—	—	1200
4	M	27	+	—	+	—	1300
5	F	40	+	—	+	+	1200
6	M	57	+	—	—	—	1300
7	M	44	+	—	+	—	1360
8	M	24	—	—	+	—	1320
9	M	48	+	+	—	—	1350
10	M	27	+	—	—	—	1250
11	M	59	+	—	—	—	1100
12	M	39	+	—	—	—	1400
13	M	60	+	—	—	—	1370
14	F	44	+	+	+	—	1190
15	M	60	+	+	+	—	1250
16	F	21	+	—	—	—	1150
17	M	37	+	—	—	—	1180
18	M	36	+	+	+	+	1590
19	M	66	+	—	—	—	1320
20	F	44	+	—	—	—	1100
21	F	41	+	—	—	—	1260
22	M	31	+	—	—	—	1510
23	M	59	+	+	+	—	1600
24	M	62	+	—	—	—	1340
25	M	39	+	—	—	—	1020
26	M	28	—	—	—	—	1440
27	M	40	+	—	—	—	1200
28	M	46	+	—	+	—	1400
29	M	56	—	—	—	—	1060
30	M	37	—	—	—	—	1200
31	M	36	—	—	—	—	1200

Table 1 — Identification and pathological data of 31 cases of the chronic chagasic cardiopathy. M, masculin; F, feminin.

Cases	Brain Examination	
	Macroscopic	Microscopic
1	NC	NC
2	Old multiple infarcts (LFL, LTL, LBG, LT, LPL, LCH). Atrophy of the cerebral peduncle and L pyramid	Id.
3	NC	OMN (LFL, LPL)
4	NC	OMN (LTL)
5	NC	OEPN (PC)
6	NC	OEPN (PC)
7	NC	OEPN (PC)
8	NC	Old laminar necrosis in the L hippocampus. OEPN (PL, TL, LT, PC)
9	Old multiple infarcts (LBG, LFL, LTL, LPL). Partial atrophy of the L pyramidal tract	Cortical laminar necrosis in organization (LPL). OEPN (LT, PC)
10	NC	REPN (FL, PL, TL, OL, hippocampus, T, PC, dentate nucleus, inferior olivary nucleus)

*Table 2 — Brain examination of cases 1 to 10. MN, micronecrosis; EPN, elective parenchymatous necrosis; R, recent; O, old; FL, frontal lobe; PL, parietal lobe; TL, temporal lobe; OL, occipital lobe; BG, basal ganglia; T, thalamus; CH, cerebellar hemisphere; R, right; L, left; PC, Purkinje cell; NC, no change. Other data: In 24 cases (77.4%) no neurological or psychiatric alterations were present on clinical examination. In three (cases 2, 9, 11) neurological signs compatible with cerebrovascular accident sequelae were found. Case 8, coinciding with episode of meningitis, presented seizures and coma for 30 days. Case 9 developed mental confusion. Mental confusion and sleepiness were observed in cases 15 and 24. Grand mal seizures, with a deterioration of conscience and evolution towards profound coma was observed in case 20.*

groups (6 cases — 19.3% — in each). Two patients were over 60. Most cases (83.9%) had clinical and pathological signs of congestive heart failure, 3 cases (9.7%) had sudden death with no previous symptoms and the other two (6.4%) died of other causes unrelated to cardiac disease. Thrombosis in the left cardiac chambers was found in 5 cases (16.1%). Renal and/or splenic infarct was observed in 10 cases (32.2%), with kidney involvement in 10 cases and spleen involvement in 2 cases.

The macroscopic brain examination did not reveal significant changes in most cases, except for pathological findings due to other processes (see ahead). The most frequent pathological finding was cerebral infarcts (7 cases — 22.6%). Six cases showed old, cystic lesions. In two cases, areas of necrosis were in stages of organization, with concomitant old lesions in another region in one case. Infarcts were multiple in 4 cases, and single in 3. Cases with multiple infarcts had 3 lesions (in two cases) and 2 lesions (in the other two cases). The left cerebral hemisphere was the most affected (6 cases), followed by the right cerebral hemisphere (4 cases) and the left cerebellar hemisphere (3 cases). Parietal lobes were the most frequently involved (5 cases), followed by the basal ganglia (4 cases), frontal and temporal lobes (3

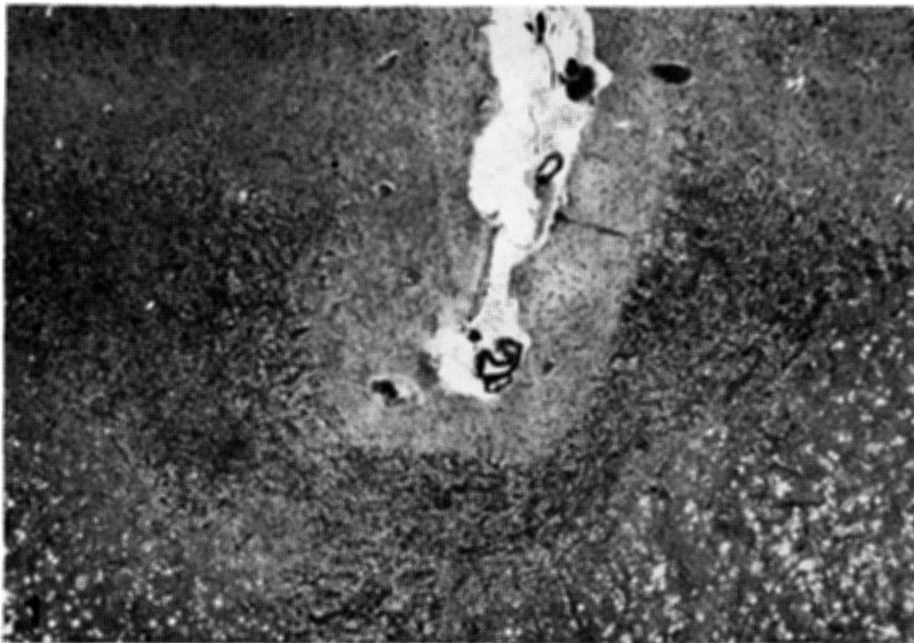Cases	Brain Examination	
	Macroscopic	Microscopic
11	Severe diffuse cortical atrophy, mainly in frontal lobes. Granular atrophy of the base and lateral regions of the frontal lobes, to the right. Old multiple infarcts (RFL, RPL, RBG)	OMN (LFL, RFL, LTL, RPL, RTL, LOL, L hippocampus, LT, CH). RMN (RTL). OEPN (RT, PC). Atrophy of the fronto-pontine and occipito-temporo-pontine tracts, to the right
12	NC	NC
13	Old infarct (RPL, ROL)	OEPN (PC)
14	NC	OMN (LFL). OEPN (PC)
15	NC	OMN (LFL). OEPN (PC)
16	NC	OEPN (PC)
17	Infarct in organization (RBG). Old infarct (LCH)	OMN (right insula and right claustrum). Atrophy of the fronto-pontine fibers, to the right
18	NC	OMN (RFL, LFL, LPL). OEPN (PC)
19	NC	NC
20	NC	OMN (base of the pons). OEPN (PC)
21	NC	OMN (RPL). OEPN (PC)
22	NC	OMN (RFL). Recent cortical laminar necrosis in the right insula
23	Cortical laminar necrosis in organization (LPL)	Recent cortical laminar necrosis (LFL). OEPN (PC)
24	NC	RMN (LPL). OMN (left insula). OEPN (PC)
25	NC	OMN (LFL, RCH). OEPN (PC)
26	NC	OMN (LPL, LOL, lateral hypothalamus)
27	Old infarct (LCH)	OMN (RFL, LPL, RBG, LCH). OEPN (PC, cerebellar cortex)
28	NC	NC
29	NC	Cortical laminar necrosis in organization (RPL). OEPN (RPL, PC)
30	NC	OMN (RFL, LFL, RPL). OEPN (PC)
31	NC	OMN (LTL). OEPN of the Sommer sector of left hippocampus

Table 3 — Brain examination of cases 11 to 31 (see table 2).

cases) and the occipital lobes (1 case). In some cases the areas of necrosis were located in adjacent parts of two lobes or in one lobe and the basal ganglia, as in case 2 (frontal and temporal lobes and basal ganglia, to the left), case 9 (frontal and temporal lobes and temporal and parietal lobes, to the left), case 11 (parietal lobe and basal ganglia, to the right) and case 13 (parietal and occipital lobes, to the right). In most cases the infarct involved only the cortex and subcortical white matter (5 cases), and others were restricted to basal ganglia (2 cases). Macroscopic cortical laminar necrosis was identified in one (case 23). In the cerebellum infarcts were located in the cortex and subcortical white matter, not involving the dentate nucleus. Pyramidal tract atrophy in the brain stem was observed in 2 cases (cases 2 and 9). Most cases of cerebral infarct occurred in the 31-40 and 51-60 age groups (3 cases in each group). There was no correlation between cerebral and renal or splenic infarcts

or with left intra-cardiac thrombosis. Diffuse and intense cortical atrophy mostly in the frontal lobes was observed in one case (case 11 - 3.2%) associated with granular atrophy of the base and sides of the frontal lobes, mostly to the right, and multiple old large infarcts also to the right. This case had the lightest brain in this series. Two others (cases 25 and 29) with reduced brain weight relative to the normal Brazilian adult<sup>22</sup> did not show evidence of morphological macroscopic changes. The circle of Willis arteries were systematically examined and no changes were found except for discrete arteriosclerosis in cases 9, 13 and 27 and hypoplasia of the right vertebral artery in cases 28 and 31. Other macroscopic findings were discrete and moderate cerebral edema (4 cases), neurocysticercosis (2 cases), capillary telangiectasis (2 cases), partial stenosis of the aqueduct (cases 20) and internal moderate hydrocephaly associated with intense and diffuse fibrosis of the leptomeninges, mainly on the superior and lateral parts of the frontal lobes, which was interpreted as sequelae due to meningitis by *H. influenzae* two months prior to death (case 8).

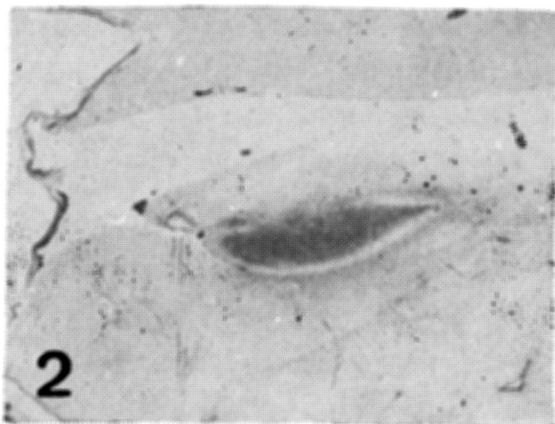
Histological examination did not show important changes in four cases (12.9%). The remaining 27 cases (87.1%) presented three types of lesions (see table 2 and 3). 1) Cortical laminar necrosis in 5 cases (16.1%). In four of these, necrosis was recent or in organization (Fig. 1). Histological signs of almost complete organization was



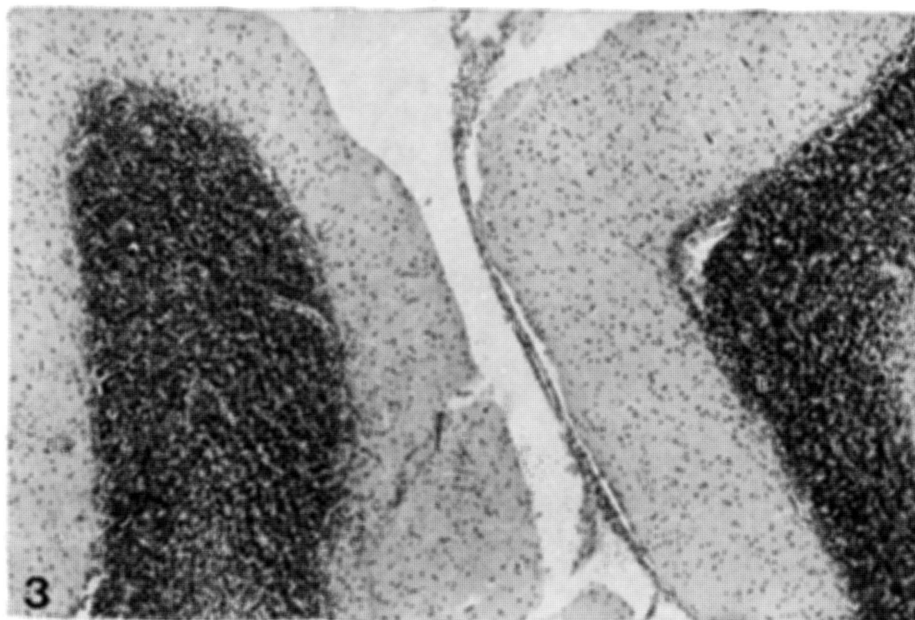
*Fig. 1 — Case 23.  
Cerebral cortex. Small  
focus of cortical  
laminar necrosis in  
organization (Elastic  
van Gieson, X37.5).*

observed in case 8. The left frontal lobe, the right insula, the left hippocampus (Fig. 2) and the right parietal lobe were affected once, and the left parietal lobe, twice. The crest and base of the gyri were involved, and in two cases (cases 23 and 29), the lesion was at the junction of the anterior and middle cerebral artery territories. 2) Old micronecrosis was identified in 16 cases (51.6%). Two cases showed coexisting microfoci of recent necrosis (cases 11 and 24) with recent semi-occlusive thrombosis of a small peripheral cortical artery in case 11. Nine cases had multiple lesions and 7 cases had single lesions. The case with most lesions (case 11, with 12 lesions), showed multiple infarcts, diffuse and intense cortical atrophy, partly granular, predominantly frontal. Necrotic microfoci were seen with greatest frequency in the frontal and parietal cortex. These foci were observed in the base and, most

frequently, in the crest of the gyri. 3) Elective parenchymatous necrosis, found in 20 cases (64.5%). The most frequent example of this type of lesions was observed in the cerebellar cortex (18 cases — 58.1%), with occasional foci of Purkinje cell depopulation with preservation of the granular layer and with no Bergmann glia reaction (Fig. 3). Only in two cases (cases 6 and 8) neuronal reduction was moderate. Also involved was the thalamus in three (cases 8, 9 and 11 - 9.7%). Neuronal depopulation was observed in the dorso-medial (three times), posterior-lateral (twice) and centro-medial (once) nuclei, the left thalamus being affected twice and the right

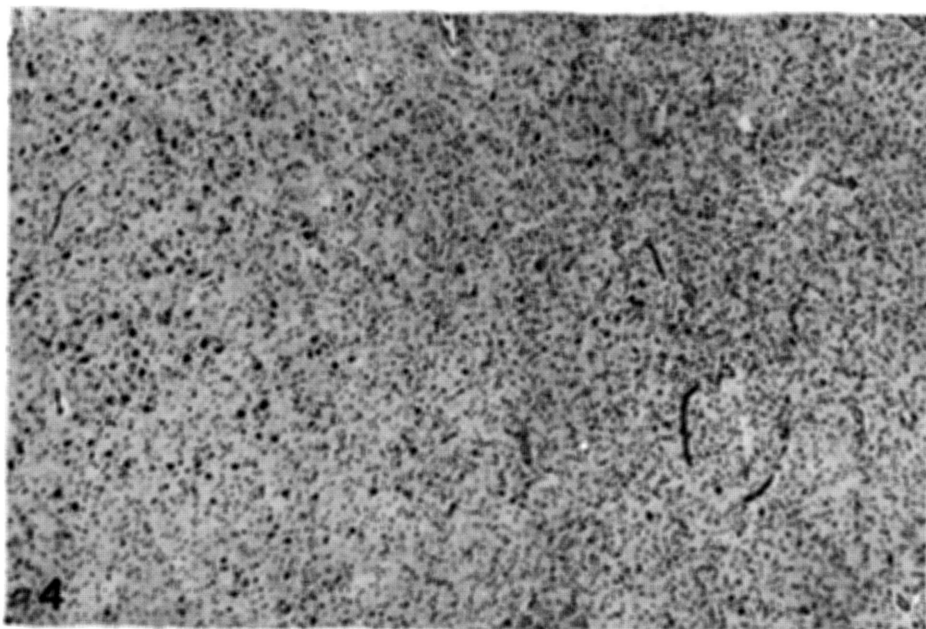


*Fig. 2 — Case. 8: Hippocampus. Intense fibrillary gliosis of Ammon's horn (Holzer, X4).*

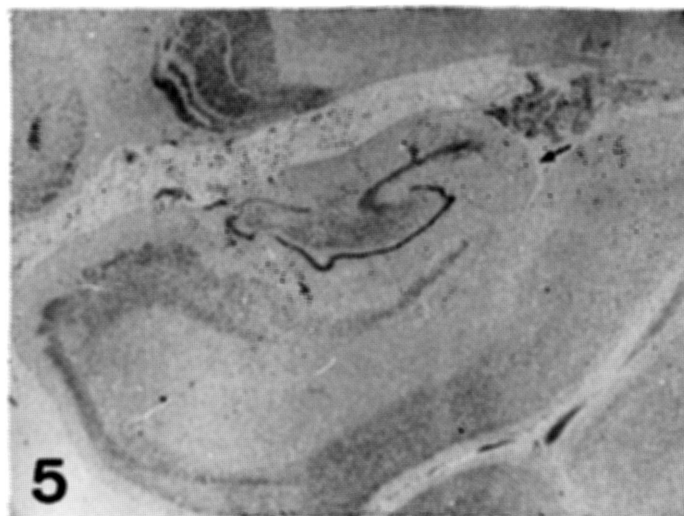


*Fig. 3 — Case 8. Cerebellar cortex. Area of intense Purkinje cells depopulation with preservation of the granular layer (Nissl, X60).*

thalamus once (Fig. 4). In cases 8 and 9, neuronal reduction was partial; in case 11, the process was more extensive. In case 8 the thalamic lesion was associated with a similar lesion in Purkinje cells and in some parts of the parietal and temporal cortex (see ahead) in addition to the old laminar necrosis in the left hippocampus, and in the other two, with multiple old infarcts in the homolateral cerebral hemisphere. Elective parenchymatous necrosis was also observed in the hippocampus (case 3), with a loss of pyramidal cells in the Sommer sector, to the left (Fig. 5), and in the cerebral cortex (cases 8 and 29). In case 8 neuronal depopulation was moderate or intense, affecting diffusely the deep layers of some parts of the parietal and temporal cortex. Case 29 showed light depopulation foci in the right parietal lobe. In case 10 severe and diffuse regressive neuronal ischemic phenomena was observed



*Fig. 4 — Case 9. Thalamus. Neuronal depopulation and proliferation of glial cells, to the right (Nissl, X60).*



*Fig. 5 — Case 31. Hippocampus. Partial loss of neurons in the Sommer sector (arrow). Nissl, X4.*

in the base of the gyri, the hippocampus, the thalamus, the lower olivary nucleus, the dentate nucleus and the cerebellar Purkinje cells, with light reactional granulocyte infiltration.

Two other observations deserve mention. In the cerebral infarcts seen in cases 11 and 17, degeneration of the right frontopontine tract and the occipito-temporo-pontine tract to the right (case 11) and of the fronto-pontine fibers to the right (cases 17) was observed. Finally, the systematic examination of the vagus dorsal, the hypoglossus, the oculomotor, and the hypothalamic supraoptical, the paraventricular and mammillary nuclei did not reveal significant morphological nerve cell changes or the presence of glial nodules.

#### DISCUSSION

The frequency of cerebral infarcts in this study (22.6%) is similar to that published by Queiroz<sup>21</sup> (26.3%) and superior to that observed by Neiva and Andrade<sup>18</sup> (9.4%). As a result of the relatively small number of cases of cerebral infarct, our findings, those of Nussenzweig et al.<sup>19</sup> and those of Neiva and Andrade<sup>18</sup> show an irregular age group distribution. However, these

studies in association show an increase of the frequency of lesions with age, as has been pointed out by Queiroz<sup>21</sup>. The cerebral hemispheres were preferred sites in our series and in those of Nussenzweig et al.<sup>19</sup>, Neiva and Andrade<sup>18</sup> and Queiroz<sup>21</sup>, mostly to the right in Queiroz's series<sup>21</sup> and to the left in Neiva and Andrade<sup>18</sup> and our series. In the cerebral hemispheres, the parietal, frontal, temporal lobes and the basal ganglia were the most affected, in general agreement with the observations made by Neiva and Andrade<sup>18</sup> and Queiroz<sup>21</sup>. The frequency of cerebellar infarcts in our cases (42.8%) was greater than that described by Queiroz<sup>21</sup> (10%). The frequency of multiple lesions in our cases was greater than that in Neiva and Andrade<sup>18</sup>; in both series a great variation of the size of necrotic areas was found. Most old lesions in our series are in agreement with the findings of Queiroz<sup>21</sup> in which the suggestion was made that cerebral infarcts are not important as a *causa mortis* in these patients, and do not affect the prognosis of the disease. It is possible that an explanation can be found in the topography and dimensions of these infarcts<sup>23</sup>, in the relative youth of most patients and the absence of significant morphological changes in the circle of Willis arteries in most cases. Based on the initial works of Nussenzweig et al.<sup>19</sup>, Andrade<sup>6</sup> and Neiva and Andrade<sup>18</sup> it is known that the cerebral infarcts in chronic chagasic cardiopathy result from parietal thrombosis from the left heart. The absence at necropsy, of intra-cardiac thrombosis in most cases of cerebral infarcts in this series can be explained by their breaking off<sup>18</sup> or by organization and absorption into the endocardium<sup>25</sup>.

Cerebral cortical atrophy in patients with chronic chagasic heart disease was described for the first time by Alencar<sup>3,4</sup> and was found in 15.7% of cases<sup>21</sup>. In our series it was observed in one case (3.2%) and was related to the presence of old multiple infarcts, granular cortical atrophy and old multiple micronecrosis. Nearly half of the cases of cortical atrophy observed by Queiroz<sup>21</sup> presented concomitant cerebral infarcts. In our cases, as opposed to Alencar<sup>3,4</sup> and Queiroz<sup>21</sup>, we found that cortical atrophy is an uncommon phenomena in chronic chagasic heart disease, unrelated to chronic hypoxemia resulting from congestive heart failure as proposed by those authors, and associated with old multiple embolic vascular occlusion.

Cortical laminar necrosis was found in 16.1% of cases and has not yet been described in chronic chagasic patients. The lesion can be found in heart disease of any cause or following cardiovascular disturbances, always characterized by episodes of abrupt transitory fall of systemic arterial pressure and cerebral blood flow<sup>1,2,8,9,14</sup>. This may be responsible for laminar necrosis in Chagas' disease, where, in addition to the reduction of the cardiac output and the systolic arterial pressure due to congestive heart failure, disturbances of the cardiac rhythm may be found. These are common in patients with the chronic cardiac form, as described by Chagas in the original description of the disease<sup>12</sup>, with the frequency of AV block being 17% in fatal cases<sup>15</sup>. Our two cases of cortical necrosis at the junction between the anterior and middle cerebral arteries favours this hypothesis.



A frequent finding in our cases were multiple old microscopic foci of necrosis (micronecrosis) in 51.6% of cases, caused by the microembolic occlusion of a small artery<sup>9,11,14</sup>. Vascular obliteration is almost always impossible to prove in this situation. In one case, we were able to find recent semi-occlusive thrombosis of a small cortical artery adjacent to an area of equally recent micronecrosis, probably the result of embolic occlusion. Thromboembolic phenomena may occur also in chronic chagasic patients with no congestive heart failure<sup>7</sup>, and in three previously asymptomatic cases with sudden death, in our series, micronecrotic lesions were found.

The most common lesion in our series was elective parenchymatous necrosis (64.5% of cases). The most frequent example of this was focal and sparse reduction of the number of Purkinje cells (58.1%), having been described previously in chagasic patients with the chronic cardiac forms of the disease<sup>5,10,21</sup>. This has been thought of as secondary to hypoxemia following congestive heart failure, being also found in heart diseases of other causes<sup>5,9,24</sup>. Elective parenchymatous necrosis was also found in the thalamus (9.7% of cases), and had not been described previously in Chagas' disease. It is non-specific, having been observed in situations of a sudden fall in systemic arterial pressure, with a reduction of cerebral blood flow<sup>2,9,14</sup>. In case 8, the thalamic lesion was associated with selective neuronal loss of Purkinje cells, and of parts of the parietal and temporal cortex, and laminar necrosis in the hippocampus; such an association suggests a relation with the intense and prolonged seizures presented by the patient<sup>20</sup>. A further hypothesis for neuronal loss in the thalamus is the disturbance of local blood flow. In cases of temporal lobe hernia, compression of posterior cerebral artery branches in the fossa interpeduncularis may occur, causing ischemia in some parts of the thalamus<sup>16</sup>. This may have occurred in the two cases in which thalamic neuronal loss was associated with old multiple infarcts in the homolateral cerebral hemisphere. The former pathogenetic factor — a sudden fall in systemic arterial pressure — can explain the reduction of nerve cells in the Sommer sector in the hippocampus in one case, and diffuse severe regressive ischemic phenomena in cerebral cortex neurons (in the base of the gyri), in the hippocampus, in the thalamus, in the inferior olivary nucleus, in the dentate nucleus and in cerebellar Purkinje cells, in another case (see, also, Scholz<sup>24</sup> and Adams<sup>1</sup>).

#### SUMMARY

The pathological systematized study of the brain of 31 cases of the chronic cardiac form of Chagas' disease was undertaken. Elective parenchymatous necrosis was found in 64.5% of cases, mainly in cerebellar Purkinje cells, and in thalamic nuclei. Also found were multiple foci of old micronecrosis (51.6%) mostly in the cerebral cortex, old cerebral infarcts (22.6%), cortical laminar necrosis (16.1%) and cerebral cortical atrophy (3.2%). These findings are not specific and can be explained by thromboembolic phenomena and hypoxemia following from congestive heart failure and disturbances of the cardiac rhythm.

## RESUMO

*Alterações cerebrais isquêmicas na cardiopatia chagásica crônica*

Fez-se o estudo anatomopatológico sistematizado do encéfalo de 31 casos da forma crônica cardíaca da doença de Chagas. Encontrou-se necrose parenquimatosa eletiva em 64,5% dos casos afetando principalmente as células de Purkinje do cerebelo e alguns núcleos talâmicos, focos múltiplos de micronecrose antiga (51,6%) especialmente do córtex cerebral, enfartes cerebrais antigos (22,6%), necrose cortical em faixa (16,1%) e atrofia cortical cerebral (3,2%). Estes achados são inespecíficos e podem ser explicados em função de fenômenos trombo-embólicos e de hipoxemia decorrente de insuficiência cardiovascular bem como de distúrbios do ritmo cardíaco.

## REFERENCES

1. ADAMS, J. H.; BRIERLEY, J. B.; CONNOR, R. C. R. & TREIP, C. S. — The effects of systemic hypotension upon the human brain. Clinical and neuropathological observation in 11 cases. *Brain* 89:235, 1966.
2. ADAMS, J. H. — Ischemic brain damage in arterial boundary zone in man. *In* J. Cervós-Nazarro & W. de Gruyter (eds.) — *Pathology of Cerebral Microcirculation*. Berlin, 1974.
3. ALENCAR, A. — Atrofia cortical na cardiopatia crônica chagásica. *O Hospital (Rio)* 66:807, 1964.
4. ALENCAR, A. — Sobre a atrofia cortical chagásica. *An. Acad. bras. Ciênc.* 38:89, 1966.
5. ALENCAR, A. — Alterações cerebelares em pacientes com cardiopatia crônica chagásica. *Arq. Neuro-Psiquiat.* (São Paulo) 25:191, 1967.
6. ANDRADE, Z. A. — Fenômenos trombo-embólicos na cardiopatia crônica chagásica. *An. Congr. internac. Doença de Chagas*, 1959, pg. 73.
7. ANDRADE, Z. A. & SADIGURSKY, M. — Trombo-embolismo em chagásicos sem insuficiência cardíaca. *Gaz. méd. Bahia* 71:59, 1971.
8. BERNSMEIER, A.; GOTTSSTEIN, U. & RUDOLPH, W. — Herzkrankheiten als Ursache zerebeler Zirkulationsstörungen. *Dtsch. med. Wochschr.* 87:16, 1962.
9. BODECHTEL, G. — Gehirnveränderungen bei Herzkrankheiten. *Z. Neurol. Psychiat.* 140:657, 1932.
10. BRANDÃO, H. J. S. & ZULIAN, R. — Nerve cell depopulation in chronic Chagas' disease. A quantitative study in the cerebellum. *Rev. Inst. Med. trop. S. Paulo* 8:281, 1966.
11. CERVÓS-NAVARRO, J. — Gefässerkrankungen und Durchblutungsstörungen des Gehirns. *In* W. DOERR & G. SEIFERT (eds.) — *Spezielle pathologische Anatomie, Band 13/I, Pathologie des Nervensystems I, Durchblutungsstörungen und Gefässerkrankungen des Zentralnervensystems*. Springer, Berlin, 1980.
12. CHAGAS, C. — Nova entidade mórbida do homem. Resumo geral de estudos etiológicos e clínicos. *Mem. Inst. Oswaldo Cruz* 3:219, 1911.
13. COSTA, R. de B. & GALLINA, R. A. — Hipotálamo anterior na moléstia de Chagas humana. *Rev. Inst. Med. trop. São Paulo* 13:92, 1971.
14. ERBSLÖH, F. — Das Zentralnervensystem bei Krankheiten des Herzens und der Lungen. *In* F. HENKE, O. LUBARSCH & R. RÖSSLE (eds.) — *Handbuch der speziellen pathologischen Anatomie und Histologie: Nervensystem* (W. Scholz, ed.). Springer, Berlin, 1958, pg. 1333.
15. LARANJA, F. S.; DIAS, E.; NÓBREGA, G. & MIRANDA, A. — Chagas' disease. A clinical, epidemiologic and pathologic study. *Circulation* 14:1035, 1956.

16. LINDENBERG, R. — Compression of brain arteries as pathogenetic factor for tissue necroses and their areas of predilection. *J. Neuropathol. exp. Neurol.* 14: 223, 1955.
17. LOPES, E. R.; TAFURI, W. L. & CHAPADEIRO, E. — Estudo morfológico e quantitativo dos núcleos dorsal do vago e hipoglosso em chagásicos crônicos com e sem megaesôfago. *Rev. Inst. Med. trop. São Paulo* 11:123, 1969.
18. NEIVA, A. R. & ANDRADE, Z. A. — Embolia cerebral em portadores de miocardite crônica chagásica. *O Hospital (Rio)* 61:373, 1962.
19. NUSSENZWEIG, I; WAJCHEMBERG, B. L.; MACRUZ, R.; SPINA FRANÇA NETTO, A.; TIMONER, J. & SÉRRO AZUL, L. G. do — Acidentes vasculares cerebrais embólicos na cardiopatia chagásica crônica. *Arq. Neuro-Psiquiat. (São Paulo)* 11:386, 1953.
20. PETERS, G. — *Klinische Neuropathologie (Zweite Auflage)*. Georg Thieme Verlag, Stuttgart, 1970, pg 273.
21. QUEIROZ, A. C. de — Estudo anatomopatológico do encéfalo na forma crônica da doença de Chagas. *Rev. Pat. trop.* 7:135, 1978.
22. RASO, P. & TAFURI, W. L. — O peso do encéfalo normal no brasileiro adulto. *An. Fac. Med. Univ. Minas Gerais* 20:231, 1960.
23. REUCK, J. de; SIEBEN, G.; COSTER, W. de & VANDER EECKEN, H. — Fatal intracranial hypertension in patients with cerebral infarction. *In* J. S. Meyer, H. Lechner, M. Reivich, E. O. Ott & A. Aranibar (eds.) — *Cerebral Vascular Disease* 3. Excerpta Medica, Amsterdam, 1981, pg 324.
24. SCHOLZ, W. — An nervöse Systeme gebundene (topistische) Kreislaufschäden. *In* O. LUBARSCH, F. HENKE & R. RÖSSLE (eds.) — *Handbuch der speziellen pathologischen Anatomie und Histologie: Nervensystem* (W. Scholz. ed.). Springer Verlag, Berlin, 1957, pg 1326.
25. STILL, W. J. S. — Endocardial fibroelastosis. *Am. Heart J.* 61:579, 1961.

*Laboratório de Neuropatologia, Departamento de Anatomia Patológica e Medicina Legal — Faculdade de Medicina da Universidade Federal de Minas Gerais — Av. Alfredo Balena 190 — 30000 Belo Horizonte — Brasil.*