

OLFACTORY GROOVE MENINGIOMAS

Surgical technique and follow-up review

*Benedicto Oscar Colli¹, Carlos Gilberto Carlotti Junior²,
João Alberto Assirati Junior³, Marcius Benigno Marques dos Santos³,
Luciano Neder⁴, Antonio Carlos dos Santos⁵, Nayara Cioffi Batagini⁶*

ABSTRACT - Background: Olfactory groove meningiomas comprise 4-10% of the intracranial meningiomas. Generally they give signs of brain compression due to great size they reach before diagnosis. In this study, the clinical outcome of patients with olfactory groove meningiomas surgically treated was analyzed. **Method:** 17 patients operated on from 1988-2006. Female: 16, Male: 1. Age: 19-76 years-old (mean=53.12±13.11). Follow-up: 1-209 months (mean=51.07±12.73). Bifrontal/bifrontal-bi-orbital approaches were used. Outcome was analyzed using survival/recurrence-free Kaplan-Mayer curves. **Results:** 16 had WHO grade 1; one grade 2 meningiomas. Resection Simpson's grade 1 was in achieved in 64.7%, grade 2 in 29.4% and grade 3 in 5.9%. There was no recurrence during the follow-up. Global and operative mortality were 11.8%. Main postoperative complications were osteomyelitis (11.8%) and pneumonia (5.9%). **Conclusion:** Extensive approaches allowed total resection of most olfactory groove meningiomas with no recurrence during the follow-up, but operative mortality and local complications were high.

KEY WORDS: olfactory groove meningiomas, surgical treatment, survival curves.

Meningiomas da goteira olfatória: técnica cirúrgica e resultados

RESUMO - Introdução: Os meningiomas da goteira olfatória constituem 4-10% dos meningiomas intracranianos. Geralmente eles causam sinais de compressão do tronco cerebral porque atingem grandes tamanhos antes do diagnóstico. Neste estudo foram analisadas os resultados do tratamento cirúrgico de pacientes com meningiomas da goteira olfatória. **Método:** 17 pacientes operados de 1988-2006. Mulheres: 16. Homens: 1. Idade: 19-76 anos (média=53,12±13,11). Seguimento: 1-209 meses (média=51,07±12,73). Foram utilizados acessos bifrontal/bifrontal bi-orbital. A evolução clínica foi analisada usando curvas de sobrevivência e de sobrevivência livre de doença de Kaplan-Mayer. **Resultados:** 16 pacientes tinham meningioma WHO grau 1; um tinha meningioma grau 2. Ressecção Simpson grau 1 foi obtida em 64.7%, grau 2 em 29.4% e grau 3 em 5.9%. Não houve recidiva durante o seguimento. A mortalidade global e a pós-operatória foram 11.8%. As principais complicações pós-operatórias foram osteomielite (11.8%) e pneumonia (5.9%). **Conclusão:** Abordagens extensas possibilitaram ressecção total da maioria dos meningiomas da goteira olfatória sem recidiva durante o seguimento, mas a mortalidade operatória e as complicações locais foram altas.

PALAVRAS-CHAVE: meningiomas da goteira olfatória, tratamento cirúrgico, curvas de sobrevivência.

Olfactory groove and tuberculum sellae meningiomas are the most frequent tumors located in the fronto-basal midline. Despite being separated in its origin by a short distance, they have quite different clinical, radiological, and anatomical relationships. Olfactory groove meningiomas comprise 4 to 10% of the intracranial meningiomas¹⁻³. These tumors originate in the transition of the cribriform plate and pla-

num sphenoidale and the first structures they reach are the olfactory nerves, but symptoms resultants from this compression are frequently neglected.

Usually they are diagnosed when they cause mental deterioration or seizures because of its great size³⁻⁶. Therefore, the size of these tumors is a major problem for their surgical treatment. In addition, the frequent invasion of the paranasal sinuses, the possibil-

Division of Neurosurgery, Department of Surgery, Hospital das Clínicas, Ribeirão Preto Medical School, University of São Paulo, Ribeirão Preto SP, Brazil: ¹Professor of Surgery, Head of the Division of Neurosurgery, Ribeirão Preto Medical School - USP; ²Associated Professor, Division of Neurosurgery, Ribeirão Preto Medical School - USP; ³Neurosurgeon, Division of Neurosurgery, Hospital das Clínicas de Ribeirão Preto - FMRP/USP; ⁴Assistant Professor, Department of Pathology, Ribeirão Preto Medical School - USP; ⁵Assistant Professor, Department of Radiology, Ribeirão Preto Medical School - USP; ⁶Medical Student, Ribeirão Preto Medical School - USP.

Received 30 January 2007, received in final form 11 April 2007. Accepted 25 May 2007.

Dr. Benedicto Oscar Colli - Departamento de Cirurgia / HCFMRP - 14048-900 Ribeirão Preto SP - Brasil. E-mail: bocolli@fmrp.usp.br

ity of cerebrospinal leak and infection, become complete removal of these tumors a challenge⁴.

In this study, the clinical outcome of patients with olfactory groove meningiomas surgically treated was analyzed with emphasis to the surgical approaches, microsurgical anatomy, extension of resection and recurrence.

METHOD

Patient population – Fronto-basal meningiomas comprised 12.6% (41) and olfactory groove 5,2% (17) of 325 patients with a radiological diagnosis of intracranial meningioma assisted from 1984 to 2006 at the Division of Neurosurgery of the Hospital das Clínicas - Ribeirão Preto Medical School. The design of this study was a retrospective review of data on 17 consecutive olfactory groove meningiomas submitted to surgical treatment. Diagnosis of tumors was performed using computed tomography (CT) scans and/or magnetic resonance images (MRI) of the skull. All patients had grade 1 meningiomas according to the histopathological WHO classification⁷, 16 patients presented benign grade I meningiomas (8 transitional, 7 meningothelial, 1 secretory), and 1 had grade 2 (atypical) meningioma.

Clinical findings – There was a great female predominance (average female/male rate of 16:1) and age ranged from 19 to 76 years-old (mean=53.12±13.11). Follow-up ranged from 1 to 209 months (mean=63.8±16.3). The clinical findings presented at diagnosis by the patients olfactory groove meningiomas were headache in 11, anosmia in 5, and seizures in 5 patients.

Surgical treatment – The goal of the surgical treatment was complete resection of tumor and resection of the dural attachment and involved bone whenever possible. The patients were operated on using microsurgical techniques and special attention was done to preoperative evaluation of the size and position of the frontal sinus, presence of hyperostosis and the relationship between the tumor and the anterior cerebral arteries using CT scans and MRI.

Most tumors of the olfactory groove were operated on through a bifrontal approach with resection of one orbit-

al rim. More recently we have used the bifrontal approach above the frontal sinus for these tumors. For the bifrontal craniotomy (Fig 1), the patient is placed in the supine position and the scalp incision is bicoronal. A lumbar drain is implanted preoperatively for eventual CSF drainage for brain relaxing. The skin flap is elevated and the periosteum is cut along the superior temporal lines and posterior to the coronal sutures, providing a large flap centered in the frontal base for covering the frontal sinus and the floor of the anterior fossa, after tumor resection. The craniotomy is performed with two paramedian frontal burr holes (behind the hair line) and another posterior to the zygomatic process, in the fronto-orbital transition, for resection of orbital rim. Other burr holes may be necessary and when the frontal sinus is large, a window may be performed in the anterior wall of the frontal sinus from a small burr hole for facilitating the anterior section of the craniotomy. The posterior wall of the frontal sinus is resected, the mucosa is exenterated and the remaining of the sinus is treated with an antiseptic solution and occluded with peaces of muscle, for preventing postoperative infection. The dura-mater is opened parallel to the base of the frontal and the superior sagittal sinus is sutured and cut together with the falx cerebri, allowing partial exposure of the tumor. Gentle postero-lateral retraction of the frontal poles allows better exposition of the tumor. The tumor is debulked for allowing its displacement from the brain surface and it is piecemeal resected, exposing the anterior cerebral artery and the optic nerves. The involved dura and bone is resected whenever possible and after resection of the involved bone the floor of the anterior fossa is covered with fascia lata and fat graft sutured to the adjacent dura-mater and to the dura-mater of the tuberculum sellae. The periosteum is reflected over the frontal sinus and anterior fossa and the dura-mater is sutured to the periosteum, close to the cranial base, providing an isolation of the subarachnoidal space from the paranasal sinuses. The window in the frontal sinus is closed.

The extent of resection was assessed macroscopically during surgery and postoperatively using CT or MR imaging 48 hours and 6 months after operation. Extent of resection was classified according Simpson⁸: 1. Complete resection of tumor, dural attachment and involved bone; 2.

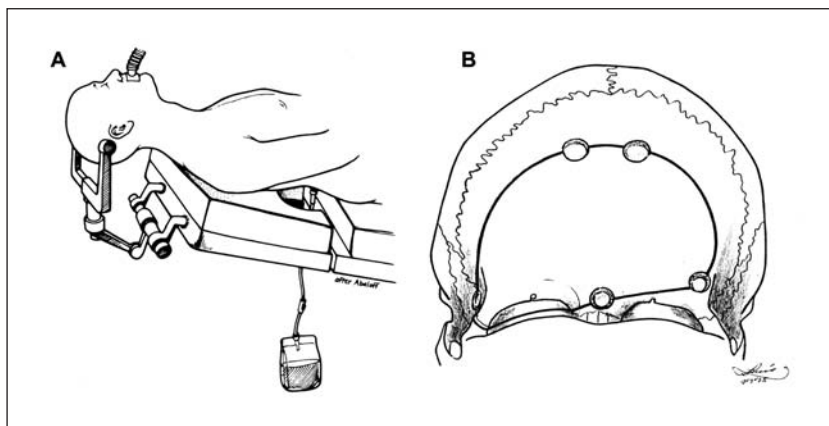


Fig 1. Bifrontal craniotomy with orbital rim resection approach for olfactory groove meningiomas. (A) Positioning of the patient with a lumbar drain that can be opened if brain relaxation is needed. (B) Burr-holes. Two burr-holes are placed paramedian under the hair line, one retrozygomatic, one above the nasion and one lateral on the contralateral frontal bone. The craniotome and resection of the orbital rim are done in the same way as the fronto-orbito-temporal craniotomy.

Complete resection of tumor and coagulation of dural attachment; 3. Complete resection of tumor, no dural coagulation; 4. Partial removal of tumor; and 5. Biopsy. Eleven (64.7%) patients had grade 1 resection, 5 (29.4%) had grade 2, and one had grade 3 (2.4%).

Functional outcome – The preoperative, postoperative (first 10 days) and the follow-up outcome were analyzed using the Karnofsky Performance Scale (KPS) to measure the degree of disability. Patients were classified into one of three groups. 1) Normal function or minimal symptoms and ability to work (KPS score 80-100), 2) Independent but not able to work (KPS score=70), and 3) Moderate or severe disability (KPS score \geq 50). For patients who experienced tumor recurrence and consequent clinical deterioration, the best KPS score obtained during the follow-up course was used. For patients who died during the immediate postoperative course, the KPS score acquired before death was used to indicate both the immediate postoperative and follow-up scores. Four patients did not attend 6 months follow-up due to death or end of follow-up and they did not receive a KPS score at this time.

Follow-up was analyzed using the Kaplan-Mayer survival and recurrence free survival (RFS) curves comparing patients in relation to location of tumor, sex, and extent of resection.

Statistical analysis – Statistical analysis was performed using the Chi-square and Fisher exact tests for comparing proportions, the Mann-Whitney test for comparing medians, and the log-rank test for comparison of survival curves and rates. An α -error probability not exceeding 5% was considered significant for two-tailed probability tests. The tests were performed using Graph Pad PRISM (version 3.0; Graph Pad Software Inc. San Diego, CA, USA).

RESULTS

Survival and recurrence – Figure 2 presents the survival curves for patients with olfactory groove meningiomas. The 5-year and the 10 year survival estimates were 83.9%. There was no recurrence among patients with olfactory groove meningiomas.

Mortality and morbidity – Four (23.5%) patients with olfactory groove meningiomas, died during the follow-up. Operative mortality (during the first 30

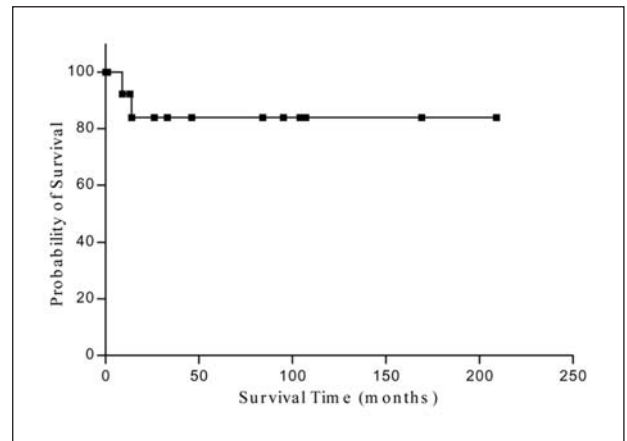


Fig 2. Survival curve for patients with olfactory groove meningiomas (n=15).

postoperative days) was 11.8% (2 patients). Causes of death were hemorrhage and pulmonary infection. Two other patients died during the follow-up due to causes not related to the tumor.

Four patients with olfactory meningiomas had local postoperative infection (soft tissue in 2, epidural empiema/osteomyelitis in one, and osteomyelitis in one), one developed a postoperative transient monoparesis, one a transient dysphasia, 2 patients developed epileptic seizures and one patient developed postoperative brain edema and another presented a transient ptosis of the upper lid. Urinary infection, pulmonary infection and sepsis were observed in one patient with OG meningiomas (death).

Postoperative functional outcome – Preoperative, immediate postoperative and follow-up functional disabilities assessed by KPS are presented in Table. The scores were similar (Chi-Square test, df=2, p=0.2733), for patients that returned to work (KPS 80-100).

DISCUSSION

Surgical treatment – The treatment of olfactory groove meningiomas is predominantly surgical.

Table. Preoperative, postoperative, and follow-up functional status*.

Functional status	KPS score	Preoperative	Immediate postoperative	Follow-up
N° of patients		17	16	13
Normal or minimal symptoms & working	80-100	12 (70.6%)	10 (62.5%)	9 (69.2%)
Independent, not working	70	4 (23.5%)	5 (31.3%)	3 (23.1%)
Moderate or severe disability	50	1 (5.9%)	1 (6.2%)	1 (7.7%)

* There was no significant difference for patients that returned to work (KPS 80-100) for all evaluations (Chi-Square test, df=2; p=0.2733).

These tumors reach great size before give symptoms, and the size tumor and the invasion of the paranasal sinuses, are the major challenge for their surgical treatment³⁻⁶.

Endonasal approaches have been recently used for treating fronto-basal meningiomas⁹⁻¹¹ but, despite of its advantages, most authors prefers intracranial approaches for resecting olfactory meningiomas^{3,4,6,12-15}. We have used bifrontal craniotomy with or without unilateral orbital rim resection for resection of these tumors.

Survival – Survival of patients with fronto-basal meningiomas depends on the histopathological grade of tumors. As all but one patient in our series were WHO grade 1 meningiomas, survival was not influenced by the tumor histology and it was similar between females and males.

Recurrence – Recurrence of olfactory groove meningiomas is considered not frequent (0 to 13,6%^{5,6,12,14,15}, but Obeid and Al-Mefty¹³ report that it is higher (average, 23%), reflecting incomplete resection of involved bone and regrow at the edge of previous surgical field.

Many factors are imputed to influence on recurrence of all intracranial meningiomas. For some of then this role is incontestable but for others it is controversial. Most authors agree that recurrence rates for patients with atypical or malignant meningiomas are greater than for patients with WHO grade 1^{16,17,20}. Regarding age and sex, some authors related that the risk is increased and the delay of recurrence is shorter in younger patients and that there is no difference in the recurrence among sex for patients with all intracranial meningiomas^{8,18}. Simpson⁸, in 1957, established the recurrence of meningiomas according the extent of resection and since then other authors have confirmed his findings^{4,19,20}. As there was no recurrence among patients with olfactory groove meningiomas in our series, we could not confirm these findings.

Mortality and morbidity – Operative mortality for resection of fronto-basal meningiomas in the old series varied from 10 to 67%(1,3), and most recent series report no or low mortality for olfactory meningiomas^{4,12,14,15}. Mortality is associated with old age^{21,22}. Operative mortality for patients with olfactory groove meningiomas was 11.8% (one due to hemorrhage and another due to pulmonary infection).

Morbidity after resection of groove meningiomas remains significant. Infection and cerebrospinal fluid leak are potential risks for entering the frontal sinus

or the etmoidal cells. Exenterates the sinus mucosa, resection of the posterior wall of the frontal sinus and packing the sinus with muscle are important precautions to avoid these complications^{4,13}. In our series, local postoperative complications were observed in 23.5% of patients with olfactory groove meningiomas (soft tissue infection, epidural empyema/osteomyelitis, and osteomyelitis). Transient ptosis of the upper lid was observed in 1 patient submitted to orbital rim resection, probably due to trauma to the orbital content.

Intraoperative complications include injury to cerebral vessels, mainly the anterior cerebral artery complex^{1,5,20}, and this has been cause of partial resection^{4,5}. In our series, postoperative neurological deficits in four patients with OG meningiomas (transient monoparesis in one and dysphasia in one, and 2 patients with epileptic seizures).

Among systemic postoperative complications, pulmonary infection and pulmonary embolism are severe problems observed in patients underwent meningioma resections, especially in patients who recover without neurological deficits⁴ and many times they are responsible for death. In our series, sepsis (death), and pulmonary infection occurred in one patient each.

Postoperative functional outcome – Functional neurological outcome for patients with olfactory meningiomas generally is good. There was no significant difference between the number of patients able to work (KPS 80-100) preoperatively and at 6 months postoperative.

In conclusion, extensive approaches allowed total resection of most olfactory groove meningiomas with no recurrence during the follow-up, but operative mortality and local complications should be considered.

REFERENCES

1. Cushing H, Eisenhardt L. Meningiomas: their classification, regional behavior, life history, and surgical end results. Springfield: Charles C. Thomas, 1938.
2. Quest DO. Meningiomas: an update. *Neurosurgery* 1978;3:219-225.
3. Solero CL, Giombini S, Morello G. Suprasellar and olfactory meningiomas: report on a series of 153 personal cases. *Acta Neurochir (Wien)* 1983;67:181-194.
4. Al-Mefty O. Tuberculum sellae and olfactory groove meningiomas. In Sekhar LN, Janecka IP (Eds). *Surgery of cranial base tumors*. New York: Raven Press 1993:507-519.
5. Ojemann RG. Surgical management of meningiomas of the tuberculum sellae, olfactory groove, medial sphenoid wing, and floor of the anterior fossa. In Schmidek HH, Sweet WH (Eds). *Operative neurosurgical techniques: indications methods and results*, 3.Ed., vol. 1. New York: Grune & Stratton 1995:393-401.
6. Symon L. Olfactory groove and suprasellar meningiomas. In: Krayenbuhl H (Ed). *Advances and technical standards in neurosurgery*. New York: Springer-Verlag 1977:67-91.

7. Kleihues P, Cavenee WK (Eds). Pathology and genetics of tumors of the nervous system. Lyon, IARC Press, 2000.
8. Simpson D. The recurrence of intracranial meningiomas after surgical treatment. *J Neurochem* 1957;20:22-39.
9. Cook SW, Smith Z, Kelly DF. Endonasal transsphenoidal removal of tuberculum sellae meningiomas: technical note. *Neurosurgery* 2004;55:239-244.
10. Couldwell WT, Weiss MH, Rabb C, Liu JK, Apfelbaum RI, Fukushima T. Variations on the standard transsphenoidal approach to the sellar region, with emphasis on the extended approaches and parasellar approaches: surgical experience in 105 cases. *Neurosurgery* 2004;55:539-547.
11. Dusick JR, Esposito F, Kelly DF, et al. The extended direct endonasal transsphenoidal approach for nonadenomatous suprasellar tumors. *J Neurosurg* 2005;102:832-841.
12. Hentschel SJ, DeMonte F. Olfactory groove meningiomas. *Neurosurg Focus* 2003;14:e4.
13. Mathiesen T, Kihlstrom L. Visual outcome of tuberculum sellae meningiomas after extradural optic nerve decompression. *Neurosurgery* 2006;59:570-576.
14. Obeid F, Al-Mefty O. Recurrence of olfactory groove meningiomas. *Neurosurgery* 2003;53:534-542.
15. Spector S, Valarezo J, Fliss DM, et al. Olfactory groove meningiomas from neurosurgical and ear nose, and throat perspectives: approaches, techniques, and outcomes. *Neurosurgery* 2005;57:268-280.
16. Maier H, Öfner D, Hittmair A, Kitz A, Budka H. Classic, atypical, and anaplastic meningiomas: three histopathological subtypes of clinical relevance. *J Neurosurg* 1992;77:616-623.
17. Mahmood A, Caccamo DV, Tomecek FJ, Malik GM. Atypical and malignant meningiomas: a clinicopathological review. *Neurosurgery* 1993;33:955-963.
18. Philippon J, Cornu P. The recurrence of meningiomas. In Al-Mefty O (Ed). *Meningiomas*. New York: Raven Press 1991:87-105.
19. Chan RC, Thompson GB. Morbidity, mortality, and quality of life following surgery for intracranial meningiomas: a retrospective study in 257 cases. *J Neurosurg* 1984;60:52-60.
20. Jääskeläinen J. Seemingly complete removal of histologically benign intracranial meningioma: late recurrence rate and factors predicting recurrence in 657 patients. A multivariate analysis. *Surg Neurol* 1986;26:461-469.
21. Pamir MN, Ozduman K, Belirgen M, Kilic T, Ozek MM. Outcome determinants of pterional surgery for tuberculum sellae meningiomas. *Acta Neurochir (Wien)* 2005;147:1121-1130.
22. Sankila RK, Kallio M, Jääskeläinen J, Hakulinen T. Long-term survival of 1986 patients with intracranial meningioma diagnosed from 1953 to 1984 in Finland. Comparison of the observed and expected survival rates in population-based series. *Cancer* 1992;70:1568-1576.