

NORMAL NERVE-FIBRES IN THE DISTAL SEGMENT OF NERVES COMPLETELY SEPARATED FROM THE PROXIMAL STUMP FOR MORE THAN SIX MONTHS

EROS ABRANTES ERHART *

It has been universally accepted that several weeks after nerve section, most of the axis-cylinder and myelin sheath have disappeared due to nerve degeneration, and that after a prolonged period, the severed distal segment manifests changes that are considered inhibitory to subsequent regeneration: Holmes and Young¹⁰, Sanders and Young¹⁵, Abercrombie and Johnson¹, Sunderland¹⁸, Seddon¹⁶, Nicholson and Seddon¹², and others.

Boeke³ discussing the nerve regeneration problem writes the following: "The question of the regeneration of the nervous system has to be studied morphologically and physiologically, but in this study it is dangerous to begin with the classical neuron theory as its unshakable basis, for this would lead us further and further away from the ascertained facts and hamper us in every respect, both histologically and physiologically. We have simply to try to understand rightly the complicated structure of the nervous system, its plasticity and, on the other hand, its conservativeness and its integrative action. We do not need to adhere to the obsolete conceptions and formulae of the last century. We need to form new paths, to achieve new outlooks, to admit that the structure of the body is far more complicated than the older scientists thought it to be. But in this we must not be impeded and obstructed by obsolete formulae, however important they may have been for the advancement of science in the past and however important they remain. We have to search for a new basis or more modern structure than the old classical neuron theory. As Cajal himself said in his last paper (1936) — 'We must never forget that our knowledge of the nervous system is still very incomplete and that the leading thought of the histologist must be a wise skepticism. A science which

Este trabalho "Sobre a existência de fibras nervosas integras no segmento distal de nervos com mais de seis meses de secção completa" foi apresentado como Tese no Concurso para Habilitação à Docência-Livre de Anatomia, Histologia e Embriologia na Fac. Med. de Ribeirão Preto da Univ. São Paulo.

* Professor Assistente de Anatomia, Chefe da Secção de Neur Anatomia, Departamento de Anatomia da Fac. Med. Univ. São Paulo (Prof. O. Machado de Sousa).

acquired its methods only forty years ago cannot already possess the key for the understanding of its structure, which will be the greatest problem for years to come'."

Guth⁸ states: "Data about the effects of long-term degeneration will undoubtedly be of great fundamental and practical importance, and Gutman⁹: "Obgleich die Diskussion über die Möglichkeit der autogenen Regeneration durch die Entwicklung der Neuronenlehre noch nicht abgeschlossen ist, erachteten die meisten Forscher dieses Problem als gelöst". This last Author suggests besides, that more experiments and new methods must be developed in order to look for the neuronal biosynthesis behavior and its relation to the Schwann cells in normal and degenerated nerve fibres.

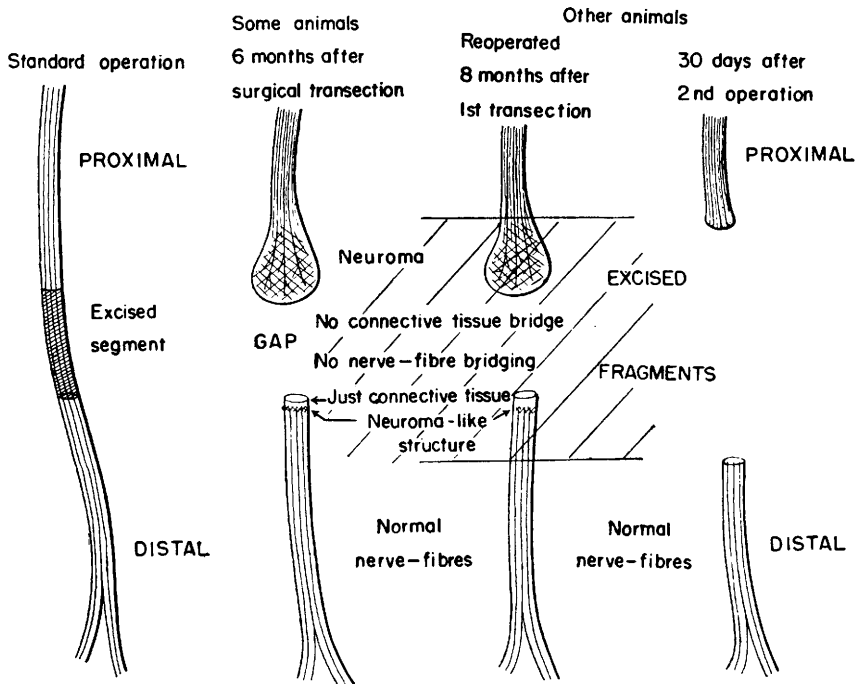
Barros de Abreu and Erhart² have found normal axis-cylinders and practically normal nerve bundles in the distal segment of human nerves — median, ulnar and radial — which had been completely severed for many years. These injured nerves were examined at the time these patients were submitted to nerve suture of the injured nerve trunks at the Medical School Hospital, Universidade de São Paulo, Brasil.

Seven such patients showing typical clinical pictures of nerve lesions were examined 1.5 to 24 years after accidental nerve section. The gap between the two stumps varied from one to seven centimeters and no gross anastomoses with other nerve were evident in the surgical field. In the histological serial cross-sections of the gap region, nerve fibres could not be found, nor were collateral sprouts noted in the distal stump.

MATERIAL, METHODS, RESULTS

In order to study these unexpected findings the following experiments were performed: Complete surgical transection of the fibular nerve was done at the knee level of fourteen adult dogs under general anesthesia, and from each, one half centimeter of nerve was excised. The severed ends of the nerves did not receive any special care in order to imitate as close as possible what could happen in an accident. The animals immediately after the operation showed complete motor and sensory loss in the territory of the fibular nerve.

About six months later the healed wounds of four dogs, under general anesthesia, were opened (Scheme 1). Each proximal stump showed a neuroma; a wide gap was present between the two stumps and the distal segment was frequently hidden between muscles, having retracted considerably distally. There was no connective tissue bridge between the two stumps in these four dogs.



Scheme 1 — Operations done on dogs fibular nerves.

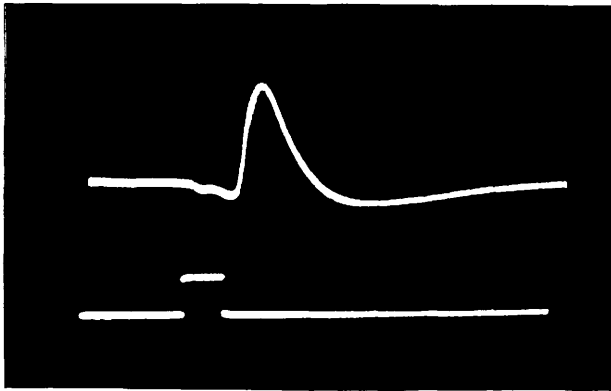
Serial De Castro histological silver preparations were made from the proximal and distal nerve segments as well as from the gap region, and the same picture described before in the human material could be seen in these dog nerves. In longitudinal and transverse sections of the distal segment, normal axis-cylinders and small nerve bundles were evident (Fig. 1), although nerve fibres could not be found in the gap region, Erhart and Erhart⁷.

Continuing with the study, the distal segment of the fibular nerve of dogs which had been sectioned eight, twelve and eighteen months previously were examined. Normal axis-cylinders and nerve bundles were again evident in the silver preparation, but they were thicker and greater in number (Figs. 2 and 3) than those seen in the nerves of the dogs which had been examined six months post-operatively.

Using other histological methods (Hematoxylin and Eosin, Pal-Weigert modified by Erhart, Mallory, and Van Gieson), the presence of myelin could be revealed in the long-term severed distal segments (Figs. 4 and 5), as well as proliferation and hypertrophy of neurilemma cells and increase of nerve connective tissue components.

A neuroma-like structure of nerve-fibres was also observed in some slides of the distal stump, close to the site of section. Such a structure was also found in human material (Fig. 16).

We were able to find electrical action potential from the isolated (in a plastic chamber) distal segment of dog fibular nerves which had been completely separated from the proximal stump for more than six months.



Record of action potential obtained from the distal segment of dog fibular nerve six months after complete surgical transection. Stimulus 10 to 15 V; time = 2 msec; calibration — 0.5 mV/inch.

As nerve fibres were not found in the gap region, four dogs, which had had completely severed nerves and separated stumps for more than eight months, were reoperated, because according to the neuron theory, in order to explain the presence of normal axis-cylinders and nerve bundles in the distal stump, there should be in some place a nerve-fibre bridging between the two stumps.

In this second operation (Scheme 1), under general anesthesia, the neuroma of the proximal stump and the most proximal segment of the distal stump were excised. While cutting the neuroma, the dog's leg did not show any reaction, but when the distal stump was cut, there was always an obvious contraction of muscles innervated by the fibular nerve.

Similar reactions were observed in human patients while being submitted to nerve suture of long-term injured nerve trunks.

In serial sections of the proximal end of the distal stump, normal axis-cylinders and normal nerve-fibre bundles could always be found.

From the tissue of one of these dogs the following was shown: a) the most proximal sections of the distal stump — just connective tissue, no nerve-fibres; b) in the proximal 2/5 of the distal stump — few and diffuse nerve-fibres beginning to appear; c) in the intermediate 3/5 — many nerve-fibres forming a neuroma-like structure; d) in the 4/5 — nerve bundle reorganization; e) in the most distal sections of the fragment of the distal stump, nerve bundles completely reorganized approximating the appearance of normal nerve. In these reorganized nerve bundles, normal nerve-fibres appear diffusely spread among the degenerated ones.

Thirty days after this second operation the healed wounds of these four dogs were reopened under anesthesia, and again no appreciable nerve degeneration was found (Scheme 1), and as noted before, when the completely separated distal segment of the nerve was cut, a muscular contraction was elicited.

Serial preparations again confirmed the previous observations.

At this point it must be emphasized that in all these experimental operations, at no time were any of the nerves or their segments isolated or disturbed from their surrounding bed (adjacent muscle or connective tissue) in order to avoid nutritional deficiencies, as much as possible, Erhart and Erhart⁶.

To explain how the nerve-fibres and nerve bundles were found in the distal segment of severed nerves, completely separated from the proximal stump for six or more months, and yet none were found in the gap region we thought of the possibility of very fine communications with neighbouring nerves which, by fibre sprouting and branching could repopulate the "degenerated" distal segment.

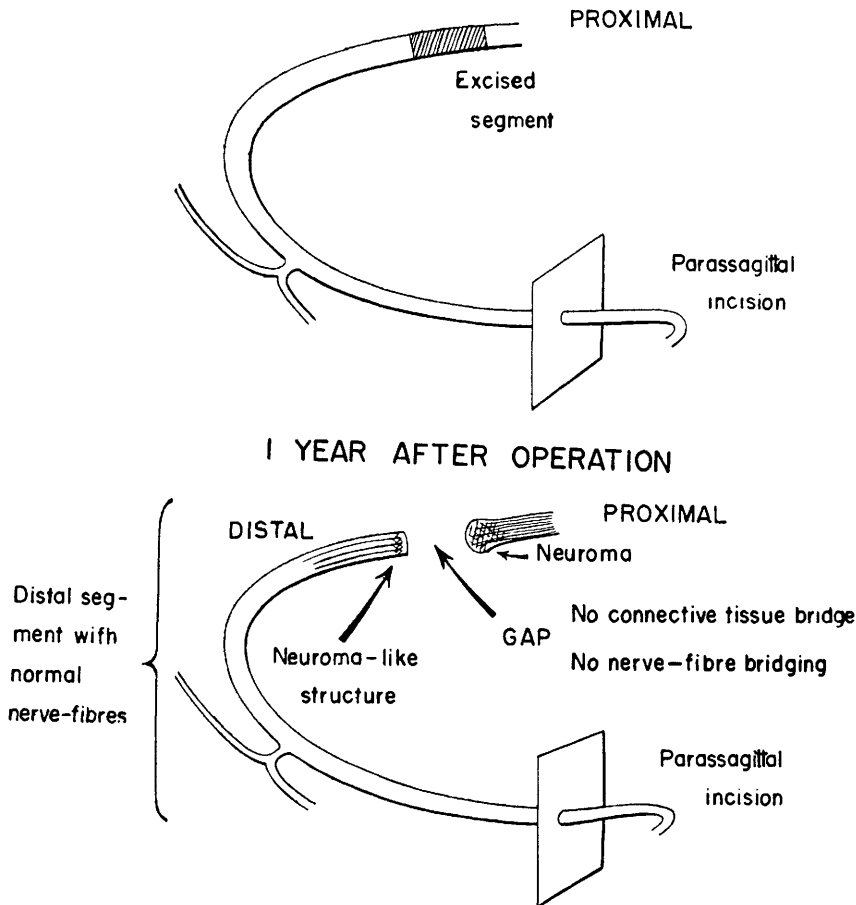
In order to study such an hypothesis, two more dogs were operated. Under general anesthesia, with artificial respiration, the thoracic cavity was widely open with a long parasagittal incision along the sternocostal joints.

By endothoracic route, one to two centimeters of each of the II to IX right intercostal nerves were excised. The proximal transection was about two to three centimeters from the corresponding intervertebral foramen (Scheme 2).

Twelve months later one of these dogs died. Necroscopy was done and again in longitudinal and transverse sections of the distal segments, normal nerve-fibres were evident (Figs. 7 and 8), although in the gap region nerve-fibres could not be found, nor were collateral sprouts observed in the distal stump.

The other dog was reoperated some days later under general anesthesia. When the thorax was opened there was an evident spontaneous fibrillation

of the whole muscular territory innervated by the II to IX intercostal nerves. The muscles were atrophic when compared to the homologous contralateral side.



Scheme 2 — Operations done on dogs intercostal nerves.

The distal segments of all the operated nerves were completely separated from the corresponding proximals and in some of the proximal stumps there were typical neuromas noticeable even to the naked eye.

Proximal and distal segments were carefully dissected and electrical stimulation was applied. While stimulating the proximal stumps, there was never muscular reaction, but when the distal ones were stimulated, there was always an evident contraction of muscles innervated by that nerve.

Similar results could also be observed in human nerves while testing the integrity of the distal segments in patients submitted to nerve suture of injured nerve trunks.

After curarization of the dog by intracardiac injection, responses to electrical and mechanical stimuli ceased although fibrillation remained. The "atrophic" muscles, however, responded when directly stimulated.

In the histological sections of the distal segment, normal nerve-fibres were again evident (Figs. 7 and 8).

As the intercostal nerves II to IX were cut off close to their emergence from the intervertebral foramina, and all their rami that could anastomose with homologous contralateral nerves, were sectioned by the parasagittal incision, any possible communications with intact nerves could be established only between nerves II and I and IX and X. It so happened that no difference of morphology or behavior could be observed when comparing the distal segments of the intercostal nerves II and IX with the others, chiefly IV, V and VI, theoretically the farthest from intact nerve trunks.

With this experiment it seems that the presence of normal nerve-fibres in the distal segment of nerves completely separated from the proximal stump, and maintained in its surrounding connective bed, cannot be explained through known nerve anastomoses or intercommunications.

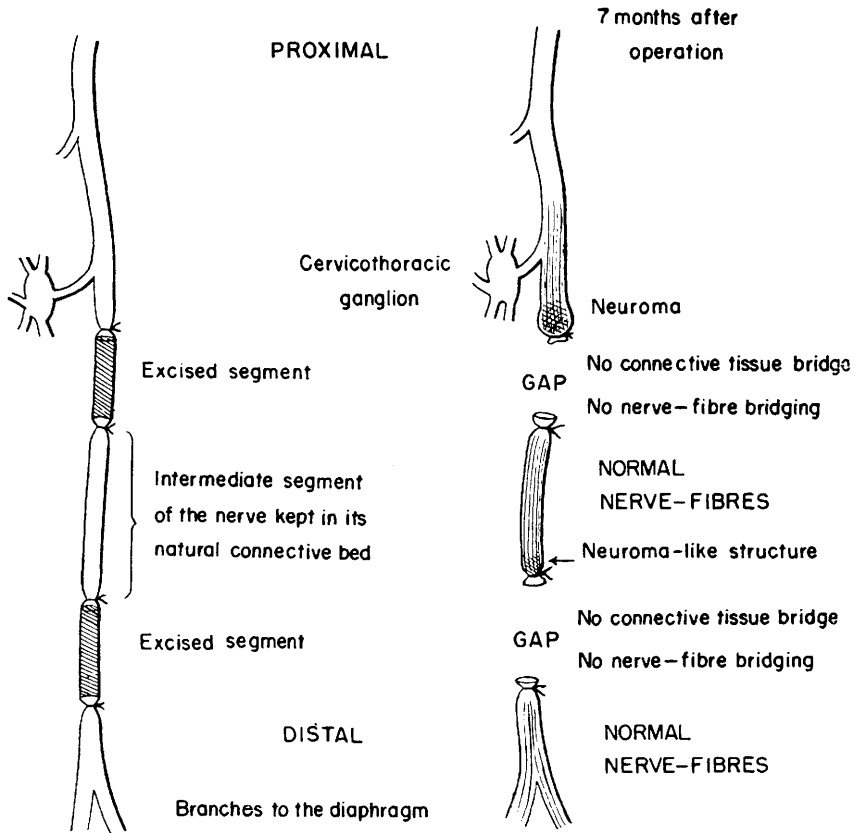
Could very fine and delicate nerve-fibers, poorly known, following perhaps blood vessels repopulate such distal "degenerated" nerve segments? Or could terminal organs (receptors and effectors) play some trophic action on the peripheral nerve-fibres? Let us remember that the distal segments, although completely separated from the proximal stumps, were maintained in their surrounding bed and had always intact their connections with the terminal organs.

With this in mind, another kind of operation was done using, this time, the phrenic nerve because of the advantage it offers us, in studying such problems.

Two more dogs were operated by endothoracic path and from each, two segments of two centimeters each were excised from the left phrenic nerve, to serve as control. The first, caudally at the level where the phrenic nerve has anastomoses with the cervico-thoracic ganglion of the sympathetic trunk, and the second, cranially at the origin of the main phrenic-diaphragm branches (Scheme 3). Each stump was tied with cotton in order to avoid, as much as possible, subsequent penetrations of nerve-fibres, and what was left of the phrenic nerve remained undisturbed in its natural connective tissue bed.

Seven months later, both dogs were reoperated under general anesthesia. When the thorax was open, the postero-lateral part of the left diaphragm dome showed some atrophy but no fibrillation.

The intermediate and distal segments of the operated phrenic nerve were completely separated one from another and from the proximal stump, which showed a typical neuroma (Scheme 3).



Scheme 3 — Operations done on dogs phrenic nerves.

Respiratory stimulation with CO_2 resulted in violent contractions of the right diaphragmatic half. The left one showed no contraction. The right half responded to electrical stimulation of the phrenic nerve — 0.5 V and 1 msec — and to direct stimulation — 5 V. In the left one, just very weak and isolated responses were obtained by direct stimulation — 90 V — only in some muscular fascicles of the anterior third of the left diaphragm.

Electrical action potentials could not be recorded from the intermediate nor from the distal segments of the operated phrenic nerves.

Histological sections of the intermediate and distal segments confirmed once more the previous observations: normal nerve-fibres were evident in both segments, although in the gap regions nerve-fibres could not be found, nor were collateral sprouts penetrating to any point of the intermediate or distal segments.

The intermediate segment of one of these operated phrenic nerves showed a nerve-fibre repopulation much more evident than the one of its correspondent distal segment. In the corresponding distal stump of this particular intermediate segment there was a typical neuroma-like structure (Scheme 3 and Fig. 11).

Based on our observations of these experimental studies, about one hundred patients with long-term nerve injuries (1.5 to 24 years) were submitted to nerve suture or neurolysis by different surgeons. In all severed nerves, normal nerve-fibres and nerve-bundles were evident in the serial sections of the distal stumps (Figs. 13, 14, 15 and 16).

These patients with long-term nerve lesions operated and treated under this orientation are showing an unexpectedly greater recovery of their motor and sensory functions, in spite of different degrees of the so-called "muscular atrophy due to denervation".

The exact statistical results in human cannot be declared herein because this paper chiefly concerns the experimental side of this problem. These clinical follow-up conclusions will be forthcoming in a later paper.

In each operation the surgeon always took great care to avoid disturbing the nerve and its bed, and cleanly excised all scar and neuromatous tissue from the site of injury, so as to be able to join normal nerve tissue of the proximal segment, to nerve tissue of the distal segment. When the interval between the two stumps is too wide, if necessary, the limb is shortened, but the nerve itself is always kept in its bed with its surrounding tissues. For these reasons grafts have not been used.

In no case did a clinical failure occur where these precautions were taken.

DISCUSSION

Although it is generally accepted that the severed distal segment manifests changes that are considered inhibitory to subsequent regeneration, our findings, whose explanation is still hypothetical in spite of the experiments done, lead us to a different conclusion.

PLATE 1

Fig. 1 — Nerve fibres in the distal stump of dog fibular nerve 6 months after complete surgical transection. Longitudinal section 8 μ , De Castro. ($\times 900$).

Fig. 2 — Nerve bundle in the distal segment of dog fibular nerve 8 months after complete surgical transection. Longitudinal section 8 μ , De Castro. ($\times 900$).

Fig. 3 — Nerve fibres in the distal segment of dog fibular nerve 8 months after complete surgical transection. Cross section 8 μ , De Castro ($\times 200$).

Fig. 4 — Nerve bundle in the distal segment of dog fibular nerve 8 months after complete surgical transection. Cross section 5 μ , H.E. ($\times 900$).

Fig. 5 — Myelin rings in nerve bundles of the distal segment of dog fibular nerve 8 months after complete surgical transection. Cross section 10 μ , Pal-Weigert modified by Erhart. ($\times 900$).

Fig. 6 — Normal dog intercostal nerve. Cross section 8 μ , De Castro. ($\times 900$).

Fig. 7 — Distal segment of dog intercostal nerve 12 months after complete surgical transection. Cross section 8 μ , De Castro ($\times 900$).

Fig. 8 — Nerve fibres in the distal segment of dog intercostal nerve 12 months after complete surgical transection. Longitudinal section 8 μ , De Castro. ($\times 900$).

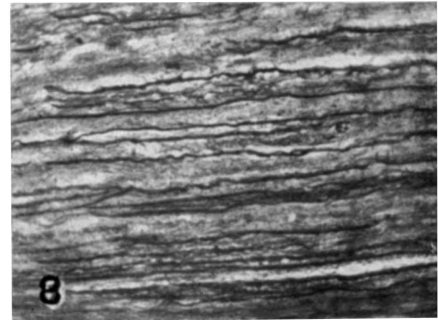
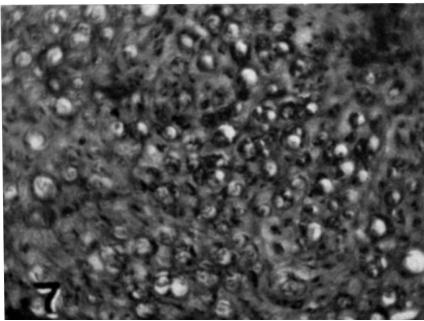
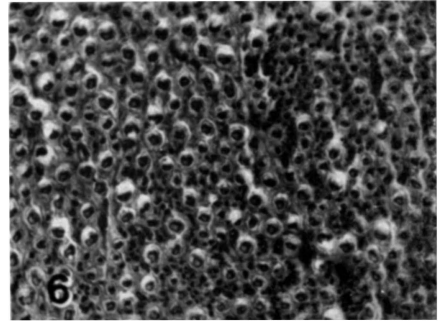
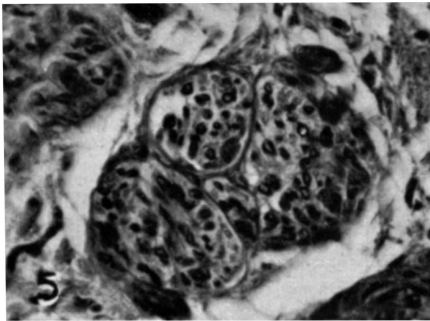
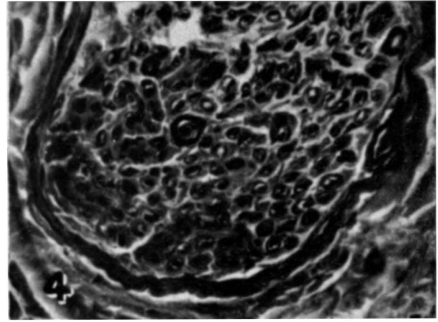
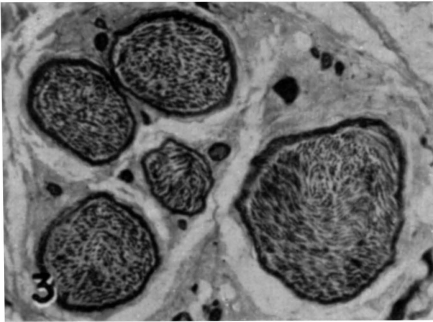

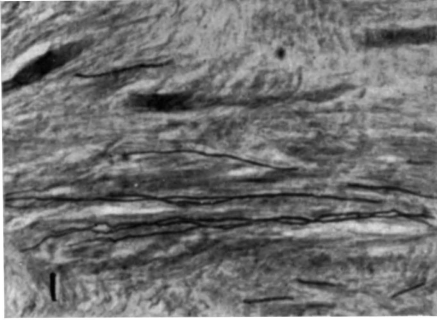


PLATE 2

Fig. 9 — Nerve fibres in the intermediate segment of dog phrenic nerve 7 months after complete proximal and distal surgical transection. Longitudinal section 8 μ , De Castro plus ferric hematoxylin to show the Schwann cells. ($\times 900$).

Fig. 10 — Intermediate segment of dog phrenic nerve 7 months after complete proximal and distal surgical transection. Cross section 8 μ , De Castro. ($\times 900$).

Fig. 11 — Neuroma-like structure of the distal end of the intermediate segment of dog phrenic nerve 7 months after complete proximal and distal surgical transection. Longitudinal section 8 μ , De Castro. ($\times 200$).

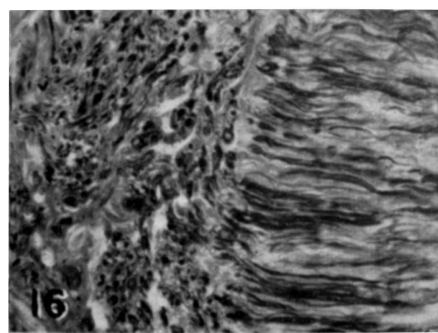

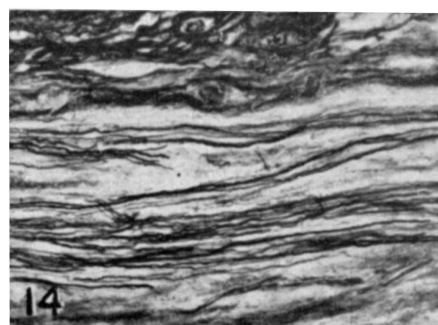
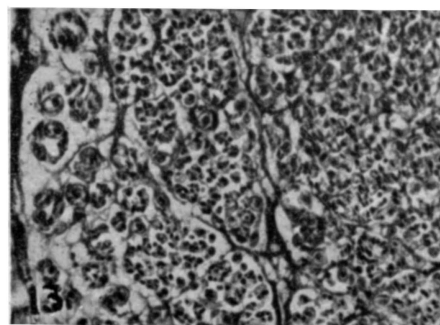
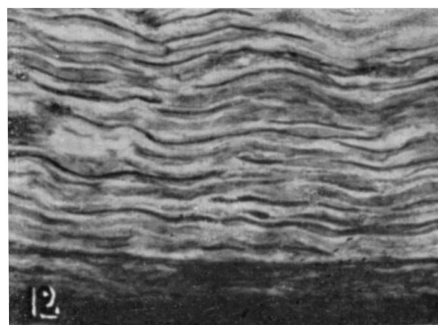
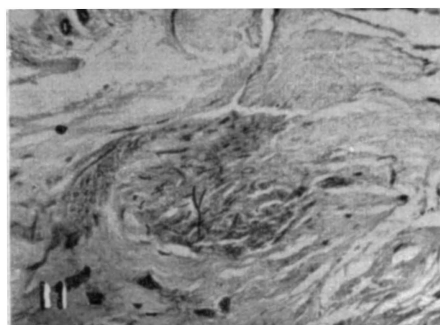
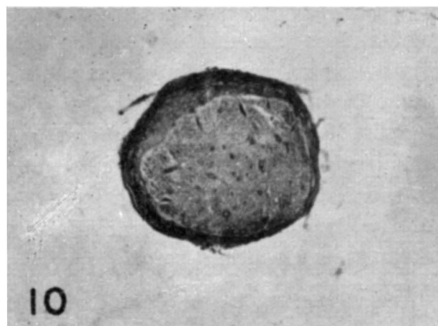
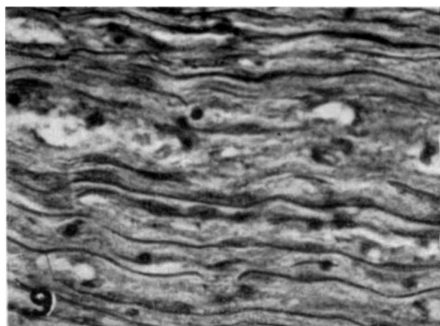
Fig. 12 — Nerve fibres in the distal segment of dog phrenic nerve 7 months after complete surgical transection. Longitudinal section 8 μ , De Castro. ($\times 900$).

Fig. 13 — Nerve fibres in the distal stump of human median nerve 12 years after complete transection. Cross section 8 μ , De Castro. ($\times 900$) (G.S. 30 years old, transection of the median nerve at the upper third of the arm).

Fig. 14 — Idem. Longitudinal section. ($\times 900$)

Fig. 15 — Nerve fibres in the distal stump of human radial nerve 24 years after complete transection. Longitudinal section 8 μ , De Castro. ($\times 900$) (A.L. 45 years old, transection of the radial nerve at the median third of the arm).

Fig. 16 — Neuroma-like structure of the distal stump of median human nerve 1.5 years after complete transection. Cross section 8 μ , De Castro. ($\times 200$) (J.B. 23 years old, transection of the median nerve at the wrist level).



The experimental cases of dog fibular nerves and human nerves, in which the reinnervation of the distal segment occurred spontaneously by ingrowing of nerve-fibres from the proximal stump are obviously excluded from the material selected for this investigation. All the studied severed nerves showed a wide gap and in the histological serial cross-sections of this region, nerve-fibres could not be found, nor were collateral sprouts in the distal stumps. For these reasons, it seems that the nerve repopulation of the distal segment occurred not by fibres from the proximal stump, but through some other way.

A degenerative process due to nerve-cells cannot be considered too, because in serial cross-sections of normal and severed dog fibular nerves, only very few nerve-cells were found. In one particular case, just four multipolar nerve-cells were found in about eight centimeters of normal fibular nerve distal to the transection level.

In the above-described experiments, we noted that while stimulating or cutting off the proximal stumps, there was never a muscular reaction, but when the distal one, completely separated from the proximal stump for six or more months and maintained in its surrounding connective bed, was stimulated, there was always an evident contraction of muscles innervated by that specific nerve.

These facts seem to exclude completely, in such cases, the possibility of reinnervation of the distal segment being done by ingrowing sprouts coming from the proximal stump.

It is really strange that the distal segment of nerves without known central connections had reacquired conducting capacity.

We have referred before to the possibility of reinnervation of the distal segment by collateral branches coming off neighbour nerves. Murray¹¹ states: "It has been thought that if a nerve is interrupted by injury or disease no recovery could take place until new fibres grew out from the central stump." "In recent years, however, it has become clear that the nervous system possesses powers additional to those normally understood by the terms "regeneration". We know now that adjacent normal fibres are stimulated to give off tiny side-branches or sprouts (Edds, 1953). The stimulus is almost certainly a humoral agent released from degenerating fibers".

Our experiments seem to invalidate this possibility of adjacent normal nerve-fibres giving off fine side branches when stimulated by some humoral agent released from degenerating fibres, because the dog fibular nerve, as far as is known, has no intercommunication with other nerves. Its own nerve fibres, sectioned and "degenerated" would not have adjacent normal nerve-fibres capable of the repopulation of the distal segment. Moreover, no difference or morphology or behavior could be observed when comparing

the distal segments of the intercostal nerves II and IX, close to I and X, with the others, chiefly IV, V and VI, theoretically the farthest from the intact nerve trunks.

With the operated phrenic nerves we were hoping to get some more information about this problem, but unfortunately the experiments done did not result in satisfactory answers, although normal nerve-fibres were histologically evident in the intermediate and distal nerve segments.

The lack of satisfactory answers, including those observed in previous experimental and human cases, may be due to some functional characteristic of the dog phrenic nerve, or to the short time (seven months) between the operation and the tests.

Therefore, the question still remains: how can one explain the re-organization or the repopulation of the distal and intermediate nerve segments found by us? Without the trophic action of the perikarion?

Hitherto we were not able to prove or to deny any action of juxta-vascular or submicroscopic nerve-fibres which could repopulate the severed nerves and adapt themselves morpho-functionally to new functions, chiefly somatic, motor and sensory.

Our observations had emphasized that at no time were any of the nerves or their segments isolated or disturbed from their surrounding connective bed, and Cajal⁴ had stated: "The segregated portion of the axon perishes and is resorbed even though it is far from the trophic center or cellular body, notwithstanding that it is protected and perhaps nourished by certain satellite cells, the cells of Schwann, and that it lives in a *milieu* of connective tissues rich in plasma and in capillaries." "In order that the nutritional process should be kept up, it is absolutely necessary that some dynamic thing, of whose nature we have no idea, should constantly be radiated from the neuronal soma so as to stimulate the protoplasm and prevent withering".

Distal nerve segments dislocated from their surrounding bed by the accident or by intentional experimental handling did not show structural integrity and nerve-fibre richness comparable to equivalent nerve segments which were kept in their connective bed. Also, they require a stronger electrical stimulus to produce muscular contraction, than those kept in their original habitat.

Richter¹³ considered the bad results of grafts due to vascular deficiencies and Weddell¹⁹ states: "Nerve bundles which are more closely related to the large blood vessels are more rapidly re-innervated than those farther away".

Concluding, we think that the surrounding bed — connective tissue rich in plasma and in capillaris, the "milieu" of Cajal — is of vital importance to maintain the nerve, as well as to allow the "regeneration" process.

With respect to the biology and histochemistry of the nerve-fibre, and to the real significance of the Schwann cell, very little is known. Would those cells act as secondary thropic centers of the mature nerve-fibre and during regenerative processes? To-date, the real functional relation between the neuron and the Schwann cell is still unknown. It could not be just a simple orientation agent to axonic sprouts (Speidel¹⁷ and Gutmann⁹). Moreover Weiss²⁰, states: "The endoneurial fluid, neither of vascular nor irritative origin, seems to have special significance in nerve regeneration, inasmuch as it forms a superior growth medium for the outgrowing sheath cells and nerve sprouts and has also antifibrotic properties." "Whether this fluid has nutrient or metabolic significance, is an open question".

Another still open question is the explanation of the neuroma-like structure found in distal and intermediate severed nerve segments. Most probably it will be understood when the origin and behavior of these distal nerve-fibres become cleared up.

More concrete data about our findings are naturally necessary, but, even so, the practical results obtained, based on our observations allows us to recommend strongly that nerve suture are worth while even after delays of many years.

Sakellarides¹⁴ suggested after a follow-up study of 172 peripheral nerve injuries in civilians, that nerve suture can be worth while even after delays of three years or more.

SUMMARY

Our experimental and histopathological findings of normal nerve-fibres in the distal and intermediate segments of nerves completely separated from the proximal stump for more than six months differs from those of previous observers, and the application of our observations in surgical reconstruction of about one hundred human nerves, chiefly from the upper limb, has resulted in appreciably great degrees of success in most cases.

RESUMO

Nossas observações experimentais e histopatológicas vêm demonstrar que as alterações estruturais que se processam em segmentos de nervos após secção completa *não são* tardiamente, de acôrdo com a opinião geral, irreversíveis e inibitórias a uma eventual regeneração.

Pelo que foi discutido e comentado, parece-nos lícito concluir que:

1 — No segmento distal de nervos completamente seccionados há mais de 6 meses e mantidos em seu leito conetivo natural, sem conexão com o segmento proximal, existem fibras e fascículos nervosos morfo-funcionalmente integros.

2 — A explicação desses achados permanece ainda no terreno das hipóteses: (a) haveria uma reorganização morfo-funcional das fibras nervosas à custa dos elementos bioquímicos constituintes das fibras “degeneradas”, possivelmente sob regência conjugada das células de Schwann, meio ambiente (leito conetivo natural do nervo) e, talvez, também de órgãos terminais, receptores e efetores; ou (b) seriam anastomoses muito delicadas, ainda não descritas, ou fibras nervosas de vasos sanguíneos que repopulariam, inclusive com ramescência recorrente, o segmento distal degenerado.

3 — Os resultados práticos obtidos em pacientes, segundo informações dos respectivos cirurgiões, vêm demonstrar que muito se poderá fazer em prol da reabilitação de inválidos, através de reconstruções e recuperação funcional de nervos com lesões antigas.

ACKNOWLEDGMENTS

Grateful acknowledgment is hereby made to: Dr. Vicente Stopigliá of the Departamento de Clínica Cirúrgica da Faculdade de Medicina Veterinária da Universidade de São Paulo, for his aid in our first animal experiments; to Dr. Joaquim Lacaz de Moraes and to Francisco Lacaz de Moraes Vieira of the Departamento de Fisiologia da Faculdade de Medicina da Universidade de São Paulo, for their part in the surgery and electroneurophysiology experiments in the later animal experiments; to the orthopedic surgeons Drs. Lauro Barros de Abreu, Edward P. Salem and Luiz G. Wertheimer for allowing us to include their observations surgical results of their clinical cases and materials therefrom as practical applications of the animal experimental conclusions; to Prof. O. Machado de Sousa and Dr. Orlando J. Aidar, for their many valuable suggestions and editing of this manuscript.

REFERENCES

1. ABERCROMBIE, M.; JOHNSON, M. L. — Quantitative histology of Wallerian degeneration; nuclear population in rabbit sciatic nerve. *Jour. Anat.*, 80:37-50, 1946.
2. BARROS DE ABREU, L.; ERHART, E. A. — Considerações sobre neurorrafias em lesões antigas. Apresentado em reunião da Assoc. Paulista de Medicina, setembro 1957. *Rev. paul. Medicina*, 52:149, 1958.
3. BOEKE, J. — Nerve Regeneration. *In Genetic Neurology*, pp. 78-91. Edit. by Paul Weiss. University of Chicago Press, 1950.
4. CAJAL, S. RAMON Y — Degeneration and regeneration of the nervous system. Translated and edit. by Raoul M. May. Oxford University Press. London, 1928.
5. EDDS, M. V. Jr. — Collateral nerve regeneration. *Quart. Rev. Biol.*, 28:260-276, 1953.
6. ERHART, E. A.; ERHART, M. B. — Normal axis-cylinders in the distal segment of nerves completely separated from the proximal stump for up to 24 years. Apresentado ao VII Congresso Internacional de Anatomia, New York, abril 1960. *Anat. Rec.*, 136:189, 1960.
7. ERHART, M. B.; ERHART, E. A. — Sobre o comportamento das fibras nervosas no côto distal de nervo fibular de *Canis familiaris* após transecção total. Apresentado à III Reunião da Soc. Bras. Anat., Pôrto Alegre, outubro 1958. *Folia Clinica et Biol.*, São Paulo, 28:98-100, 1958/59.
8. GUTH, L. — Regeneration in the mammalian peripheral nervous system. *Physiological Reviews*, 36:441-478, 1956.
9. GUTMANN, E. — Die funktionelle Regeneration der peripheren Nerven. Akademie Verlag, Berlin, 1958.
10. HOLMES, W.; YOUNG, J. Z. — Nerve regeneration after immediate and delayed suture. *Jour. Anat.*, 77:63-96, 1942.
11. MURRAY, J. G. — The consequences of injury and disease

of nervous tissue: recent advances in knowledge. J. Royal College of Surgeons of Edinburgh, 4:199-217, 1959. 12. NICHOLSON, O. R.; SEDDON, H. J. — Nerve repair in civil practice. British Medical Jour., 2:1065-1071, 1957. 13. RICHTER, G. A. — *In* Gutmann. 14. SAKELLARIDES, H. — A follow-up study of 172 peripheral nerve injuries in the upper extremity in civilians. Jour. Bone and Joint Surgery, 44: 140-148, 1962. 15. SANDERS, F. K.; YOUNG, J. Z. — The role of the peripheral stump in the control of fibre diameter in regenerating nerves. Jour. Physiol., 103: 119, 1944. 16. SEDDON, H. J. — Peripheral nerve injuries. Medical Research Council Special Report Series. No. 282. London, Her Majesty's Stationery Office, 1954. 17. SPEIDEL, C. C. — Adjustments of peripheral nerve fibres. *In* Genetic Neurology, pp. 66-77. Edit. by Paul Weiss. University of Chicago Press, 1950. 18. SUNDERLAND, S. — Regeneration phenomena in human peripheral nerves. *In* Genetic Neurology, pp. 105-127. Edit. by Paul Weiss. University of Chicago Press, 1950. 19. WEDDELL, J. — Axonal regeneration in cutaneous nerve plexuses. Jour. Anat., 77:49-62, 1942. 20. WEISS, P. — Endoneurial edema in constricted nerve. Anat. Rec., 86:491-522, 1943.

Departamento de Anatomia — Faculdade de Medicina da Universidade de São Paulo — Caixa Postal 2921 — São Paulo, Brasil.