

MALIGNIZATION OF AN ARACHNOID CYST

S. L. ROSSITTI* — R. J. BALBO**

SUMMARY — A case of evolvement of fibrosarcoma from a supratentorial arachnoid cyst (verified in surgery five years before) is presented, with brief comments on the embryonic origin of the tissues involved.

Malignização de um cisto aracnóideo.

RESUMO — Cistos aracnóideos representam displasia mesodérmica focal (do neurotélío subdural), sendo sua apresentação clínica decorrente de seu tamanho e localização. No presente caso, um fibrossarcoma originou-se de cisto aracnóideo supratentorial verificado em cirurgia cinco anos antes. A malignização de cistos aracnóideos deve ser muito rara, e esse é provavelmente o primeiro caso relatado na literatura.

Cancer has been occasionally reported to evolve from congenital malformations. In the present case, a fibrosarcoma arised from an arachnoid cyst of the right sylvian fissure verified in surgery five years before.

CASE REPORT

ACF, a 1-year-old caucasian male, admitted to the Neurosurgical Clinic four days after a head injury of moderate intensity (he fell from his bed). Since this accident he refused to eat, had frequent vomits, and slept most of the time. On examination he presented with drowsiness, asymmetric macrocephaly and bilateral choked disks. There was no motor paralysis, reflex asymmetry or pathological reflexes. The enlargement of his head was progressive since birth. He was not well fed, and presented a delayed psychomotor development. Cranial roentgenogram showed a linear parietoccipital skull fracture, enlargement of the right temporal fossa and disjunction of sutures. Pneumoencephalogram and right carotid angiogram showed a frontotemporal avascular mass lesion. A large frontotemporal craniotomy was performed and revealed a cystic lesion (Fig. 1) which splayed the frontal and temporal operculae, exposing the island of Reil. The cyst was filled with about 100 ml of clear, slightly xanthochromic fluid, which was drained. The outer cystic wall was resected and its cavity communicated with the right lateral ventricle by means of two small plastic tubes. Microscopic examination of the cyst wall revealed a delicate fibrovascular membrane with an internal lining of flattened cells, and sparse nests of meningothelial cells. The diagnosis was symptomatic (hypertensive) arachnoid cyst, of developmental origin.

He made a slow recovery, with gradual cessation of pressure symptoms, and was discharged after 4 weeks. A pneumoencephalogram performed 6 months later showed a communicating cystic cavity with no mass effect. With exception of a persistent macrocephaly, and one episode of measles meningitis, he remained free from symptoms for 5

Trabalho do Departamento de Neuro-Psiquiatria da Faculdade de Ciências Médicas da Pontifícia Universidade Católica de Campinas (PUCAMP) e do Departamento de Neurologia e Neurocirurgia do Hospital Vera Cruz e Hospital Municipal Dr. Mario Gatti, Campinas:
* Médico Residente; ** Professor Adjunto.

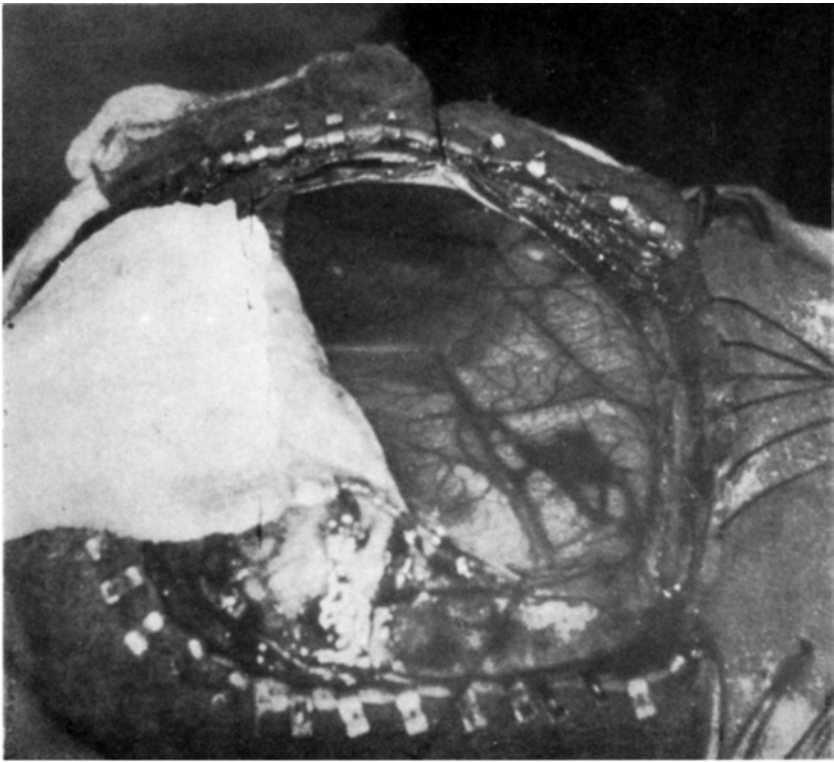


Fig. 1 — Case ACF. Arachnoid cyst of the right sylvian fissure as revealed in surgery.

years, when he was readmitted with bacterial meningitis. He received antibiotic therapy and was discharged asymptomatic.

He returned 6 months later presenting marked drowsiness, vomits and gait instability of two weeks duration. On examination he presented left hemiparesis and bilateral choked disks. Right carotid angiogram demonstrated an avascular frontotemporal mass lesion, with subfacial herniation to the left. A right frontotemporal craniotomy disclosed multiple pearly white tissue masses adherent to the cyst wall, with areas of pulpy consistency easily aspirable; the remnant of the cystic cavity was filled with about 60 ml of viscous, brown fluid, which coagulated after drainage. Tumor biopsy was performed. Microscopic examination proved the lesion to be a fibrosarcoma, grade III (Fig. 2). A computerized tomographic scan was performed (Fig. 3), and the patient was reoperated. A radical excision of the tumour was attempted, exposing normal cortex beneath it. The immediate post-operative recovery was uneventful, the patient being conscious and with slight left hemiparesis in the day following the second operation. He died two months later of bronchopneumonia, not having initiated radiotherapy. No extracranial metastasis was suspected on clinical ground. Necropsy was not permitted by the family.

COMMENTS

The arachnoid is the last of the meninges to differentiate, developing from the inner aspect of the duramaetr. It is of mesodermal origin, avascular, composed of both collagen and modified fibroblasts (arachnoid cells)⁵. Arachnoid cysts represent a focal reduplication of the normal arachnoid membrane originating a fluid-containing space within the subarachnoid space^{5,8}. Except when localized in the cerebral convexity, they are associated with a normal subarachnoid cistern⁸. Ultrastructural studies

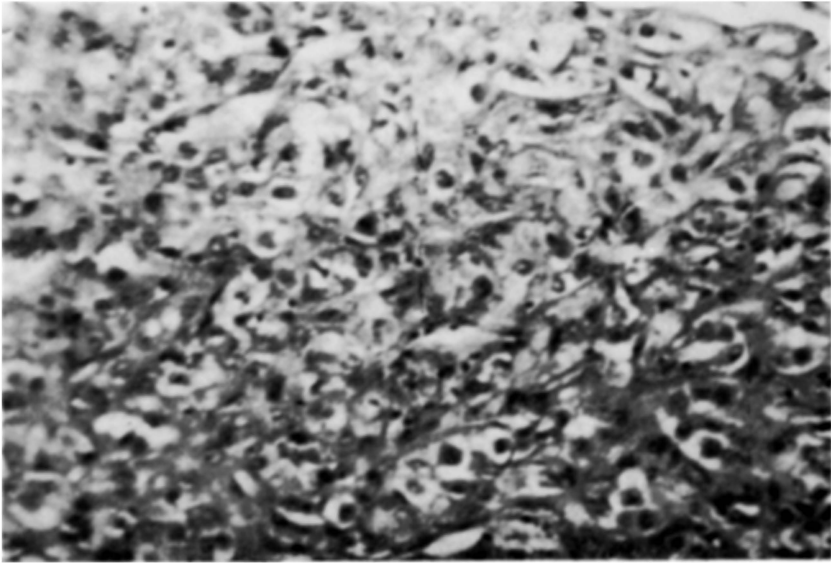


Fig. 2 — Case ACF. Fibrosarcoma, grade III. Densely cellular neoplasia composed of little collagen and closely packed elongated cells, with voluminous hyperchromatic nuclei, and sparse atypical mitoses; extensive necrotic areas are present, with hemorrhagic suffusion (HE, X400).

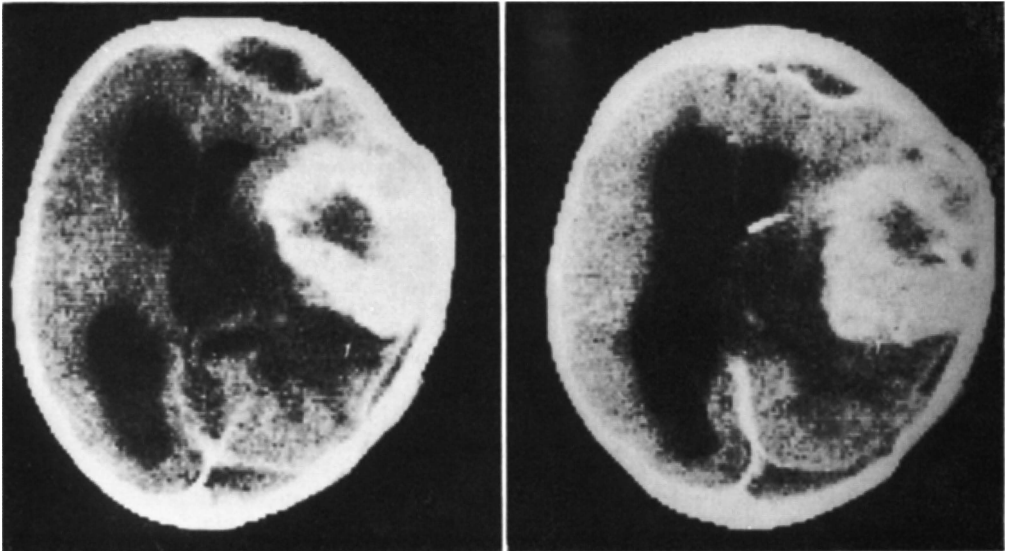


Fig. 3 — Case ACF. Contrast-enhanced CT scan. Large right frontotemporal mass with irregular hypodense areas, and shift of the supratentorial ventricles to the left.

suggest that they are derived from the outer arachnoid cell layer (subdural neurothelium), their formation and gradual enlargement being attributable to secretory capacity of the subdural neurothelium³.

The clinical presentation of arachnoid cysts is usually related to their size. Small cysts are found incidentally in autopsy or CT scans; larger ones behave as space-occupying lesions. In some cases progressive symptoms arise in consequence of head trauma. In recent years, technology has provided an optimization in the diagnosis of intracranial arachnoid cysts. Several observations have pointed to the association with genetic disorders of the mesodermal tissues (Marfan syndrome^{9,10}, neurofibromatosis¹¹, and autosomal-dominant polycystic kidney disease¹), suggesting a common pathogenesis. The incidental finding of an arachnoid cyst in patients with primary intracranial neoplasms (meningioma⁶ and pituitary adenoma⁷) has also motivated some communications.

Fibrosarcomas are common to all organs. In the central nervous system they may arise from preexisting fibroblasts or undifferentiated mesenchymal cells in the duramater, leptomeninges and perivascular connective tissue⁴. Occasionally, fibrosarcomas have followed radiation therapy. Teratogenesis and carcinogenesis are both related to reproductive capacity of somatic cells, and neoplasms have been reported to evolve from congenital malformations². The evolvement of malignancy from an arachnoid cyst must be very rare. This is probably the first case reported in literature.

REFERENCES

1. Allen A, Wiegman TB, MacDougall ML — Arachnoid cyst in a patient with autosomal-dominant polycystic kidney disease. *Am J Kidney Dis* 8:128, 1986.
2. DiPaolo JA, Kotin P — Teratogenesis-oncogenesis: a study of possible relationships. *Arch Pathol* 81:3, 1966.
3. Go KG, Houthoff HJ, Blaauw EH, Stokroos I, Blaauw G — Morphology and origin of arachnoid cysts: scanning and electron microscopy of three cases. *Acta Neuropathol (Berlin)* 44:57, 1978.
4. Kernohan JW, Uihlein A — Sarcomas of the Brain. Charles C. Thomas, Springfield, 1962, pg 30.
5. Lemire RJ, Loeser JD, Leech RW, Alvord EC Jr — Normal and Abnormal Development of the Human Nervous System. Harper & Row, Hagerstown, 1975, pg 280.
6. Lepuschütz H, Sager WD, Schröttner O — Doppelmeningeome mit Arachnoidalzyste: eine seltene Kombination. *Computertomographie (Stuttgart)* 1:33, 1981.
7. Rahimizadeh A, Kaghazchi M, Haddadian K — Coincidence of an arachnoid cyst of the middle fossa and a pituitary adenoma. *Neurosurgery* 21:261, 1987.
8. Rengachary SS, Watanabe I — Ultrastructure and pathogenesis of intracranial arachnoid cysts. *J Neuropath Exp Neurol* 40:61, 1981.
9. Robinsor RG — The temporal lobe agenesis syndrome. *Brain* 87:87, 1964.
10. Weir B — Leptomeningeal cysts in congenital ectopia lentis. *J Neurosurg* 38:650, 1973.
11. Yoshioka H, Ino S, Ishimura K, Fujiwara K, Morioka Y, Terada N, Sawada T, Kusunoki T, Koyama T — An arachnoid cyst in a 8-year-old boy with neurofibromatosis. *Brain Dev* 6:551, 1984.