

# SEP DIAGNOSING NEUROPATHY OF THE LATERAL CUTANEOUS BRANCH OF THE ILIOHYPOGASTRIC NERVE

## Case report

Rafael José Soares Dias<sup>1</sup>, Lancaster de Souza<sup>1</sup>,  
Wanderley Freitas de Moraes<sup>1</sup>, Armando Pereira Carneiro<sup>2</sup>

**ABSTRACT** - The article pertains to the uncommon clinical case of a patient with a proximal neuropathy of the lower extremity. It outlines the electrophysiological evaluation and reviews the medical literature. The electrophysiologic test that most accurately revealed the neuropathy was the segmental somatosensory evoked potential (SEP) of the lateral cutaneous branch of the iliohypogastric nerve. It showed well-defined and replicable cortical waveforms following the excitation of the lateral cutaneous branch of the iliohypogastric nerve in the asymptomatic lower extremity, but failed to present somatosensory evoked potentials arising from the excitation of the contralateral nerve in the symptomatic lower extremity. We did not find any previous reports diagnosing that particular pathology by the use of segmental SEP. In conclusion, it is important to remember that the accurate diagnosis of patients complaining of pain and dysesthesia in the proximal part of the lower extremities can possibly be achieved through the use of electrophysiologic tests such as the segmental SEP.

**KEY WORDS:** neuropathy, nerve injury, nerve entrapment, iliohypogastric nerve, somatosensory evoked potential.

### **Neuropatia do ramo cutâneo lateral do nervo ílio-hipogástrico diagnosticada por PES: relato de caso**

**RESUMO** - O presente artigo relata caso clínico incomum de neuropatia proximal de membro inferior, demonstra eletrofisiologicamente o comprometimento neural e revisa a literatura médica sobre o assunto. O teste neurofisiológico que demonstrou a patologia foi o potencial evocado somato-sensitivo (PES) segmentar do ramo cutâneo lateral do nervo ílio-hipogástrico. Ele revelou potenciais corticais bem definidos e replicáveis à estimulação do membro inferior assintomático, mas falhou em produzir respostas corticais do membro inferior sintomático. Na revisão da literatura não foi encontrado nenhum relato anterior de diagnóstico dessa patologia por PES segmentar. Conclui-se que é importante ter em mente ao avaliar pacientes com queixas de dor e disestesia na base dos membros inferiores que o acometimento de pequenos ramos cutâneos, como o cutâneo lateral do ílio-hipogástrico, pode ter confirmação eletrofisiológica da patologia por testes neurofisiológicos como o potencial evocado somato-sensitivo segmentar.

**PALAVRAS-CHAVE:** neuropatia, nervo ílio-hipogástrico, potencial evocado somato-sensitivo.

Proximal neuropathies of the lower extremities, with the exception of the lateral femoral cutaneous neuropathy, are uncommon causes of pain and paresthesia<sup>1</sup>. As such, these pathologies can often present a diagnostic challenge for the physician. There are several proximal neural branches of the lower extremities that can suffer nerve entrapment: the cluneal, the lateral cutaneous branch of the iliohypogastric and the subcostal<sup>2,3</sup>.

This paper references one specific neuropathy that affects the lateral cutaneous branch of the iliohypogastric nerve, as revealed by the segmental somatosensory evoked potential (SEP).

*Review of anatomy* - The iliohypogastric nerve is the highest branch of L1 and receives fibers from T12. It passes through the psoas, extending diagonally along the anterior surface of the quadra-

Unit of Graphic Registers, Area of Clinical Neurophysiology, Márcio Cunha Hospital, Ipatinga MG, Brazil: <sup>1</sup>MD, Márcio Cunha Hospital, <sup>2</sup>MD Arapiara Hospital.

Received 29 September 2003, received in final form 1 April 2004. Accepted 25 May 2004.

Dr. Rafael José Soares Dias - Rua Francisco Sales 96 - 35010-110 Governador Valadares MG - Brasil. E-mail: rafadias.bh@terra.com.br

tus lumborum. From there, it continues through the transverses abdominis, extending between the transverses and the internal oblique and continuing medially deep into the aponeurosis of the internal oblique at the level of the anterosuperior iliac crest. Then the nerve divides into its anterior and lateral cutaneous branches. The anterior branch extends horizontally below the aponeurosis of the external oblique and becomes cutaneous in the anterior abdominal wall. The lateral cutaneous branch becomes superficial close to the iliac crest, where it creates a bony groove located 7 to 11 cm from the anterosuperior iliac spine. This groove is transformed into an osseo-membranous tunnel by the aponeurosis of the oblique muscle<sup>4-9</sup>.

### CASE

A 20-year-old woman was examined in the Unit of Graphic Registers (area of clinical neurophysiology) of Márcio Cunha Hospital. She has described pain and hypoesthesia in the proximal lateral face of the right thigh for 4 years, but the symptoms have increased as of late.

The patient's past medical history did not reveal any trauma, sickness, and use of drugs or contact with toxic substances that could have cause neuropathies. Hansen's disease, a common illness in this country, was investigated by physical examination and skin biopsy at the public department of infect-contagious diseases, and the outcome was negative. Physical examination - Weight: 47 kg, Height: 156 cm. Positive findings: hypoesthesia (decreased sensation to light touch and pinprick) in the lateral aspect of the proximal segment of the right thigh, and a painful point over the iliac crest approximately 8 cm off the anterior-superior iliac spine. Negative findings: absence of local alterations on the skin, normal sensitivity in the groin, normal muscle stretch reflex and normal muscle strength.

Many test were performed, including: thigh, abdomen and wall abdominal ultrasound; plain X-ray of the right hip and lumbosacral spine, and computed tomography of the lower thoracic and upper lumbar spine. These exams did not show any abnormality.

An orthopedist and a pain-clinic specialist evaluated the case and were left to decide the best treatment for the patient. They chose 6 neural blockades with a

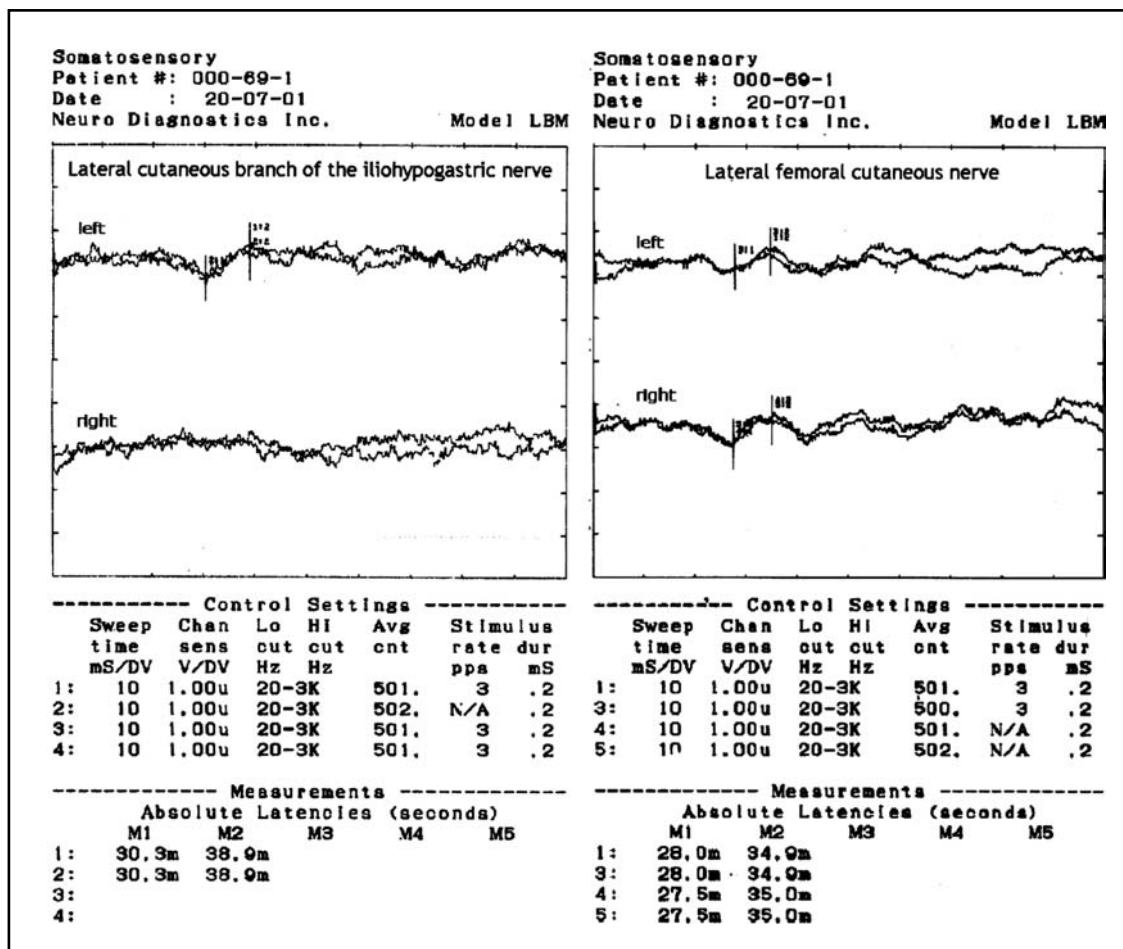


Fig 1. SEP waveforms and instrument parameters.

local anaesthetic (lidocaine 2%) in addition to the removal of physical pressure on the iliac crest (via underclothes) as a treatment. After 45 days, the patient was relieved of symptoms and the hypoesthesia area was decreased.

**Neurophysiological evaluation** - The neurophysiological assessment of this case included nerve conduction studies, needle electromyography and segmental SEP. An LBM electromyography machine (Neurodiagnostics Inc., USA) was used for all tests. The instrument parameters of the segmental SEP are in Figure 1.

These neural conduction studies analyzed sensory nerves (right sural and both superficial peroneal) as well as motor nerves (tibial and peroneal). Needle electromyography was performed in the proximal muscles of the lower extremity (iliopsoas, vastus medialis, gluteus medius), the paraspinal muscles (T12/L1), and the abdominal wall muscles (obliquus int abdominis) using a disposable monopolar needle. These tests resulted in no defined diagnosis.

Segmental SEP was then performed by electrical stimulation via bar electrode of the skin regions associated with the lateral cutaneous branch of the iliohypogastric nerve. It was positioned 8.5 cm distal to the iliac crest, at a distance of 9.5 cm from the superior-anterior iliac spine (Fig 2). The stimulus intensity used was 3.5 times the sensory threshold of the asymptomatic side. Segmental SEP of the lateral femoral cutaneous was performed too. The recording scalp needle electrodes were placed 2 cm posterior to the International 10-20 Cz and Fpz electrode locations. The exam revealed well-defined cortical waveforms following excitation of all sensory nerves, except the one arising from the lateral cutaneous branch of the right iliohypogastric nerve (symptomatic side). It did not show any cortical response (Fig 1).

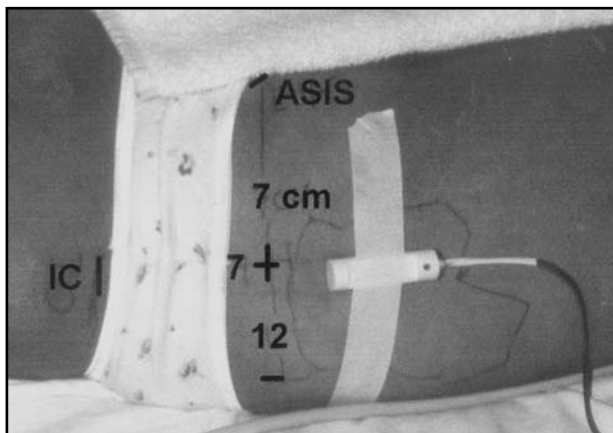


Fig 2. Segmental SEP of the lateral cutaneous branch of the iliohypogastric nerve. Stimulation electrode placement on the hypoesthesia area. IC: iliac crest. ASIS: anterior-superior iliac spine.

The corresponding neurophysiologic evaluation revealed an injury to the iliohypogastric nerve, located distally to the motor branches of the abdominal wall muscles. The possibility of central sensory conduction disorder was ruled out because the segmental SEP of the lateral femoral cutaneous nerve showed normal waveforms at the same side of the affected nerve.

## DISCUSSION

In modern medical literature, it is common to experience cases of iliohypogastric neuropathy (IHN) after performing specific surgical procedures like abdominoplasty, and herniorrhaphy<sup>10-12</sup>. These diagnoses were commonly found by the use of neurochemical blocks or by performing surgery to relieve the symptoms<sup>13, 14</sup>. In one report, however, IHN was diagnosed using neurophysiologic assessment<sup>15</sup>. It employed needle electromyography of the abdominal muscles to identify the injured nerves. This method, however, revealed an important limitation of such testing, since only motor fibers were analyzed, thereby reducing the test's sensitivity. As a result, a complete neurophysiological evaluation with conduction tests (specifically segmental SEP) and needle electromyography has been determined to provide a much better chance of diagnosing IHN. In fact, in the aforementioned case, segmental SEP was utilized to analyze the iliohypogastric sensory nerve fibers and it provided the crucial monitoring needed to accurately diagnose the neuropathy. Segmental SEP testing was able to evaluate sensory nerve fibers as opposed to electromyography, which could only analyze motor nerve fibers.

Results of anatomic dissection show morphological changes of the lateral cutaneous branch of the iliohypogastric nerve at the point where it crosses the iliac crest inside the osseo-membranous tunnel<sup>7</sup>. This neuropathy was labeled in others articles as "perforates syndrome"<sup>3</sup> and "pseudotrochanteric bursitis"<sup>16</sup>. This neuropathy was apparently caused by the wearing of tight underclothes that compressed the osseomembranous tunnel over the iliac crest, thereby damaging the lateral cutaneous branch of the iliohypogastric nerve.

Proximal neuropathies are difficult to assess through the use of electroneurological tests due to the inherent difficulty of the electroneurography to study proximal nerves. This is due primarily to the anatomy of the nerve becoming superficial at its very thin-ending neural branches and consequent inability of most electroneurological tests to accurately analyze them.

In conclusion, it is important to consider using alternative electrophysiological testing for patients with pain and dysesthesia in the proximal region of the lower extremities. As showed-in this study, the segmental SEP test, in addition to a conventional electrophysiological assessment, may be especially helpful in the neurological assessment of the small sensory cutaneous branches like the iliohypogastric nerve, as many other electrophysiological tests have proven inadequate in such cases.

**Acknowledgement** - The authors wish to thank Mr. Charles W. Smith III for the manuscript revision.

## REFERENCES

1. Reid V, Cros D. Proximal sensory neuropathies of the leg. *Neurol Clin* 1999;17:655-667.
2. Maigne JY, Doursounian L. Entrapment neuropathy of the medial superior cluneal nerve. *Spine* 1997;22:1156-1159.
3. Touzard RC, Maigne JY, Maigne R, Doursounian L. Douleur de la région trochanterienne par striction canalaire de la brenche perforante latérale cutaneé du nerf iliohypogastrique. *Chirurgie* 1989;115:287-291.
4. Papadopoulos NJ, Katritsis ED. Some observations on the course and relations of the iliohypogastric and ilioinguinal nerves (based on 348 specimens). *Anat Anz* 1981;149:357-364.
5. Mandelkow H, Loeweneck H. The iliohypogastric and ilioinguinal nerves: distribution in the abdominal wall, danger areas in surgical incisions in the inguinal and pubic regions and reflected visceral pain in their dermatomes. *Surg Radiol Anat* 1988;10:145-149.
6. Maigne JY, Lazareth JP, Maigne R. Étude anatomique de l'innervation cutaneé lombo-sacrée. *Rev Rhumat* 1988;55:107-111.
7. Maigne JY, Maigne R, Guérin-Surville H. Anatomic study of the lateral cutaneous rami of the subcostal and iliohypogastric nerves. *Surg Radiol Anat* 1986;8:251-256.
8. Maigne JY, Lazareth JP, Maigne R, Guérin-Surville H. The lateral cutaneous branches of the dorsal rami of the thoraco-lumbar junction. *Surg Radiol Anat* 1989;11:289-293.
9. Netter FH. Atlas de anatomia humana. Trad. Jaques Vissoky. Porto Alegre:Artes Médicas,1996.
10. Melville K, Schultz EA, Dougherty JM. Ilioinguinal-iliohypogastric nerve entrapment. *Ann Emerg Med* 1990;19:925-929.
11. Liszka TG, Dellon AL, Manson PN. Iliohypogastric nerve entrapment following abdominoplasty. *Plast Reconstr Surg* 1994;93:181-184.
12. Cunningham J, Temple WJ, Mitchell P, et al. Cooperative hernia study: pain in the postrepair patient. *An Surg* 1996;224:598-602.
13. Carter BL, Racz GB. Iliohypogastric nerve entrapment in pregnancy: diagnosis and treatment. *Anesth Analg* 1994;79:1193-1194.
14. Ziprin P, Williams P, Foster ME. External oblique aponeurosis nerve entrapment as a cause of groin pain in the athlete. *Br J Surg* 1999;86:566-568.
15. Knockaert DC, Boonen AL, Bruyninckx FL, Bobbaers HJ. Electromyographic findings in ilioinguinal-iliohypogastric nerve entrapment syndrome. *Acta Cl Bel* 1996;51:156-160.
16. Traycoff RB. "Pseudotrochanteric bursitis": the differential diagnosis of lateral hip pain. *J Rheum* 1991;18:1810-1812.