

Plasmacytoma of head and neck as initial presentation of multiple myeloma

Rodrigo Jorge de Oliveira¹, Fabiano Reis¹, Atul Kumar Taneja¹, Luciano de Souza Queiroz², Verônica de Araújo Zanardi¹

45-year-old female with headache and facial tumor growing since 16 months ago. Diagnostic imaging demonstrated a large lesion on the right greater sphenoid wing, extending into the masticator space, nasopharynx, nasal cavity, clivus, sphenoid and maxillary sinuses, and to the anterior and middle cranial fossae.

Histological analysis confirmed the

diagnosis of plasmacytoma and later the bone marrow biopsy diagnosed multiple myeloma.

Multiple myeloma compromising the skull base is difficult to diagnose, specially when its onset is a head and neck plasmacytoma, which is uncommon and overlaps other head and neck tumoral conditions that also present as large extra-axial masses.

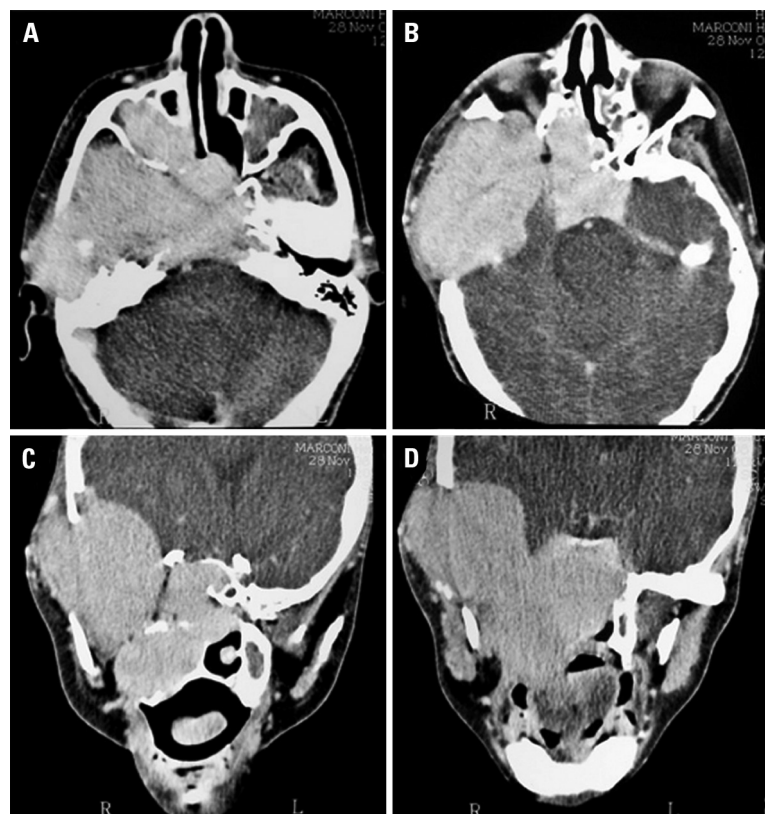


Fig 1. CT: [A and B] Contrast-enhanced axial, [C and D] Contrast-enhanced coronal. On CT, the lesion presented attenuation similar to soft tissues, with intense and heterogeneous enhancing after contrast.

Correspondence

Fabiano Reis
Faculdade de Ciências Médicas
Universidade Estadual de Campinas
Departamento de Radiologia
Rua Tessália Vieira de Camargo 126
13083-887 Caixa Postal 6111
Campinas SP - Brasil
E-mail: fabianoreis2@gmail.com

Received 20 July 2010
Received in final form 9 August 2010
Accepted 16 August 2010

PLASMOCITOMA DA CABEÇA E PESCOÇO COMO APRESENTAÇÃO INICIAL DE MIELOMA MÚLTIPLO

¹Department of Radiology of the Clinics Hospital of the State University of Campinas, Faculty of Medical Sciences, Campinas SP, Brazil; ²Department of Pathology of the Clinics Hospital of the State University of Campinas, Faculty of Medical Sciences, Campinas SP, Brazil.

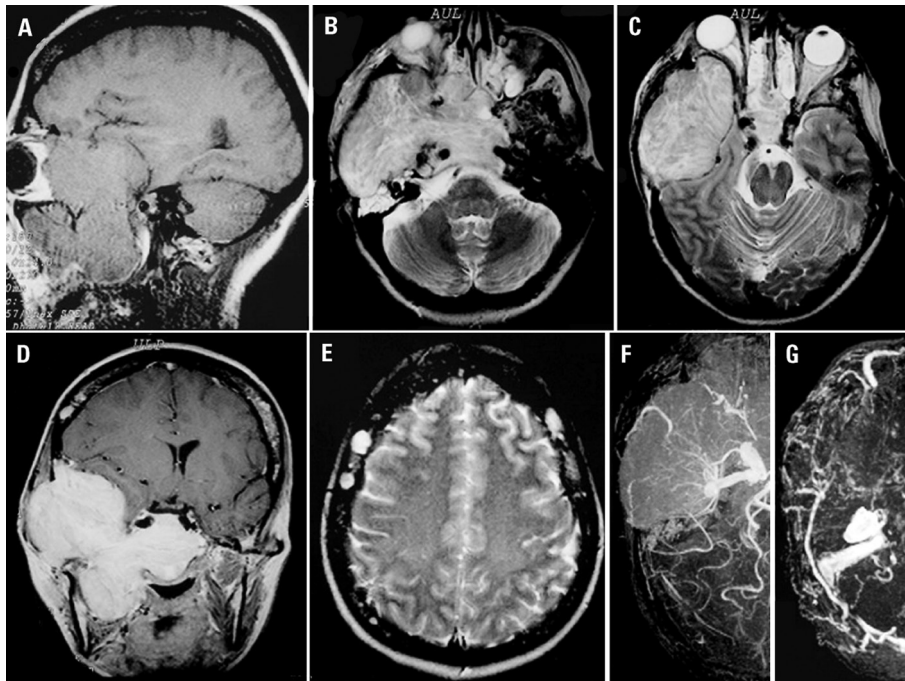


Fig 2. MR: [A] Sagittal T1W, [B and C] Axial T2W, [D] Contrast-enhanced Coronal T1W, [E] Axial T2W, [F] Arterial MR Angiography and [G] Venous MR Angiography. Isointensity was noted on T1-weighted images, hyperintensity on T2-weighted and FLAIR images, intralesional flow-voids and strong contrast enhancement. There was bone remodeling and compression of adjacent structures. Lytic bone lesions with no definite margins were seen in the masticator spaces. Other contrast-enhancing nodular intradiploic lesions were also seen. Digital subtraction angiography demonstrated the right external carotid artery as the major nutrient vessel of the mass.

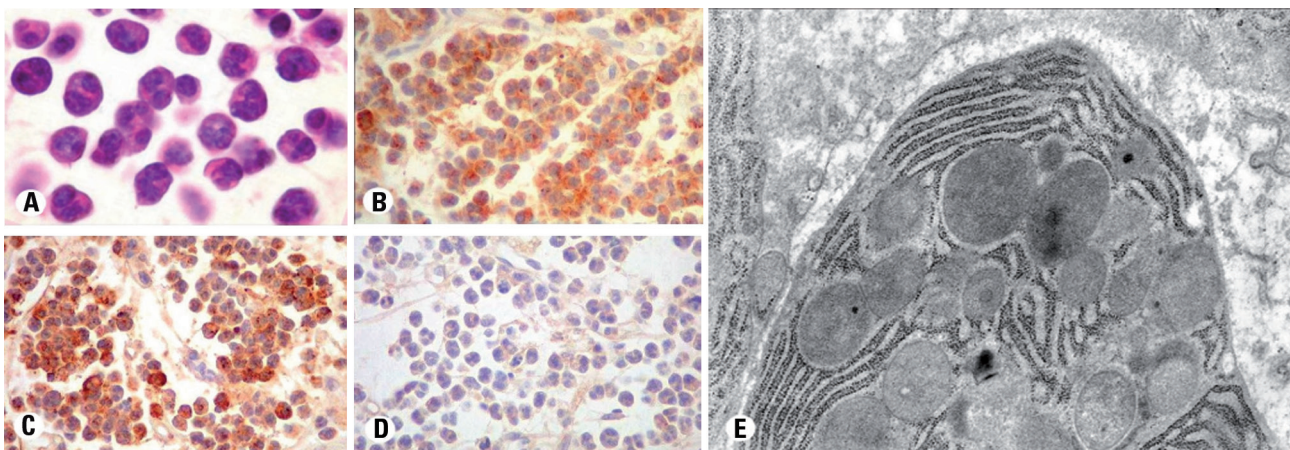


Fig 3. [A] Histological analysis of hematoxylin-eosin stained sections revealed the tumor to be composed of plasma cells with strong basophilic cytoplasm, eccentric nuclei and cartwheel chromatin, in a loose capillary-rich stroma. A large proportion of cells contained two to four nuclei. Mitotic figures were very rare and necrosis was not seen. [B, C and D] Immunohistochemistry showed exclusive expression of kappa chains, while lambda chains were thoroughly negative. Many cells were positive for CD138, a reliable marker of plasma cells. [E] On electron microscopy most cells contained abundant cisterns of rough endoplasmic reticulum, often in parallel arrays along the cell periphery. Macrophages in the process of phagocytosis of apoptotic tumor cells were plentiful.

REFERENCES

1. Lin C, Luciani A, Belhadj K, et al. Patients with plasma cell disorders examined at whole-body dynamic contrast-enhanced magnetic resonance imaging. *Radiology* 2009;250:905-915.
2. Cerase A, Tarantino A, Gozzetti A, et al. Intracranial involvement in plasmacytomas and multiple myeloma: a pictorial essay. *Neuroradiology* 2008;50:665-674.
3. Angtuaco JC, Fassas ABT, Walker R, Sethi R, Barlogie B. Multiple myeloma: clinical review and diagnostic imaging. *Radiology* 2004;231:11-23.
4. Provenzale JM, Schaefer P, Traweek ST, et al. Craniocerebral plasmacytoma: MR features. *AJNR Am J Neuroradiol* 1997;18:389-392.