

# Multiparametric multidetector computed tomography scanning on suspicion of hyperacute ischemic stroke: validating a standardized protocol

Avaliação multiparamétrica por tomografia computadorizada multidetectores na suspeita de isquemia cerebral hiperaguda: validando um protocolo padronizado

Felipe Torres Pacheco<sup>1</sup>, Antônio José da Rocha<sup>1</sup>, Ingrid Aguiar Littig<sup>1</sup>, Antonio Carlos Martins Maia Júnior<sup>1</sup>, Rubens José Gagliardi<sup>2</sup>

## ABSTRACT

Multidetector computed tomography (MDCT) scanning has enabled the early diagnosis of hyperacute brain ischemia. We aimed at validating a standardized protocol to read and report MDCT techniques in a series of adult patients. The inter-observer agreement among the trained examiners was tested, and their results were compared with a standard reading. No false positives were observed, and an almost perfect agreement ( $Kappa > 0.81$ ) was documented when the CT angiography (CTA) and cerebral perfusion CT (CPCT) map data were added to the noncontrast CT (NCCT) analysis. The inter-observer agreement was higher for highly trained readers, corroborating the need for specific training to interpret these modern techniques. The authors recommend adding CTA and CPCT to the NCCT analysis in order to clarify the global analysis of structural and hemodynamic brain abnormalities. Our structured report is suitable as a script for the reproducible analysis of the MDCT of patients on suspicion of ischemic stroke.

**Key words:** tomography, perfusion, angiography, stroke, cerebral infarction.

## RESUMO

A tomografia computadorizada multidetectores (TCMD) permitiu o diagnóstico precoce de isquemia cerebral hiperaguda. O presente estudo objetivou validar a interpretação e a descrição padronizada de um protocolo de TCMD multiparamétrica em uma série de pacientes adultos. A concordância entre os examinadores foi testada, e seus resultados confrontados com uma leitura padrão. Não foram observados resultados falso-positivos, e foi documentado um elevado grau de concordância ( $Kappa > 0,81$ ) quando os dados da angiotomografia (ATC) e dos mapas de perfusão cerebral por TC (PCTC) foram adicionados à análise da TC sem contraste (TCSC). A concordância interobservador foi superior para os leitores melhor treinados, corroborando a necessidade de formação específica para a interpretação dos exames. Os autores recomendam acrescentar a interpretação da ATC e da PCTC à análise da TCSC, visando à análise global das anormalidades cerebrais estruturais e hemodinâmicas. O presente protocolo é adequado como um roteiro reproduzível para a análise da TCMD de pacientes com suspeita de acidente vascular cerebral isquêmico.

**Palavras-Chave:** tomografia, perfusão, angiografia, acidente vascular cerebral, infarto cerebral.

Within the last few years, brain imaging has revolutionized the approach for patients with acute ischemic stroke, confidently differentiating hemorrhagic from ischemic stroke, depicting the extent of early parenchymal effects and most recently defining the parameters to guide thrombolytic therapy<sup>1</sup>.

Magnetic resonance imaging (MRI) protocols are reliable for the detection of early cytotoxic brain edema, mismatch areas, and arterial flow abnormalities<sup>2</sup>. However, the acquisition is not as feasible in the daily routine due to the required time and inherent limitations of the procedure. Noncontrast computed tomography (NCCT) has become a useful tool in

<sup>1</sup>Division of Neuroradiology, Santa Casa de Misericórdia de São Paulo, São Paulo SP, Brazil;

<sup>2</sup>Division of Neurology, Santa Casa de Misericórdia de São Paulo, São Paulo SP, Brazil.

**Correspondence:** Antonio Jose da Rocha; Rua Doutor Cesário Motta Junior 112; 01221-020 São Paulo SP - Brasil; E-mail: a.rocha@uol.com.br

**Conflict of interest:** There is no conflict of interest to declare.

Received 10 November 2012; Received in final form 22 November 2012; Accepted 29 November 2012.

the evaluation of acute stroke due to its wide availability, fast acquisition, and high accuracy for ruling out intracranial hemorrhage<sup>3-5</sup>. More recently, multidetector CT (MDCT) scanning has enabled the development of advanced techniques, including CT angiography (CTA) and cerebral perfusion computed tomography (CPCT)<sup>6-9</sup>.

Although patient selection could be based primarily on NCCT<sup>10</sup>, recent reports have been gathering evidence about the safe use of multiparametric MDCT to include patients for either intravenous or intra-arterial thrombolysis from early or later ictus in different protocols<sup>11-13</sup>.

In order to determine which patients would most benefit with the available protocols for thrombolytic therapies, some objective queries must be effectively understood in an emergency setting<sup>8,14</sup>:

- Could the imaging results indicate something other than ischemia?
- Is there intracranial hemorrhage?
- Is there a parenchymal abnormality? What is its extent?
- Is there a mismatch area in the brain perfusion?
- Is there a large vessel obstruction?

A comprehensive training program must comprise the theoretical basis of stroke, and include a practical scenario to enable specialists to solve these inquiries. The sequential steps to read and report multiparametric MDCT in hyperacute brain ischemia are the focus of this study.

## METHODS

This is part of a larger study using MDCT techniques to evaluate hyperacute stroke. The protocol has been reviewed and approved by the Institutional Review Board and the local ethics committee. A cohort of individuals with previously known outcomes was selected to include a range of imaging findings in the scenario of hyperacute brain ischemia. Multiparametric MDCT examinations from the digital archives of the Radiology Division of Santa Casa de Misericórdia de São Paulo were analyzed, with the aim of testing the reproducibility of a standardized protocol for their analysis and description.

Adult patients ( $\geq 18$  years-old) with hyperacute symptoms ( $< 6$  hours) suspected of focal acute ischemia in the middle cerebral arteries (MCA) and who had been submitted to multiparametric brain MDCT were considered eligible. The informed consent was signed personally by all subjects or their guardians. We excluded patients with contraindications to ionizing radiation exposure or to the intravenous iodine contrast agent, those who refused to participate in the study, and those whose examinations included images with inadequate quality or technical artifacts.

All exams were conducted using a previously defined imaging acquisition protocol with a minimum dose of both ionizing

radiation and intravenous iodinated contrast in a 64-slice CT scanner (Brilliance CT 64 Channel, Philips Medical, Eindhoven, The Netherlands), including NCCT, CPCT maps, and CTA, which could take up to seven minutes.

In all cases, a dual-head power injector (Medrad, Warrendale, USA) with an 18-G i.v. access, usually located in the cubital vein, was used for injection. Brain perfusion was performed after the administration of 50 mL of a nonionic contrast agent at an injection rate from 4 to 5 mL/s. After 5 seconds from the start of contrast injection, continuous images in the region of interest were acquired (120 kV, 80 mA, rotation of 0.75 second, and duration of 20 seconds). A total of 640 images, axial through 16 and each 2.5 mm thick, were acquired, resulting in a total area of 3.75 cm<sup>2</sup> of the brain studied in the MCA territory.

Thereafter, the CTA was obtained by the intravenous administration of an additional 50 mL of nonionic iodinated contrast agent. The region of interest (ROI) was previously placed in the aortic arch for determining the self-timing of the apparatus, when the attenuation in this region reached 160 Hounsfield units (HU), initiating the acquisition of the sections from the aortic arch to the vertex of the skull.

The perfusion analysis was post-processed from the source images to obtain semiautomated maps of the CPCT, including cerebral blood volume (CBV), cerebral blood flow (CBF), and mean transit time (MTT). The CTA analysis included the maximum intensity projection (MIP) and tridimensional (3D) views of the intracranial and extracranial arteries. All data were post-processed using a commercially available software on a workstation (Extended Brilliance Workspace v3.5.0.2250, Philips Medical Systems Nederland B.V., PC Best, The Netherlands).

A structured form was adapted from previous reports considering the relevant imaging findings to build an effective script for the step-by-step interpretation and to objectively answer those queries to guide the clinical decision-making process concerning patients with suspected ischemic stroke (Fig 1)<sup>8</sup>.

All studies were anonymous, and the standard reading was based on the authors' interpretation of all exams, which were read by consensus and considered the imaging follow-up results. Subsequently, in order to consider only the background knowledge of the examiners, we decided to include 22 residents from our current program of radiology (11 second- and 11 third-year residents) and 6 neuroradiology fellows. The purpose of the study was described, and doubts about how to fill out the report were clarified. Neither specific training nor an image review was offered to prepare them for the study.

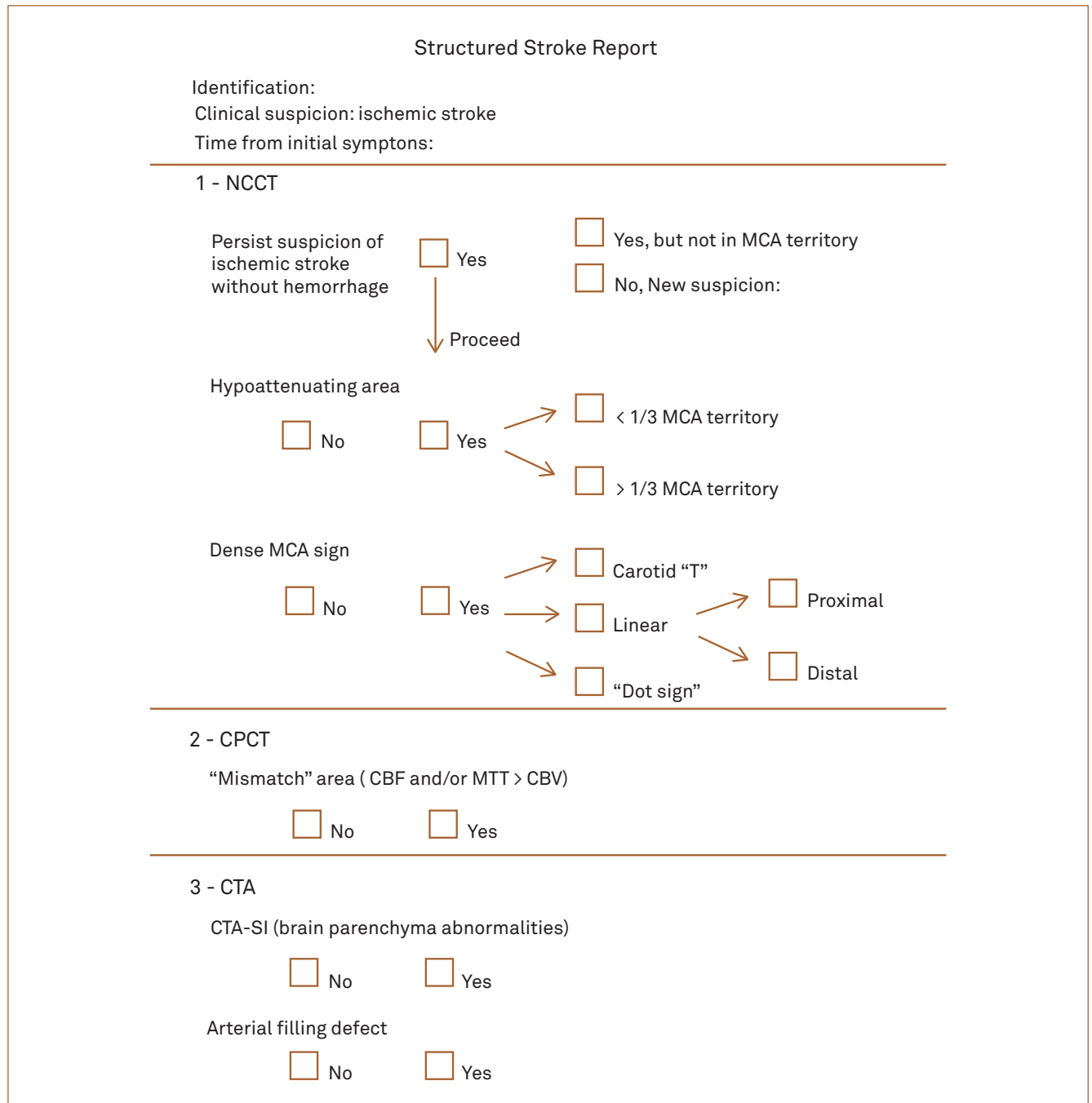
Brain parenchyma was scrutinized on NCCT, searching for intracranial hemorrhage and any abnormalities compatible with the early signs of hyperacute brain ischemia. Hypoattenuation in the MCA territory (insular

ribbon sign or loss of basal ganglia definition) was graded according to the one third rule<sup>15</sup>. On the CTA post-processed images, cervical and intracranial arteries from the carotid system were mainly examined to detect wall abnormalities, intraluminal plaques, or thrombus (filling defects). Intraluminal fresh thrombi (carotid-MCA) were defined as indicated in previous reports, according to their form and location, as a T-carotid thrombus, linear M1 thrombus or “dot sign” distal thrombus<sup>8,16,17</sup>.

Source images from the CTA (CTA-SI) acquisition were analyzed to detect hypoattenuating brain areas and

identify either an arterial obstruction or intraluminal thrombus. Mismatch areas were defined (present or absent) on the CPCT post-processed images (CBF / MTT > CBV), and they were summarized on an automatic post-processed map (“summary map”)<sup>8,18</sup>.

All examiners sequentially analyzed every parameter from the same patient to create an individual structured report for each person. The inter-observer agreement was assessed by obtaining Kappa’s coefficient for the evaluation of the proposed stroke report.



NCCT: noncontrast computed tomography; MCA: middle cerebral arteries; CPCT: cerebral perfusion computed tomography; CTA: tomography angiography.

**Fig 1.** Structured stroke report.

## RESULTS

According to the proposed criteria, 70 consecutive subjects were submitted to the established protocol, with 11 being excluded later.

The standard reading (consensus from authors and imaging follow-up analysis) included the following paragraphs.

Normal results of the multiparametric MDCT studies were documented in 33 subjects (33/59 – 55.9%). All unremarkable studies were properly identified, and none of them depicted brain ischemia on the imaging follow-up (no false positives). The remaining 26 ones (26/59 – 44.1%) had at least one abnormal parameter on the MDCT, and their imaging follow-up confirmed the variable MCA territory brain ischemia.

Hypoattenuating areas were documented on the NCCT scans in 14 subjects (14/26 – 53.8%), which were associated or not with the dense middle cerebral artery sign. After additional analysis of the CTA-SI, the sensitivity significantly increased to greater than 80%. Furthermore, the NCCT analysis, compared with both the

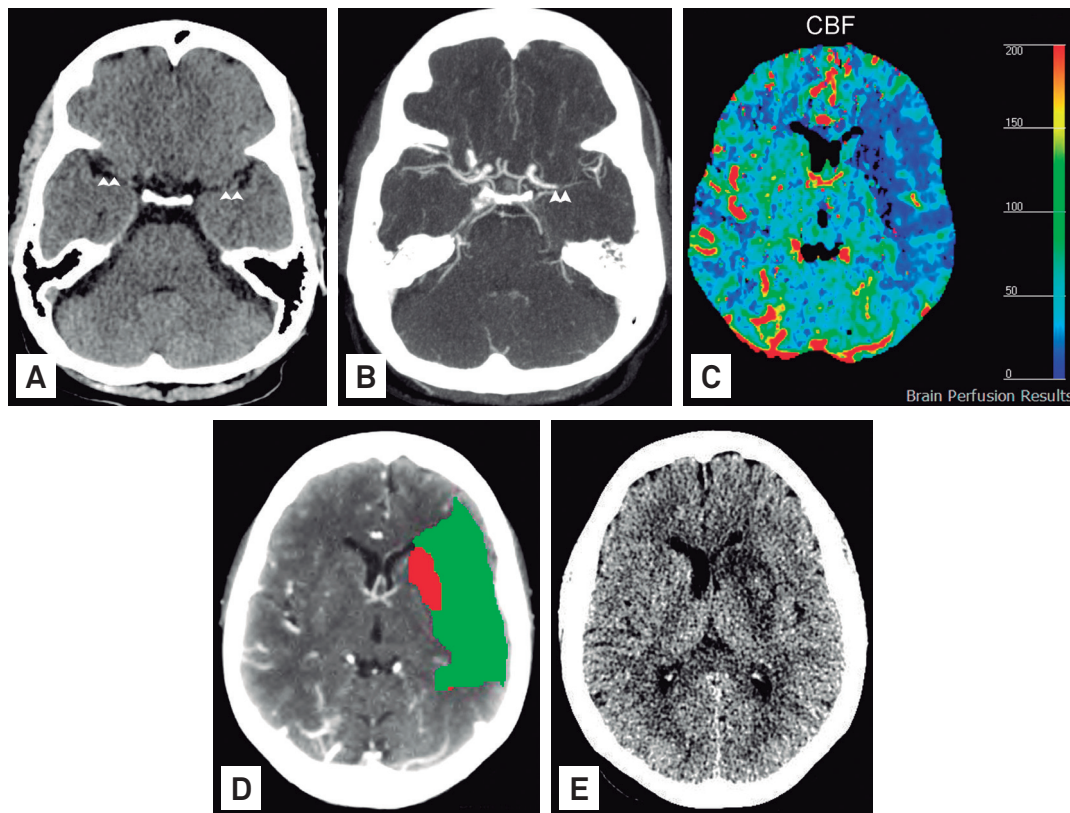
CTA and CPCT, failed to detect these abnormal areas in 12 subjects (12/26 – 46.1%).

The detection rate of the dense middle cerebral artery sign on NCCT was 38.4 % (10/26). It was labeled as the linear type (7/10), carotid “T” type (2/10), and “dot sign” (1/10). After the analysis of the arterial circulation by CTA, we found that 65.3% (17/26) of the patients had an intravascular filling defect (Fig 2).

According to the CPCT parameters, penumbra areas and ischemic core were detected in all 26 scans (Fig 3), which confirmed brain ischemia on the imaging follow-up (no false negatives). The concurrent analysis of the CPCT maps and CTA-SI allowed the detection of brain ischemia in seven additional subjects for whom the NCCT had unremarkable results (7/26 – 27.0%). CPCT was the only technique that enabled ischemia detection in another five subjects (5/26 – 19.0%).

The results of the examiners’ analysis (filled imaging reports, not considering the imaging follow-up) were the following parts herein.

All unremarkable studies were also correctly identified by examiners (no false positive reports). Considering



CBF: cerebral blood flow.

**Fig 2.** Intra-luminal thrombus undetected on the noncontrast computed tomography obtained one hour after the onset of ischemic symptoms in a 68-year-old woman. Note the absence of hyperdense artery signs on the M1 segments (arrowheads) in this noncontrast computed tomography axial scan (A). The computed tomography angiography axial post-processed image (B) depicted a filling defect in the left M1 segment (arrowheads). The perfusion computed tomography map of the cerebral blood flow (C) and “summary map”(D) demonstrated a large mismatch (green-colored area) with a small infarcted core (red-colored area) on the left brain hemisphere. The comparative noncontrast computed tomography axial scan for the imaging follow-up (E) confirmed the final infarct extension to the left striatum (larger than the previous core).



the abnormal examinations, 72.0% of the reports were correctly filled out by the second-year residents, when they analyzed the NCCT images, reaching 81.8% after the inclusion of the CTA and CPCT maps. These results characterized an almost perfect agreement ( $Kappa > 0.81$ ). The third-year residents and Neuroradiology fellows detected abnormalities in 84.1 and 90.3%, respectively, when evaluating the NCCT images, and in 90.1 and 95.8%, respectively, after the inclusion of the CPCT maps. These results also showed an almost perfect agreement ( $Kappa > 0.81$ ). These data are summarized on Tables 1 and 2.

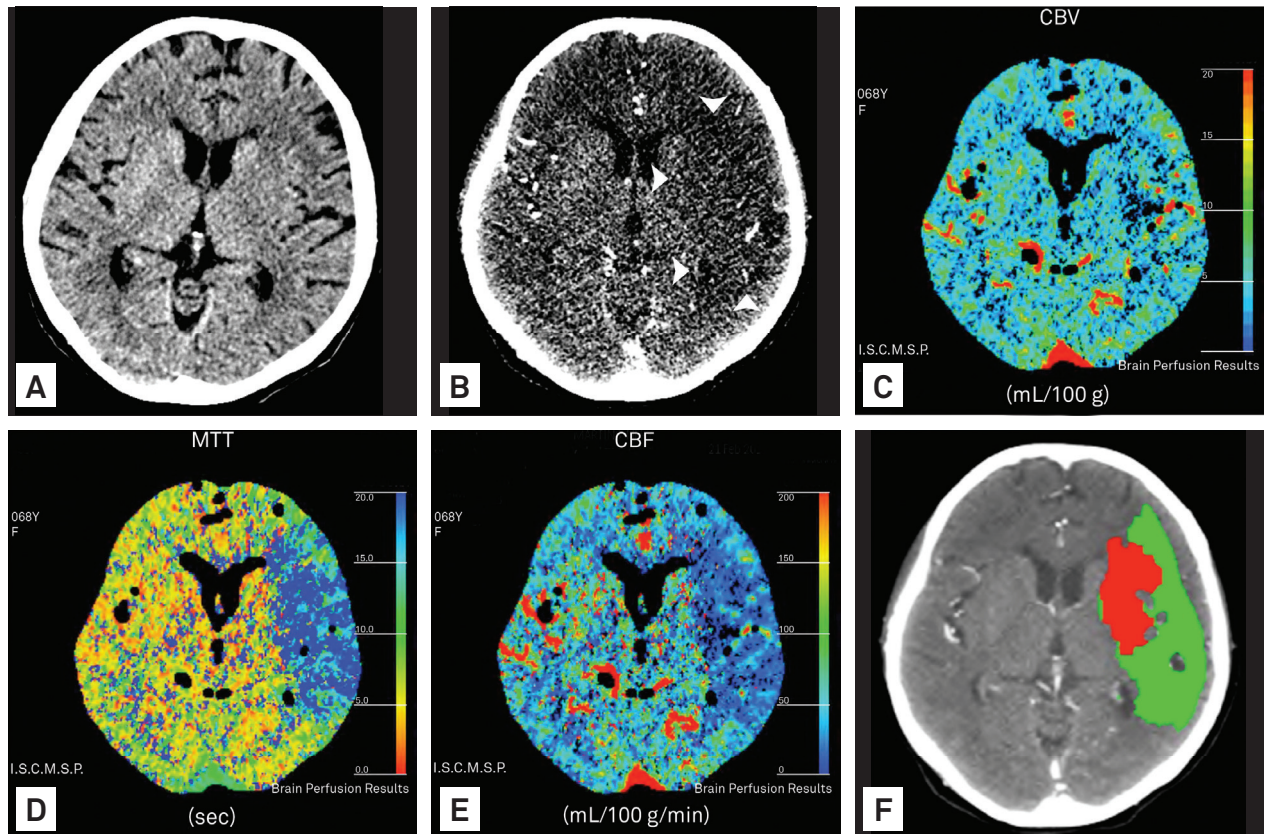
## DISCUSSION

The emergency evaluation of hyperacute stroke patients requires team harmony to quickly detect abnormalities and correctly determine the appropriate treatment. Conversely, traditional Brazilian radiologic reports describe normal and abnormal findings in an inappropriate form for this scenario. Structured protocols for imaging analysis have been proposed abroad, but the validation of

their use in Brazilian practice and for training our specialists remains to be performed<sup>8</sup>.

Fundamental queries concerning imaging diagnosis must be answered before starting therapeutics<sup>8</sup>. NCCT analysis has proven to be an accurate method for ruling out intracranial hemorrhage and identifying subtle early signs of brain ischemia<sup>16,19</sup>. However, several studies have demonstrated only poor-to-moderate inter-observer agreement in the detection of infarcts by NCCT in acute settings<sup>20,21</sup>. NCCT findings might indicate brain swelling as a relatively late phenomenon characterized by the loss of insular ribbon sign and obscuration of the lentiform nucleus sign, both detected at a lower rate in the first six hours than the results from the decreased density of brain tissue often associated with an increased density of arteries<sup>22</sup>.

Successful thrombolytic therapy depends on the selection of patients, and MDCT parameters have proven to be useful for this purpose<sup>3,12,23,24</sup>. To attend the need of a stroke unit, imaging training for doctors is mandatory. Our proposed stroke report was structured to objectively assess the most relevant imaging findings that influence



CBV: cerebral blood volume; MTT: mean transit time; CBF: cerebral blood flow.

**Fig 3.** Multiparametric multidetector computed tomography on hyperacute ischemic stroke obtained four hours after the onset of ischemic symptoms in a 68-year-old woman. The noncontrast computed tomography axial scan at the basal ganglia level (A) exhibited the loss of putaminal definition and an insular ribbon sign on the left brain hemisphere. The source images from the computed tomography angiography (B) depicted a larger hypoattenuation in the middle cerebral arteries territory (arrowheads). The perfusion computed tomography map of the cerebral blood volume (C), mean transit time (D), and cerebral blood flow (E) confirmed left middle cerebral arteries hypoperfusion (blue-colored area), and the “summary map” (F) shared information showing the mismatch (green-colored area) with a infarcted core (red-colored area).

Table 1. Data of images.

Patient	NCCT				CTA		CPCT
	Hypoattenuating area (< or > 1/3 MCA territory)	Insular ribbon sign	Loss of definition of BG	Dense carotid/MCA artery	Hypoattenuating area (smaller/larger/similar to NCCT)	Intraluminal thrombus /stenosis	Abnormal perfusion (smaller/larger/similar to CTA)
1	-	-	-	-	Similar	-	Larger
2	+ (< 1/3)	-	+	-	Larger	+	Larger
3	-	+	+	Linear	Larger	+	Larger
4	+ (> 1/3)	+	+	-	Similar	+	Larger
5	-	+	-	"Dot sign"	Larger	+	Larger
6	+ (> 1/3)	+	+	"T"	Similar	+	Larger
7	-	-	-	-	Similar	+	Larger
8	+ (> 1/3)	+	+	"T"	Larger	+	Similar
9	-	-	-	-	Similar	-	Larger
10	+ (< 1/3)	-	-	-	Similar	-	Larger
11	+ (< 1/3)	+	-	-	Larger	-	Larger
12	+ (> 1/3)	+	+	-	Larger	+	Similar
13	-	-	-	-	Similar	-	Larger
14	-	+	+	Linear	Larger	+	Larger
15	-	+	+	-	Larger	+	Larger
16	+ (> 1/3)	+	+	Linear	Similar	+	Similar
17	-	-	-	-	Larger	-	Larger
18	+ (< 1/3)	+	+	Linear	Larger	+	Similar
19	+ (< 1/3)	+	+	Linear	Larger	+	Similar
20	+ (< 1/3)	+	-	-	Similar	-	Larger
21	+ (> 1/3)	+	+	-	Similar	+	Larger
22	-	+	+	Linear	Larger	+	Similar
23	+ (< 1/3)	-	-	-	Similar	-	Larger
24	+ (< 1/3)	+	+	-	Similar	+	Larger
25	-	+	+	Linear	Larger	+	Similar
26	+ (< 1/3)	-	-	-	Similar	-	Larger

MCA: middle cerebral arteries; NCCT: noncontrast computed tomography; CTA: tomography angiography; CPCT: cerebral perfusion computed tomography.

Table 2. Inter-observer agreement.

Inter-observer agreement	NCCT	CTA	CPCT
R2	72.0%	80.3%	81.8%
R3	84.1%	87.1%	90.1%
Neuroradiology fellows	90.3%	95.9%	95.8%

NCCT: noncontrast computed tomography; CTA: tomography angiography; CPCT: cerebral perfusion computed tomography.

the clinical treatment. No false positives were derived from the NCCT analysis in our series of patients since all normal examinations were properly identified by the examiners.

After the NCCT evaluation, our proposed imaging report expressed the CPCT study, assessing the occurrence of penumbra and ischemic core areas. Some trials around the world have confirmed the relevance of patient's selection according to the demonstration of "viable ischemic brain tissue", as defined by perfusion mismatch<sup>8,14,24-26</sup>. Our results are in line with these previous studies, confirming the relevance of CPCT in detecting abnormal brain perfusion even without parenchymal NCCT abnormalities with an almost perfect agreement among the examiners<sup>6,20,21,23</sup>. Understanding CPCT maps added physiologic information to the anatomic and structural analyses of the NCCT and CTA. No false positives occurred in the analysis of the CPCT maps in our series of patients.

The last stage of our stroke protocol assessed the CTA information. On the NCCT scans, the occurrence of a hyperdense artery sign predicted an intravascular filling defect in the CTA images<sup>17</sup>. A dense middle cerebral artery was detected in 38.4% of the patients from our series, which increased to 65.3% after the CTA analysis (vessel obstruction). Similarly, parenchymal abnormalities were detected on the NCCT of our patients in agreement with the detection rate reported in the current literature<sup>17</sup>. After the additional analysis of the CTA-SI, the sensitivity significantly was superior among our examiners. These results confirmed previous reports that CTA images add sensitivity and specificity to the interpretation of NCCT for detecting neglected brain abnormalities and intravascular filling defects<sup>6,17,24,25</sup>.

The increased red blood cell content in the thrombus enables the detection of potential fresh red thrombi (hyperdense artery sign on the carotid or MCA) on NCCT, which influences the therapeutic decision-making process<sup>25</sup>. However, contrast injection on CTA enables the detection of filling defects even in the absence of red thrombus, avoiding the false-positive detection of hyperdense artery signs on the NCCT, as previously reported in cases of dehydration or advanced atherosclerosis<sup>8</sup>. In acute ischemic stroke, CTA has proven to be an accurate method for the detection of intracranial proximal arterial occlusions and stenoses that predict functional outcome, final infarct size, and response to intravenous thrombolysis, thereby facilitating the decision-making for the intra-arterial rescue procedures<sup>5,25,26</sup>. Hence, future decisions about the optimal therapy for acute strokes should consider the detection of vascular thrombus<sup>17</sup>.

The inter-observer agreement among the Neuroradiology fellows was higher than among the younger residents, presumably as a result of not neglecting relevant details during the

interpretation. Although our normal results were confirmed to be accurate for all examiners, the abnormal ones exhibited a progressive learning curve according to the radiology training program. This observation reinforces the previous suggestion that inter-observer agreement might be higher for highly-trained readers in the hyperacute ischemic stroke setting<sup>9</sup>. We argue that our results corroborate the need for specific training to interpret multiparametric examinations.

The absence of false positives was most likely derived from the interference among the judged MDCT parameters, suggesting that the sequential analysis of multiparametric complementary data facilitates the interpretation and optimistically reinforces the confidence in the diagnosis and inter-rater reliability. The addition of CPCT semiautomated maps to CTA-SI more clearly depicted the hypoattenuating areas and their size, contributing to the ability to delineate the mismatch areas.

Our study design is in line with the current guidelines reinforcing the need for the correct global analysis of data to detect parenchymal, vascular, or hemodynamic abnormalities. The development and application of multi-professional, integrated written protocols for the treatment of any suspected stroke cases are also addressed herein by this proposed stroke report<sup>10</sup>.

The limitations of the MDCT technology to evaluate ischemic stroke patients have been reported<sup>9,17</sup>. Furthermore, our study has some limitations inherited from the proposed design, including the small patient sample and absence of intraobserver analysis. However, our study design is acceptable for testing the inter-observer agreement among the training radiologists. It is a preliminary attempt to develop an auditable tool that documents specific skills to analyze multiparametric MDCT in the hyperacute stroke scenario. Related Brazilian societies and medical services could use this objective script for training and certifying specialists to work in stroke units.

In conclusion, the proposed protocol for the multiparametric MDCT study is a fast and uncomplicated tool that will help to objectively answer the most important issues of decision-making in the emergency scenario. Normal exams were correctly identified (no false positives), minimizing the risk of inappropriate intervention. Furthermore, to ensure a confident interpretation and avoid false negative results, the authors recommend adding CTA and CPCT to the NCCT analysis, clarifying the global evaluation of the structural and hemodynamic brain abnormalities.

The structured report proposed herein is valid, and it may be integrated into an assistance protocol for patients with suspected ischemic stroke as a script for the reproducible analysis of imaging exams. We also encourage its use to document the doctors' learning curve in interpreting multiparametric MDCT.

## References

1. Gonzalez RG. Imaging-Guided acute ischemic stroke therapy: from "time is brain" to "physiology is brain". *AJNR* 2006;27:7.
2. Mullins ME. CT and conventional and diffusion-weighted MR imaging in acute stroke: study in 691 patients at presentation to the emergency department. *Radiology* 2002;224:253-260.
3. Latchaw RE. Recommendations for imaging of acute ischemic stroke. *Stroke* 2009;40:3646-3658.
4. Vu D, Lev MH. Noncontrast CT in acute stroke. *Semin Ultrasound CT MR* 2005;26:380-386.
5. Saqqur M, Uchino K, Demchuk AM, et al. Site of arterial occlusion identified by transcranial Doppler predicts the response to intravenous thrombolysis for stroke. *Stroke* 2007;38:948-954.
6. Camargo ECS. Acute brain infarct: detection and delineation with CT angiographic source images versus nonenhanced CT scans. *Radiology* 2007;244:542-548.
7. Tan JC. Systematic comparison of perfusion-CT and CT-angiography in acute stroke patients. *Ann Neurol* 2007;61:533-543.
8. de Lucas EM, Sanchez E, Gutierrez A, et al. CT protocol for acute stroke: tips and tricks for general radiologists. *Radiographics* 2008;28:1673-1687.
9. Suzuki K, Morita S, Masukawa A, Machida H, Ueno E. Utility of CT perfusion with 64-row multi-detector CT for acute ischemic brain stroke. *Emerg Radiol* 2011;18:95-101.
10. Oliveira Filho J. Guidelines for acute ischemic stroke treatment - Part I. *Arq Neuropsiquiatr* 2012;70:621-629.
11. Wintermark M. Imaging of acute ischemic brain injury: the return of computed tomography. *Curr Opin Neurol* 2003;16:59-63.
12. Lovblad KO, Baird AE. Actual diagnostic approach to the acute stroke patient. *Euro Radiol* 2006;16:1253-1269.
13. Leiva-Salinas C, Wintermark M. Imaging of acute ischemic stroke. *Neuroimaging Clin N Am* 2010;20:455-468.
14. Konstas AA. CT Perfusion Imaging in acute stroke. *Neuroimaging Clin N Am* 2011;21:215-238.
15. Kalafut MA. Detection of early CT signs of > 1/3 middle cerebral artery infarctions: interrater reliability and sensitivity of CT interpretation by physicians involved in acute stroke care. *Stroke* 2000;31:1667-1671.
16. Wardlaw JM, Mielke O. Early signs of brain infarction at CT: observer reliability and outcome after thrombolytic treatment--systematic review. *Radiology* 2005;235:444-453.
17. Romero JM. CT angiography source image evaluation for stroke. *Semin Ultrasound CT MR* 2005;26:387-393.
18. Wintermarck M. Perfusion-CT assessment of infarct core and penumbra. *Stroke* 2006;37:979-985.
19. Kucinski T. Unenhanced CT and acute stroke physiology. *Neuroimaging Clin N Am* 2005;15:397-407.
20. Schriger DL, Kalafut M, Starkman S, Krueger M, Saver JL. Cranial computed tomography interpretation in acute stroke: physician accuracy in determining eligibility for thrombolytic therapy. *JAMA* 1998;279:1293-1297.
21. Shinar D, Gross CR, Hier DB, et al. Interobserver reliability in the interpretation of computed tomographic scans of stroke patients. *Arch Neurol* 1987;44:149-155.
22. Sarikaya B, Provenzale J. Frequency of various brain parenchymal findings of early cerebral ischemia on unenhanced CT scans. *Emerg Radiol* 2010;17:381-390.
23. Paciaroni M. Systematic thrombolysis in patients with acute ischemic stroke and internal carotid artery occlusion. *Stroke* 2011;43:125-130.
24. Lev MH, Farkas J, Rodriguez VR, et al. CT angiography in the rapid triage of patients with hyperacute stroke to intraarterial thrombolysis: accuracy in the detection of large vessel thrombus. *J Comp Assist Tomogr* 2001;25:520-528.
25. Barlinn K, Alexandrov AV. Vascular imaging in stroke: comparative analysis. *Neurotherapeutics* 2011;8:340-348.
26. Puetz V, Dzialowski I, Hill MD, et al. Intracranial thrombus extent predicts clinical outcome, final infarct size and hemorrhagic transformation in ischemic stroke: the clot burden score. *Int J Stroke* 2008;3:230-236.