

MITOCHONDRIAL MYOPATHY AND MYOCLONIC EPILEPSY

WALTER O. ARRUDA* — LUIZ F. B. TORRES** — ANNE LOMBES***
SALVATORE DIMAURO**** — BELKISS A. CARDOSO***** — HÉLIO A. G. TEIVE*
DUILTON DE PAOLA***** — RICARDO R. SEIXAS*****

SUMMARY — The authors describe a family (mother, son and two daughters) with mitochondrial myopathy. The mother was asymptomatic. Two daughters had lactic acidosis and myoclonic epilepsy, mild dementia, ataxia, weakness and sensory neuropathy. The son suffered one acute hemiplegic episode due to an ischemic infarct in the right temporal region. All the patients studied had hypertension. EEG disclosed photomyoclonic response in the proband patient. Muscle biopsy disclosed ragged-red fibers and abnormal mitochondria by electron microscopy. Biochemical analysis showed a defect of cytochrome C oxidase in mitochondria isolated from skeletal muscle. Several clinical and genetic aspects of the mitochondrial encephalomyopathies are discussed.

Miopatia mitocondrial e epilepsia mioclônica.

RESUMO — Os autores descrevem uma família de raça negra (mãe e três filhos) com miopatia mitocondrial. Duas irmãs tinham acidose láctica concomitante e epilepsia mioclônica. Outros achados observados nos membros mais afetados foram demência, ataxia, fraqueza muscular e neuropatia sensitiva. A mãe era assintomática. Um filho sofreu acidente vascular cerebral isquêmico envolvendo a região temporal direita. Todos os membros da família estudados eram hipertensos. EEG mostrou resposta fotomioclônica na paciente probanda. Biópsia muscular mostrou «ragged-red» fibers e mitocôndrias anormais ao estudo de microscopia eletrônica. Análise bioquímica mostrou um defeito no citocromo C oxidase nas mitocôndrias extraídas do músculo esquelético de uma paciente afetada. Aspectos clínicos e genéticos sobre as encefalomiopatias mitocondriais são discutidos.

Mitochondrial myopathies are a group of heterogeneous clinical disorders that can affect not only skeletal muscles but also multiple other systems. They are characterized by the presence of structurally and/or biochemically abnormal mitochondria^{9,10,43}. This clinical entity was first described by Luft and co-workers, in 1962, in a 35-year-old woman suffering from euthyroid hypermetabolic state due to a functional defect of the mitochondria²⁷. Muscle biopsies of patients with mitochondrial myopathies studied by modified Gomori trichrome stain show fibers with abnormal accumulation of coarse subsarcolemmal and intermyofibrillar red material, named "ragged red" fibers³⁴. Their presence is a diagnostic requisite for mitochondrial myopathy, but is not pathognomonic. They can be observed in other neuromuscular diseases

* Neurologist; ** PhD, Neuropathologist, Hospital Nossa Senhora das Graças and Hospital de Clínicas, Universidade Federal do Paraná (UFPR); *** MD, Postdoctoral Fellowship, H. Houston Merritt Clinical Research Center for Muscular Dystrophy and Related Diseases (HHMCR CMDRD), Columbia College of Physicians and Surgeons, New York; **** Professor of Neurology, HHMCR CMDRD, Columbia College of Physicians and Surgeons, New York; ***** MSc, Endocrinologist, Instituto de Biofísica Carlos Chagas Filho, Universidade Federal do Rio de Janeiro; ***** Service of Electroencephalography, Hospital de Clínicas, UFPR; ***** Neurophysiologist. Dr. Walter O. Arruda and Belkiss A. Cardoso are in receipt of a CNPq and CAPES grants, respectively.

Dr. Walter O. Arruda — Unidade de Ciências Neurológicas — Rua Gonçalves Dias 713 — 80240 Curitiba PR — Brasil.

including myasthenia gravis, thyrotoxicosis, polymyositis, myotonic dystrophy, spinal muscular atrophy and idiopathic neuropathy^{10,29,34}. Marked morphologic abnormalities of muscle mitochondria can be also observed by electron microscopy⁹.

Several neurological syndromes have been described in association with mitochondrial myopathies^{8,33,40,45} and including myoclonus epilepsy with ragged red fibers (MERRF)^{5,7,14,15,17,26,40,50,52}. In the present report we describe a family with mitochondrial myopathy associated with myoclonic epilepsy and lactic acidosis².

CASUISTICS

Family description — We studied two women and one man belonging to a kindred of 13 members (Fig. 1). Their mother was studied too. The members of the family denied consanguinity. An older maternal uncle suffered seizures and died of unknown cause. The grandparents were apparently asymptomatic.

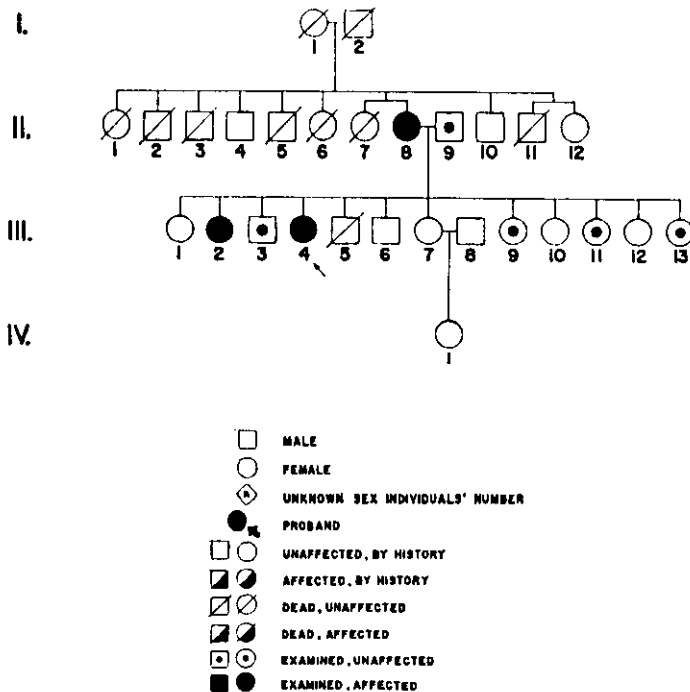


Fig. 1 — Heredogram of the family.

Case II-4 — MAM, a 32-year-old woman has had generalized tonic-clonic and partial complex epileptic attacks for the past 3 years. Myoclonic jerks, predominating at her left side appeared in the last 2 years, with progressive gait disturbance, muscular weakness predominating in the legs, and dysarthria. She also complained of occasional paresthesia in the hands and feet and dyspnea with mild efforts. Menstrual irregularity was noted since menarche (at the age of 15), with up to 6 months of amenorrhea. At the age of 9 she abandoned school due to learning disability. She could neither write nor read. Physical examination revealed a blood pressure of 150/100 mgHg, pulse of 100 bpm, respiration 16 per minute at rest, height 148 cm, weight 44000 g. She was alert and cooperative. Her speech was dysarthric, sometimes interrupted by myoclonic jerks predominantly involving the upper limbs, specially the left one. Abrupt sounds, touching and light triggered myoclonus. Cardiac examination disclosed a soft systolic bruit +/- more audible at the mitral focus. Pulmonary auscultation was normal. No visceromegaly was noted. Cranial nerve examination was

normal. Mild generalized proximal weakness (MRCP grade 4) was observed in the upper and more severe in the lower limbs. Muscle tonus and deep tendon reflexes were normal and symmetric. Plantars were flexor. Gait was ataxic and Romberg sign was positive. Diadochokynesia and eumetry were difficult to evaluate due to the myoclonic jerks. Superficial (light touch, pinprick) and deep (vibratory, proprioception) sensation was intact.

Case II-2 — APM, a 35 year-old woman, suffered from myoclonic jerks on her upper limbs, mainly in the right, and generalized tonic-clonic seizures since age 15. At age 18 she was given sodium valproate 250 mg bid with disappearance of the myoclonic episodes and good control of the generalized seizures. She could not remember the age of menarche, but the menses were regular. She also complained of a mild degree of weakness in the legs. She did not go to school. She was mildly demented, in comparison with other members of the family. Blood pressure 150/95 mmHg, heart rate 88 bpm, respiratory rate 12 mpm, height 151 cm, weight 40500 g. General physical examination was unremarkable. No involuntary movements were observed. Fundi and visual acuity were normal. Cranial nerves examination, strength and tonus, deep and superficial reflexes, gait and all modalities of sensation were normal. Plantar reflexes were flexor and Romberg manouever was negative. There was a mild degree of dysmetria and dysdiadochokynesia in upper and lower limbs.

Case III-3 — JFM, a 34 year-old man, had an acute episode of left hemiplegia at age 32, without loss of consciousness or headache. At that time his blood pressure was 250/160 mmHg. He was told that he suffered seizures as a child, but could not give further details. At the time of our evaluation, his blood pressure was 180/90 mmHg, and he was on methyldopa 1000 mg qd and hydrochlorthiazide 50 mg qd. General physical examination and neurologic examination were normal except for a left spastic hemiparesis (MRCP 3), hyperreflexia on the left and a left extensor plantar response.

Case I-2 — TCL, the 60 year-old mother of the patients described above, has had hypertension for the last 10 years and was treated with methyldopa 1000 mg qd. She has had chronic backache (osteoarthritis). Physical and neurologic examinations were normal, except for her high blood pressure (200/100 mmHg).

Laboratory data:

Case II-4 — Hemogram, urea, creatinine, glucose, sodium, potassium, calcium, magnesium, IgG, IgA, IgM, CPK, aldolase, SGOT, SGPT, LDH, TSH, T3, T4 and prolactin were normal. Fasting arterial blood gas examination showed pH 7.201, pO₂ 93.4 mmHg, pCO₂ 21.1 mmHg, bicarbonate 8.2 mg/dl, BB 30.0 BE (-18). Fasting arterial blood lactate: 107 mg/dl (normal up to 10 mg/dl). CSF examination: 2 white cells/mm³, 18 red blood cells/mm³, protein 24.4 mg/dl, glucose 67 mg/dl, chloride 690 mg/dl. The serum progesterone levels on the seventh day after five days of clomiphene 50mg/day was 13.0 ng/ml (normal luteal phase 2.5-25 ng/ml). During a luteinising hormone releasing hormone (LHRH) infusion test (100 ug iv) the serum LH rose from 18.0 mIU/ml to 90.0 mIU/ml and the FSH from 8.5 mIU/ml to 25.0 mIU/ml (maximal values 30 minutes after the end of the infusion). Chest X-ray was normal. Electrocardiogram: left anterior hemiblock + anterior subepicardic ischemia + right ventricular hypertrophy. Echocardiogram (M mode) was normal. A cerebral CT scan was normal. An electroencephalogram disclosed symmetric, irregular and mildly slowed posterior cerebral electrical activity; the posterior rhythm was formed by 6-8 Hz waves, with little modification with open/closed eyes; intermittent photostimulation triggered the appearance of bilateral synchronous high voltage polyspikes-slow wave complex (Figs. 2 and 3) accompanied by myoclonic jerks; the photo-myoclonic response was elicited at different photostimulation rates; spontaneous discharges or sequences of irregular spike-wave or polyspike-wave were seldom observed. Pattern reversal visual evoked potential (VEP) and brainstem auditory evoked potential (BAEP) studies could not be performed due to uncontrollable myoclonic jerks. Somatosensory evoked potential (SEP) study was performed with the stimulation of the right median nerve; a clearly reproducible cortical potential was obtained, with the following latencies: N20 = 21.0ms, P25 = 29.6ms, and N35 = 36.8ms; the amplitude of the cortical potential (N20-P25) after 80 stimuli was 20.0uV (normal value up to 5.5 uV); the plexal and spinal potentials could not be registered due to the involuntary movements. The results of the nerve conduction studies are depicted in table 1. Muscle biopsy (quadriceps) was frozen in liquid nitrogen and several sections studied with histochemistry techniques; small fresh fragments were readily fixed with 3% glutaraldehyde, post-fixed in osmium tetroxide, dehydrated in graded ethanol and embedded in araldite/epon,

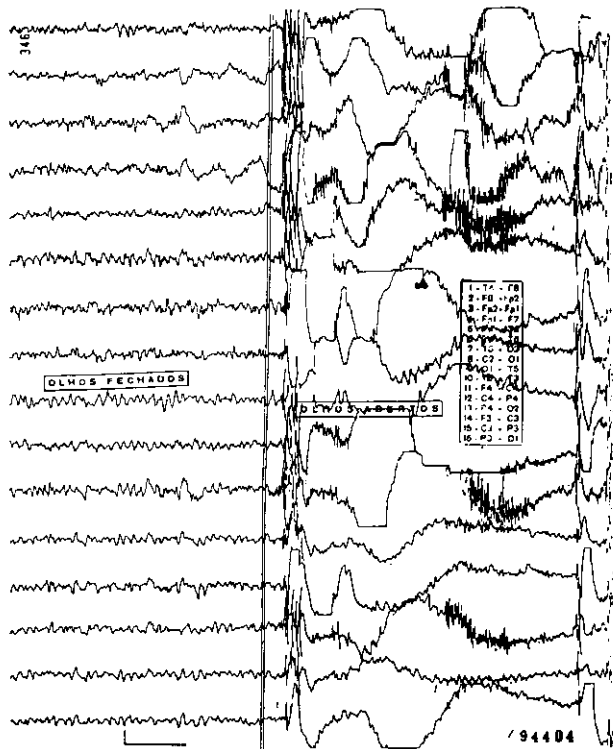


Fig. 2 — Case II-4. Posterior rhythm of 7-10 Hz waves. Sudden opening of the eyes triggers bilateral high amplitude poly spike and spike-slow waves activity, with concomitant myoclonic jerks.

for electron microscopic studies. Fresh frozen sections stained with modified Gomori trichrome 34 showed moderate variation in fibre size and shape, with diameters ranging from 40 to 90 micrometers although very few small (less than 15 micrometers) fibres were occasionally seen. There were some angulated fibres. Many ragged-red fibres were noted (Fig. 4). Electron microscopy examination showed very few abnormal mitochondria but no inclusions.

Case II-2 — Hemogram, urea, creatinine, glucose, sodium, potassium, calcium, magnesium, CPK, aldolase, SGOT, SGPT, LDH, TSH, T3, T4 were normal. Urinary screening for inborn metabolic errors was negative. Fasting arterial blood gas examination showed pH 7.408 pO₂ 99.6 mmHg, pCO₂ 26.1 mmHg, bicarbonate 16.1 mg/dl, BB 41.9, BE (-6.1). Fasting arterial blood lactate: 45 mg/dl (normal up to 10 mg/dl). CSF examination: 10 white cells/mm³ (100% mononuclear), 0 red blood cells/mm³, protein 21.6 mg/dl, glucose 61 mg/dl, chloride 760 mg/dl. Chest X-ray, electrocardiogram, and a CT scan were normal. Electroencephalogram was abnormal, but changes were nonspecific and there were no photomyoclonic responses. Pattern reversal VEP study was normal in both eyes, with P100 amplitude of 14 uV (right eye) and 9.0 uV (left eye). BAEP study was normal in both ears. SEP study (site of stimulation: right median nerve) showed the following latencies: plexal potential (N9) = 12.0 ms, spinal potential (N13) = 15.2 ms, and cortical potential (N20) = 22.4 ms; the interlatencies were normal; there was an absolute increase of all latencies caused by decrease of the peripheral nerve conduction (Table 1). Muscle biopsy disclosed similar histological abnormalities as described for case II-4, although there were comparatively more ragged-red fibers and no small atrophic fibres. Electron microscopy (Fig. 5) showed mild myofibrillar disruption with abnormal, mitochondria.

Case III-3 — The following laboratory tests were normal or negative in January, 1986, when he suffered the stroke episode: hemogram, erythrocyte sedimentation rate, sodium, potassium, glucose, creatinine, cholesterol, triglycerides, hepatic transaminases, alkaline phosphatase, TAP

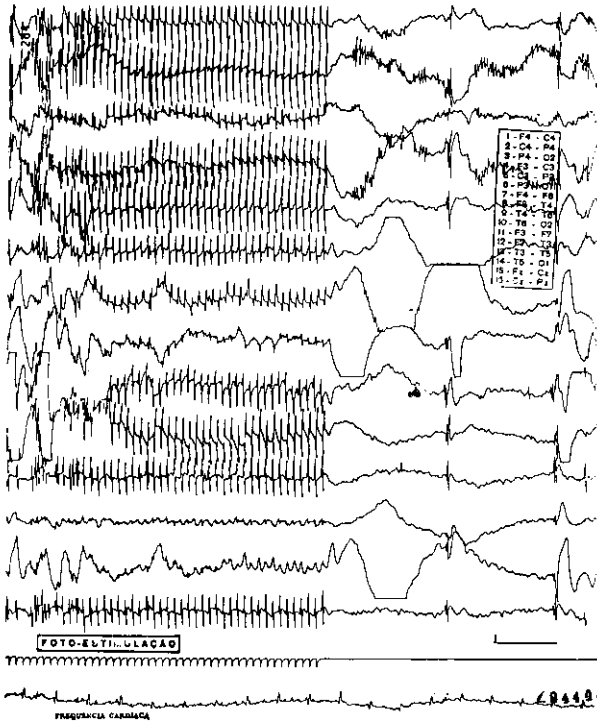


Fig. 3 — Case II-4. Typical photomyoclonic response. After stopping photostimulation some high amplitude, bilateral and irregular spike-wave and poly-spike wave discharges are observed.

	Case II-4	Case II-2
Median nerve		
MNCV (m/s)	44.5 (12.0)	44.5
DL (ms)	2.8	5.0
SNCV (m/s)	48.5 (4.0)	32.0 (3.5)
Fibular nerve		
MNCV (m/s)	41.0 (11.0)	28.0 (11.0)
DL (ms)	4.6	10.4
Sural nerve		
SNCV (m/s)	31.0 (3.0)	28.0 (15.0)

Table 1 — Nerve conduction study results. MNCV, motor nerve conduction velocity; DL, distal latency; SNCV, sensory nerve conduction velocity (orthodromic); interparenthesis values are amplitudes, expressed in millivolts (MNCV) and microvolts (SNCV).

(prothrombin activity time) and VDRL. A chest X-ray was normal. At that time a CT scan disclosed an ischemic infarct in the deep right temporal region, without contrast enhancement. Bilateral carotid angiography was normal. CPK, aldolase, SGOT, SGPT, LDH, T3, T4, and TSH were normal. Electrocardiogram showed a variable P-R segment (0.14-0.26 s), with occasional ventricular ectopic beats. Muscle biopsy showed very minimal abnormalities: there was a mild variation in fibre size with occasional small fibers (less than 25

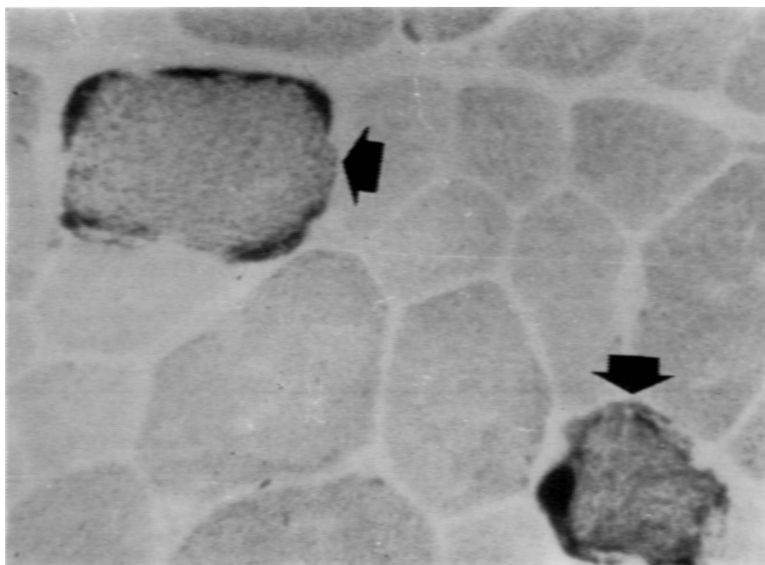


Fig. 4 — Frozen section studied with NADH-TR reaction showing a more intense staining particularly under the sarcolemma, with disruption of fibre architecture (arrows). Note the variation of shape and size of the muscle fibres (Case II-4, $\times 400$).

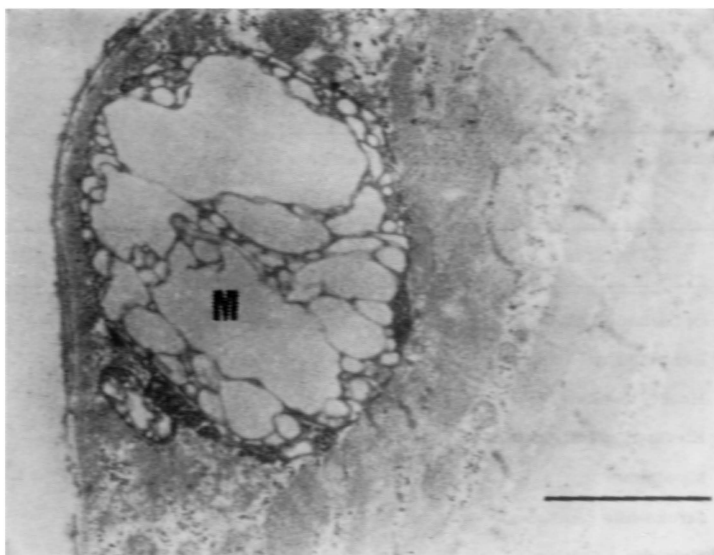


Fig. 5 — Electron micrograph showing a swollen and enlarged abnormal mitochondria (M) (Case II-2; bar = 2 μ m).

micrometers), although most fibers ranged from 50 to 90 micrometers; some fibres showed slight increase in mitochondrial content but no ragged-red fibres were identified. Electron microscopy was not helpful.

Case I-2 — CPK, aldolase, SGOT, SGPT, LDH, T3, T4, and TSH were normal. Electrocardiogram showed left ventricular hypertrophy. Muscle biopsy showed several ragged-red fibers and electron microscopy demonstrated abnormal enlarged mitochondria.

A muscle sample from patient II-4 was frozen in liquid nitrogen, shipped on solid carbon dioxide, and stored at -70°C . Biochemical studies were performed in mitochondria isolated from this muscle sample. The results are showed in table 2.

Patient II-4 had been treated with carbamazepine and clonazepam, with partial reduction of seizures and myoclonic jerks. Sodium valproate was started and carbamazepine gradually tapered. There was a marked reduction of the myoclonic and photomyoclonic phenomena and seizures became rare. As a therapeutic trial, patient II-4 received vitamin C 1.0 g tid + vitamin K 10 mg tid for 3 months, without clinical response. Patient II-2 was already taking sodium valproate alone, with good control of epilepsy and disappearance of the myoclonic movements.

	Case II-4	Controls (n = 29)	
		mean	SD
Serum (μM)			
Total carnitine	31.96	51.5	11.6
Free carnitine	27.11	40.1	9.5
Muscle ($\mu\text{moles/min/g}$)			
Cytochrome c oxidase	1.36	2.48	0.58
Succinate cytochrome c reductase	1.19	0.97	0.48
NADH cytochrome c reductase (rotenone sensitive assay)	0.85	2.06	1.14
Citrate synthase	17.28	20.05	9.02
NADH dehydrogenase	27.90	44.51	31.47
Succinate dehydrogenase	3.87	2.12	0.69

Table 2 — Results of biochemical studies. n, number of controls.

Features	KSS	MELAS	MERRF
Ophthalmoplegia	+	—	—
Retinopathy	+	—	—
Heart block	+	—	—
Elevated CFS protein	+	—	—
Myoclonus	—	—	+
Stroke-like episodes	—	+	—
Episodic vomiting	—	+	—

Table 3 — Clinical and laboratory characteristics in the three syndromes with mitochondrial encephalomyopathies. Weakness, dementia, ataxia, short stature, peripheral neuropathy, sensorineural hearing loss, and lactic acidosis are possible features common to all syndromic groups.

COMMENTS

Mitochondrial myopathies are a group of diseases characterized by defects in mitochondrial metabolism^{9,33,46,58}. These disorders are often multisystemic, involving central nervous system (CNS), skeletal muscle, peripheral nerves, heart, eye, endocrine glands, liver and kidney^{11,32,36,42,43}. The term "mitochondrial encephalomyopathies" (MEM)⁴³ or "mitochondrial cytopathies"¹¹ may be indeed more suitable when muscle involvement is only one clinical aspect of these disorders. The mitochondrial encephalomyopathies can be divided into two groups according to the age of onset³⁶. In the first group, the patient is either ill from birth or shows symptoms soon after birth and death commonly occurs in childhood. This group includes Alper's disease (progressive cerebral poliodystrophy), Canavan's disease (spongy degeneration of the white matter), Leigh's disease (subacute necrotizing encephalomyelopathy), and Menke's disease (kinky hair syndrome, trichopolydystrophy)^{9,43,55}. In the second group, the patient appears normal at birth and the neurologic disorder develops later. Some authors⁹ have proposed a classification of this group into a number of specific syndromes, such as the Kearns-Sayre syndrome (KSS), the syndrome of mitochondrial myopathy, encephalopathy, lactic acidosis and stroke-like episodes (MELAS)³⁵, and that of myoclonic epilepsy with ragged red fibers (MERRF)^{15,48} (Table 3).

The family described here belongs to the group MERRF. Since the first brief report by Tsairis et al.⁴⁸, in 1973, several cases of MERRF have been published^{7,14,15,17,25,26,31,38,39,40}. The MERRF syndrome can be readily distinguished from the other forms of progressive myoclonus epilepsy, in which mitochondrial abnormalities in the muscle biopsies are not observed⁴. Fukuhara et al.¹⁵ gave the first detailed description of this syndrome and suggested that the association of myoclonus epilepsy with ragged-red fibers could represent a distinct disease entity. Different biochemical errors of the respiratory chain have been reported in individuals with MERRF, affecting rotenone-sensitive NADH-oxidase (complex I)¹⁷, succinate-cytochrome c reductase (complex II)³⁸, cytochrome b (complex III)³¹, and cytochrome c oxidase (complex IV)^{5,26}. Wallate et al.⁵⁰ reported a combined defect of complex I and complex IV in muscle biopsies from two members of the pedigree described by Rosing et al.⁴⁰. On the other hand, Byrne et al.⁷ described a 55-year-old man with MERRF in whom the mitochondrial respiratory chain was biochemically intact, while Petty et al.³⁷ described a 21-year-old man with mitochondrial ATPase deficiency, a defect of energy conservation and transduction³¹. Conversely, a wide spectrum of clinical presentation can occur with the same apparent biochemical defect^{25,37,55}. This may be due to differences in the distribution of defective mitochondria in different organs, or to heterogeneity of the enzymatic abnormality at a molecular level. If the genetic defect is in mitochondrial DNA (mtDNA), different phenotypic expressions may be due to different percentages of mutated mtDNAs in different tissues. If the genetic error affects nuclear DNA, the differential involvement of tissues may be due to the presence of tissue-specific isozymes, whose nuclear gene is mutated. The existence of cases with characteristics of both MERRF and MELAS makes it difficult to clearly differentiate the two syndromes^{16,25,35}. The possibility of an overlap of MERRF and MELAS was raised in patient III-3. However, severe arterial hypertension could have caused his stroke episode. Moreover there were no other tomographic findings commonly found in patients with MELAS or MELAS+MERRF (e.g. basal ganglia calcification, cerebral and cerebellar atrophy, other low-density areas in the cerebral hemispheres)^{35,51,52}, or additional characteristic manifestations of MELAS.

The EEG abnormalities in our patients were similar to those observed in other cases^{7,11,13,15,17,25,26,29,31,39,45,48} and were non-specific, with the exception of the photomyoclonic response. Light sensitivity on the EEG was previously observed in some cases^{8,15,17,26,39,40,48}, but is not exclusively seen in myoclonic epilepsy^{4,33}. Although a marked photosensitivity was observed in our most affected patient, the degree of photomyoclonic response is not correlated with the severity of the disease⁴⁰. High-amplitude responses on the VEP and SSEP studies, as observed in patient II-4, have already been observed in other patients with myoclonic epilepsy, with and without MEM^{4,24,40}. VEP, BAEP and SSEP were normal in two patients with a MERRF syndrome³⁸, whereas abnormal BAEP was reported in a 46 year-old man with respiratory distress and with evidence by MRI of several high-intensity areas from the midbrain to the medulla⁴⁶.

Peripheral neuropathy is a relatively common complication in patients with MEM⁵³, although asymptomatic most of the time. Electrophysiologically, there is a mixed impairment of motor and sensory conduction, with mild-to-moderate slowing of

nerve conduction^{37,53}. Sural nerve biopsy disclosed chronic axonal degeneration and loss of myelinated fibers^{7,15,53}. Abnormal mitochondria containing paracrystalline inclusions were observed in the Schwann cells of some patients⁵³. Several endocrine disturbances have been reported in patients with MEM including diabetes mellitus^{6,11,29,47}, hypoparathyroidism^{20,47}, short stature (with and without growth hormone deficiency^{11,23,31,34,37,40,52} and hypogonadism^{14,22,29}. In this family, short stature was present even in non-affected members. This raises the question of a family trait not related to the mitochondrial problem. The menstrual disturbance of case II-4 was not clearly elucidated, since the results of the investigation of the hypothalamus-hypophysis-ovarian system were normal. Heart involvement is a hallmark in Kearns-Sayre syndrome, where defects of cardiac conduction arte characteristic and are due to degeneration of the His-Purkinje system and progressive infranodal block³⁶. Cardiac abnormalities in other forms of MEM are relatively common^{7,9,13,23,29,31,35,37,47}, but they are rarely severe^{13,53}. Hypertrophic cardiomyopathy in association with cataract has been described in some families with MEM⁴². Heart hypertrophy was excluded in patient II-4 by M-mode echocardiography and the electrocardiographic changes we found in our patients might be caused by arterial hypertension^{29,47}.

The mode of transmission in MEM has been an interesting matter of investigation^{9,11,13,40,54}. The mitochondrion has its own genetic material, a double-stranded circular molecule of DNA (mtDNA). The mtDNA is responsible for coding only 10% (13 polypeptides) of total mitochondrial proteins. In the formation of the zygote, all mitochondria are provided by the ovum. Therefore, the mitochondrial genome is transmitted in a "vertical", nonmendelian fashion. This is called "maternal" or "mitochondrial" inheritance and the genetic information is transmitted only from females to both females and males¹². Maternal inheritance provides some explanations for the great variation of clinical expression in families with MEM^{9,40}. Each cell contains thousand copies of mtDNA, so the cellular phenotype is a product of the ratio of mutant and wild-type mtDNAs. The mutant phenotype becomes only expressed when the proportion of mutant DNAs exceeds a certain threshold. The severity of the symptoms may reflect the proportion of mutant mtDNAs within the original ovum and the cells derived from it. This model would explain the "incomplete penetrance" of the maternal inherited diseases, including some of the MEM. In fact, this kind of genetic transmission was confirmed in a large American family with MERRF⁴⁰, and could be operative in our family and in other pedigrees^{5,15,26,39,43,54}. However, maternal inheritance is not manifested in many families with MEM^{11,21,45}. As most mitochondrial proteins, including components of the respiratory-chain complexes, are encoded by nuclear DNA, it is not surprising that Southern analysis of mitochondrial DNA have failed to find deletions of mtDNA in most patients with MEM^{18,19,54}.

The therapeutic approach to patients with MEM includes the avoidance of drugs that can inhibit the function of respiratory chain (barbiturates, phenytoin) and the mitochondrial protein synthesis (chloramphenicol, tetracycline)³⁶. The use of valproic acid in the control of epileptic fits and myoclonus in our patients was very impressive, and should be probably indicated in these cases⁴⁴. Some drugs have been used with anecdotal good success in patients with MEM. Successful treatment with riboflavin, vitamin B₂, was reported in a case with NADH-CoQ reductase (complex I) deficiency³. Vitamin K₃ and vitamin C provided clinical and metabolic improvement in a patient with complex III deficiency¹. These compounds were used for their apparent capacity to bypass the defective complex III and bridge the block in the respiratory chain between coenzyme Q and cytochrome c.

Acknowledgments — Prof. Noboro Miasaki, Department of Pediatrics, Hospital de Clinicas, Universidade Federal do Paraná, performed the lactic acid determinations. Dr. Admar Moraes de Souza performed the M-mode echocardiogram. Prof. Paulo R. Cruz Marquetti kindly reviewed the electrocardiograms.

REFERENCES

1. Argov Z, Bank WJ, Maris J, Eleff S, Kennaway NG, Olson RE, Chance B — Treatment of mitochondrial myopathy due to complex III deficiency with vitamins K₃ and C: a 31P-NMR follow-up study. *Ann Neurol* 19:598, 1986.
2. Arruda WO, Torres LFB, Teive HAG, Seixas RR, Paola D, Cardoso BA, Paola R, Parolin MKF — Miopatia mitocondrial e epilepsia mioclônica: um estudo familiar. Tema livre do XIII Congresso Brasileiro de Neurologia. *Arq Neuro-Psiquiat (São Paulo)* 46 (Suppl): 145, 1988.

3. Arts W, Scholte H, Bogard J, Kerrebijn KF, Luyt-Houwen IEM — NADH-CoQ reductase deficient myopathy: successful treatment with riboflavin. *Lancet* 2:581, 1983.
4. Berkovic SF, Andermann F, Carpenter S, Wolfe LS — Progressive myoclonus epilepsies: specific causes and diagnosis. *N Engl J Med* 315:296, 1986.
5. Berkovic SF, Carpenter S, Karpati G, Andermann F, Andermann E, Shoubrisse E, Arnold D — Cytochrome C oxidase deficiency: a remarkable spectrum of clinical and neuropathological findings in a single family. *Neurology* 37(Suppl):233, 1987.
6. Bradley WG, Tommlinson BE, Hardy M — Further studies of mitochondrial and lipid storage myopathies. *J Neurol Sci* 35:201, 1978.
7. Byrne E, Dennett X, Trounce I, Burdon J — Mitochondrial myoneuropathy with respiratory failure and myoclonic epilepsy: a case report with biochemical studies. *J Neurol Sci* 71:273, 1985.
8. D'Agostino AN, Ziter FA, Rallison ML, Bray PF — Familial myopathy with abnormal mitochondria. *Arch Neurol* 18:388, 1968.
9. DiMauro S, Bonilla E, Zeviani M, Nakagawa M, DeVivo DC — Mitochondrial myopathies. *Ann Neurol* 17:521, 1985.
10. Dobkin BH, Verity MA — Familial progressive bulbar and spinal muscular atrophy: juvenile onset and late morbidity with ragged-red fibers. *Neurology* 26:754, 1976.
11. Egger J, Lake BD, Wilson J — Mitochondrial cytopathy: a multisystem disorder with ragged-red fibers on muscle biopsy. *Arch Dis Child* 56:741, 1981.
12. Egger J, Wilson J — Mitochondrial inheritance in a mitochondrially mediated disease. *N Engl J Med* 309:142, 1983.
13. Fisher ER, Danowski TS — Mitochondrial myopathy. *Am J Clin Pathol* 51:619, 1969.
14. Fitzimons RB, Clifton-Bligh P, Wolfenden WH — Mitochondrial myopathy and lactic acidemia with myoclonic epilepsy, ataxia and hypothalamic infertility: a variant of Ramsay-Hunt syndrome? *J Neurol Neurosurg Psychiat* 44:79, 1981.
15. Fukuhara N, Tokiguchi S, Shirakawa K, Tsubaki T — Myoclonus epilepsy associated with ragged-red fibres (mitochondrial abnormalities): disease entity or a syndrome? *J Neurol Sci* 47:117, 1980.
16. Fukuhara N — Strokeliike episodes in MERRF. *Ann Neurol* 18:368, 1985.
17. Garcia Silva MT, Aicardi J, Goutierres F, Chevrie JJ — The syndrome of myoclonic epilepsy with ragged-red fibers: report of a case and review of the literature. *Neuropediatrics* 18:200, 1987.
18. Holt IJ, Harding AE, Morgan-Hughes JA — Mitochondrial DNA polymorphism in mitochondrial myopathy. *Hum Genet* 79:53, 1988.
19. Holt IJ, Harding AE, Morgan-Hughes JA — Deletions of mitochondrial DNA in patients with mitochondrial myopathies. *Nature* 331:717, 1988.
20. Horwitz SJ, Roessmann U — Kearns-Sayre syndrome with hypoparathyroidism. *Ann Neurol* 3:513, 1978.
21. Hudgson P, Bradley WG, Jenkinson M — Familial «mitochondrial» myopathy: a myopathy associated with disordered oxidative metabolism in muscle fibres. Part I: Clinical, electrophysiological and pathological findings. *J Neurol Sci* 16:343, 1972.
22. Julien J, Vital C, Vallat JM, Roger P, Lunel G, Vallat M — Myopathie oculaire avec hypogonadisme primaire: anomalies mitochondriales en ultrastructure. *Rev Neurol (Paris)* 128:365, 1973.
23. Kenaway NG, Buist RNM, Darley-Usmar VM, Papadimitriou A, DiMauro S, Kelley RI, Capaldi RA, Blank NK, D'Agostino A — Lactic acidosis and mitochondrial myopathy associated with deficiency of several components of complex III of the respiratory chain. *Pediatr Res* 18:991, 1984.

24. King JO — Progressive myoclonic epilepsy due to Gaucher's disease in an adult. *J Neurol Neurosurg Psychiat* 38:849, 1975.
25. Kuriyama M, Umezaki H, Fukuda Y, Osame M, Koike K, Tateishi J, Igata A — Mitochondrial encephalomyopathy with lactate-pyruvate elevation and brain infarctions. *Neurology* 34:72, 1984.
26. Lombes A, Mendell JR, Nakase H, Barohn RJ, Bonilla E, Zeviani M, Yates AJ, Omerza J, Gales TL, Nakahara K, Rizzuto R, Engel K, DiMauro S — Myoclonic epilepsy and ragged-red fibers (MERRF) with cytochrome c oxidase deficiency: neuropathological, biochemistry, and molecular genetics. *Ann Neurol* (in press).
27. Luft R, Ikkos D, Palmieri G, Ernster L, Afzelius B — A case of severe hypermetabolism of nonthyroid origin with a defect in the maintenance of mitochondrial respiratory control: a correlated clinical, biochemical, and morphological study. *J Clin Invest* 41:1776, 1962.
28. Markesbery WR — Lactic acidemia, mitochondrial myopathy, and basal ganglia calcification. *Neurology* 29:1057, 1979.
29. McLeod JG, Baker WC, Shorey CD, Kerr CB — Mitochondrial myopathy with multisystem abnormalities and normal ocular movements. *J Neurol Sci* 24:39, 1975.
30. Morgan-Hughes JA, Darveniza P, Kahn SN, Landon DN, Sherratt RM, Land JM, Clark JB — A mitochondrial myopathy characterized by a deficiency in reducible cytochrome b. *Brain* 100:617, 1977.
31. Morgan-Hughes JA, Hayes DJ, Clark JB, Landon DN, Swash M, Stark RJ, Rudge P — Mitochondrial encephalomyopathies: biochemical studies in two cases revealing defects in the respiratory chain. *Brain* 105:553, 1982.
32. Mullie MA, Harding AE, Petty RKH, Ikeda H, Morgan-Hughes JA, Sanders MD — The retinal manifestations of mitochondrial myopathy: a study of 22 cases. *Arch Ophthalmol* 103:1825, 1985.
33. Neville HE, Brooke MH, Austin JH — Studies in myoclonus epilepsy (Lafora body form): IV. Skeletal muscle abnormalities. *Arch Neurol* 30:466, 1974.
34. Olson W, Engel WK, Walsh GO, Einaugler R — Oculocraniosomatic neuromuscular disease with «ragged-red» fibers. *Arch Neurol* 26:193, 1972.
35. Pavlakis SG, Phillips PC, DiMauro S, DeVivo DC, Rowland LP — Mitochondrial myopathy, encephalopathy, lactic acidosis, and stroke-like episodes: a distinctive clinical syndrome. *Ann Neurol* 16:481, 1984.
36. Peterson PL, Martens ME, Lee CP — Mitochondrial encephalomyopathies. *Neurol Clin* 6:529, 1968.
37. Petty RKH, Harding AE, Morgan-Hughes JA — The clinical features of mitochondrial myopathy. *Brain* 109:915, 1986.
38. Riggs JE, Shochet SS, Fakadei AV, Papadimitriou A, DiMauro S, Crosby TW, Gutmann L, Moxley III, RT — Mitochondrial encephalomyopathy with decreased succinate-cytochrome c reductase activity. *Neurology* 34:48, 1984.
39. Roger J, Pelisier JF, Dravet C, Bureau-Paillas M, Arnoux M, Larrieu JL — Dégénérescence spino-cérébelleuse, atrophie optique, épilepsie-myoclonies et myopathie mitochondriale. *Rev Neurol (Paris)* 138:187, 1982.
40. Rosing HS, Hopkins LC, Wallace DC, Epstein CM, Weidenheim K — Maternally inherited mitochondrial myopathy and myoclonic epilepsy. *Ann Neurol* 17:228, 1985.
41. Rustam H, Hamdi T, Witri S — Progressive familial myoclonus epilepsy. *J Neurol Neurosurg Psychiat* 38:845, 1975.
42. Sengers RCA, Stadhouders AM, Lakwijk-Vondrovicova E, Kubat K, Ruitenbeek W — Hypertrophic cardiomypathy associated with a mitochondrial myopathy of voluntary muscles and congenital cataract. *Br Heart J* 54:543, 1985.
43. Shapira Y, Harel S, Russell A — Mitochondrial encephalomyopathies: a group of neuromuscular disorder with defects in oxidative metabolism. *Israel J Med Sci* 13:161, 1977.

44. Somerville ER, Olanow CW — Valproic acid: treatment of myoclonus in dyssynergia cerebellaris myoclonica. *Arch Neurol* 39:527, 1982.
45. Spiro AJ, Moore CL, Prineas JW, Strasberg PM, Rapin I — A cytochrome-related inherited disorder of the nervous system and muscle. *Arch Neurol* 23:103, 1970.
46. Tatsumi C, Takahashi M, Yorifuji S, Kitaguchi M, Tarui S — Mitochondrial encephalomyopathy, ataxia, and sleep apnea. *Neurology* 37:1429, 1987.
47. Toppet M, Telerman-Toppet N, Szliwowski HB, Vaincel M, Coers C — Oculocraniosomatic neuromuscular disease with hipoparathyroidism. *Am J Dis Child* 131:437, 1977.
48. Tsairis P, King Engel W, Kark P — Familial myoclonic epilepsy syndrome associated with skeletal muscle mitochondrial abnormalities. *Neurology* 23:408, 1973.
49. Vilming ST, Dietrichson P, Isachsen MM, Lovvik L, Heiberg A — Late-onset hereditary myopathy with abnormal mitochondria and progressive dementia. *Acta Neurol Scand* 73:502, 1986.
50. Wallace DL, Zheng X, Lott MT — Familial mitochondrial encephalomyopathy (MERRF): genetic, pathophysiological, and biochemical characterization of a mitochondrial DNA disease. *Cell* 55:601, 1988.
51. Werneck LC, Abdalla H, Lohr A — MELAS (Mitochondrial encephalopathy, lactic acidosis and stroke like episodes). *Arq Neuro-Psiquiat (São Paulo)* 45:288, 1987.
52. Yamamoto T, Bepu H, Tsubaki T — Mitochondrial encephalomyopathy: fluctuating symptoms and CT. *Neurology* 34:1456, 1984.
53. Yannikas C, McLeod JG, Pollard JD, Baverstock J — Peripheral neuropathy associated with mitochondrial myopathy. *Ann Neurol* 20:249, 1986.
54. Zeviani M, Moraes CT, DiMauro S, Nakase H, Bonilla E, Schon EA, Rowland LP — Deletions of mitochondrial DNA in Kearns-Sayre syndrome. *Neurology* 38:1339, 1988.
55. Zeviani M, Bonilla E, DeVivo DC, DiMauro S — Mitochondrial diseases. *Neurol Clin* 7:123, 1989.
56. Zinn AB, Kerr DS, Hoppel CL — Fumarase deficiency: a new cause of mitochondrial encephalomyopathy. *N Engl J Med* 315:469, 1986.