

Ataxia telangiectasia

Ataxia telangiectasia

Leticia Sauma, Karine C. S. Teixeira, Maria Augusta Montenegro

Ataxia-telangiectasia is an autosomal recessive disorder caused by mutation in the ATM gene. Symptoms are characterized by progressive cerebellar ataxia, dysarthria, oculomotor apraxia, chorea/dystonia, oculocutaneous telangiectasias, endocrine dysfunction, immunodeficiency, premature aging, radiosensitivity, and predisposition to cancer. Ataxia is evident in the first year of life, and results in wheelchair dependency

for most children by age of 10 years-old. Laboratory tests show raised serum alpha-fetoprotein levels. Brain MRI shows cerebellar atrophy (Figure). It may also show multiple T1 and T2 hypointense foci suggestive of hemosiderin, probably related to thrombosis and vascular leaks from multiple capillary telangiectasias^{1,2}. There is no definitive treatment available³.

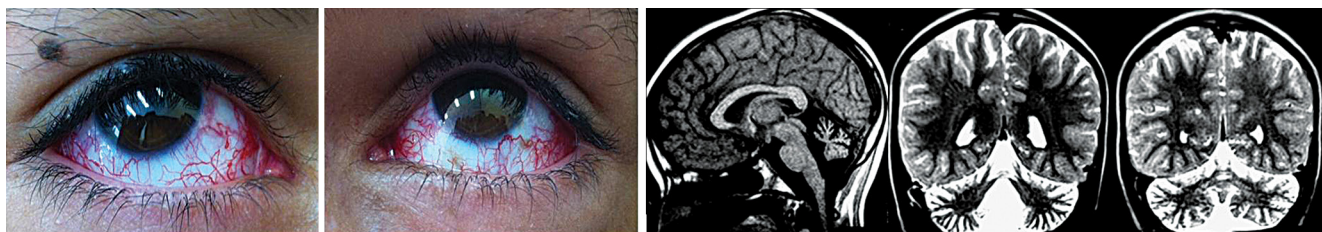


Figure. Nine year-old boy who presented gait difficulties since age two-years-old. Left figures: bilateral ocular telangiectasias. Right figures: MRI (sagittal T1 and coronal T2) images showing cerebellar atrophy.

References

1. Lin, DD, Barker PB, Lederman HM, Crawford TO. Cerebral abnormalities in adults with ataxia-telangiectasia. *AJNR Am J Neuroradiol.* 2014;35(1):119-23. <http://dx.doi.org/10.3174/ajnr.A3646>
2. Sahama I, Sinclair K, Pannek K, Lavin M, Rose S. Radiological imaging in ataxia telangiectasia: a review. *Cerebellum.* 2014;13(4):521-30. <http://dx.doi.org/10.1007/s12311-014-0557-4>
3. Chaudhary MW, Al-Baradie RS. Ataxia-telangiectasia: future prospects. *Appl Clin Genet.* 2014;7:159-67. <http://dx.doi.org/10.2147/TACG.S35759>

Universidade Estadual de Campinas, Departamento de Neurologia, Campinas SP, Brazil.

Correspondence: Maria Augusta Montenegro; Departamento de Neurologia, FCM/ Unicamp; Rua Tessália Vieira de Camargo, 126; 13083-887 Campinas SP, Brasil; E-mail: guga.32@hotmail.com

Conflict of interest: There is no conflict of interest to declare.

Received 23 December 2014; Received in final form 20 March 2015; Accepted 09 April 2015.