

ORGANIC AND INORGANIC BONE GRAFT USE IN RABBITS' RADIUS SURGICAL FRACTURES REPAIR: AN EXPERIMENTAL AND COMPARATIVE STUDY

ELSON SOUZA MIRANDA¹, FERNANDA TÉRCIA SILVA CARDOSO², JOÃO FELIPE DE MEDEIROS FILHO³, MÁRCIO D'ANGELO RODRIGUES BARRETO⁴, RAMON MARCELLO DE MACEDO TEIXEIRA⁴, ANDREY LEAL WANDERLEY⁵, KALYANA EDUARDO FERNANDES⁶

SUMMARY

Study carried out with the purpose of evaluating the outcomes of rabbits' radius fracture unions by using both organic and mineral bone grafts. For the study, 20 adult animals, both males and females, weighing around 3.0 and 3.5 kg, sourced by Maranhão State University Animal Lab were employed. The animals were divided into two similar groups and subjected to a simple complete transverse osteotomy on the right radius diaphysis, with 1 cm of bone fragment being removed. In group I (G1), an organic bone fragment from the iliac wing of the same animal was placed at the osteotomy site; in group II (G2), an Osteosynt inorganic bone graft, composed by synthetic hydroxyapatite and calcium phos-

phate was placed. The groups were subdivided into 5 periods (P15 = 15 days, P30 = 30 days, P45 = 45 days, P60 = 60 days, P75 = 75 days) for evaluating x-ray and histological aspects of the osteotomy site (surgical fracture) aiming to check local bone union process. X-ray studies showed that G2 developed a faster repair process in all observation periods when compared to G1. This fact was confirmed by histological evaluation. We conclude that the inorganic bone graft may be routinely used in orthopaedic surgery, providing an early bone healing.

Keywords: *Hydroxyapatite; Rabbit; Radiology; Histology.*

INTRODUCTION

The purpose of treating a fracture is to obtain a fast bone union, preserving the normal function of joints and surrounding soft tissues⁽¹⁾. A fracture repair involves a sequence of cellular events that evolve, since the very aggression, to hematoma formation, the beginning of a plastic callus, as well as its organization and remodeling. Some fractures' union occur appropriately after the proper use of a given stabilization method, but others result in delayed repair or non-union.

Many factors are important in order to be successful in repairing fractures; among those factors we can mention the biomechanical factors (excessive movements in the fracture core), anatomical factors (age, deficient vascularization, diastasis, infection, and others) and metabolic factors (nutrition).

It is notorious that, in order to have union, a local bone continuity is essential; the use of bone grafts, which was introduced in the beginning of the 20th Century in surgical practice, has brought subsidies to the union of comminute fractures or fractures with large defects, promoting the formation of an early callus through a process called invasive replacement associated to osteoinduction process^(2,3).

Bone grafts can be classified according to their respective origins as autogenous and heterologous; according to their type as corti-

cal, spongy or cortical-spongy, and; according to their composition as organic and inorganic⁽⁴⁾. Many times, the removal of an autogenous graft may lead to serious sequels to the patient, such as local pain, infection, in addition to extending the surgical time and increasing costs. The use of synthetic biomaterials has become increasingly important nowadays, since they are biocompatible, easy to apply and to store⁽⁵⁾.

The biological properties of the synthetic hydroxyapatite are well documented in literature, and it has been used for correcting bone defects in human beings and in other species^(6,7,8,9) with results good enough for indicating it as an alternative for bone graft in clinical practice.

This study has the objective to compare the use of an organic bone graft to an inorganic bone graft in the process of fracture repair in rabbits.

MATERIALS AND METHODS

Twenty adult, male and female New Zealand's rabbits weighting between 3.0 and 3.5 kg sourced by the UEMA Animal Lab were used and divided into 2 groups with 10 animals each being kept in separate cages and feed with balanced ration once a day and with water ad libitum. The animals were submitted to intravenous anesthesia with acepromazine 0.2% (at a dosage of 0.1 mg/kg),

Study conducted by the Maranhão State University –UEMA- in São Luís/MA in a partnership with the Orthopaedics and Traumatology Institute of Rio Grande do Norte – ITORN in Natal/RN

Correspondences to: R. Joaquim Manoel, 720, Petrópolis – Natal/RN - CEP:59012-330 - E-mail: marciodangelo@hotmail.com

1. Head of the Medical Residence Program, ITORN, Natal/RN; Member of the Brazilian Society of Knee Surgery, Doctor at ITORN
2. Student of the Veterinary Medicine Course, Maranhão State University – UEMA.
3. Precept of the Medical Residence's Group of Shoulder and Elbow, ITORN
4. Resident Doctor in the 3rd year of the Medical Residence Program, ITORN
5. Resident Doctor in the 2nd year of the Medical Residence Program, ITORN
6. Resident Doctor in the 1st year of the Medical Residence Program, ITORN

Received: 06/05/05 approved in 19/08/05

and 15 minutes later, 0.5ml/kg of an equal-portions mixture of ketamine (vetanarcol 5%) and xylazine hydrochloride (kensol 2%) were administered by intramuscular-deep via.

After the trichotomy of the anterior right limb, the skin antisepsis by rubbing with degerming polypyrrolidone diluted in saline solution was performed. All animals were submitted to a total simple surgical fracture at the diaphysis of the right radius (FIG1) removing a periosteal bone segment across its diameter with 1 cm long, by using a low-speed drill attached to a cutting disc. The same anti-inflammatory agent was used in both groups - subcutaneous ketoprofen at a dosage of 2mg/kg, once a day, during three days. The entire procedure was performed at UEMA.

In the first group (G1), fragments of organic graft were placed over the fracture core, which were removed from a dorsally addressed iliac wing, according to the technique by Bojrab⁽¹⁰⁾.

In the second group (G2), the procedure was repeated by placing an inorganic graft composed by calcium triphosphate and hydroxyapatite - Osteosynt. This graft was provided by the Orthopaedics and Traumatology Institute of Rio Grande do Norte (ITORN); the granules of the product were mixed to the clean blood (without debris or clogs) and placed at the osteotomy site, avoiding missed areas formation.

Surgical wounds were sutured with needled Nylon 3-0 and protected with dry and sterilized bandages with nitrofurazone solution, which were removed 96 hours later. Assessed limbs in both groups were immobilized with polyvinyl chloride (PVC) splints.

Each group was divided into periods, aiming a better radiographic and histological evaluation, as follows: P15= 15 days after surgery, P30= 30 days, P 45= 45 days, P60= 60 days, and P75= 75 days postoperatively.

In each period, the animals were submitted to radiographic analysis, taking into consideration time and intensity of the periosteal reaction, presence of a bone bridge and of a radiolucent line between fragments. X-rays were performed at UEMA with a radiological technique of 40 kVp (kilovolts) and 0.5 mAs (milliampere); they were subsequently sent to ITORN for analysis, where examiners were not aware of which group that X-Ray picture belonged to.

After being evaluated, both animal groups were sacrificed, with the authorization by the Committee on Ethics at UEMA, with fractured radius being removed, in all periods of the study, for histological evaluation. Bone tissue was prepared with a decalcification technique, being initially fixed in formol 10% during 12 to 24 hours, placed in decalcifying fluid (1ml of concentrated nitric acid, 99ml distilled water) with a volume 100 times big-

ger than the piece, with fluid being replaced at a daily basis, until tissue got soft, within 2 or 3 days in average.

After total decalcification, fragments were treated with 5%-sodium sulphate solution for 1 hour and rinsed in tap water for 30 minutes. They were then included in paraffin and cut at the microtome at 5 mm, being stained by the technique hematoxylin-eosin and observed at the optical microscope aiming to compare the neoformation of fibrous, cartilaginous tissues, and young bone during the bone healing process.

Descriptive and comparative evaluations were performed using radiographic and histological examinations at the end of each period for determining the best grafting method for fracture union.

RESULTS

In the sequential x-ray evaluations, it was seen that both groups concluded the bone repairing process, with the group in which the inorganic graft was placed - Group II - presenting a faster recovery and a shorter evolution time.

In the analysis of the four parameters: periosteal reaction, bone bridge formation, presence of fracture trace and bone callus formation, GII showed a better evolution regarding union process. Periosteal reaction was graded as slight (+) to moderate (++); bone bridge was evaluated by the presence of bone fragment joining fractured ends.

Table 1 represents the comparative radiological evaluation of the groups in percentages.

The histological study presented the following evolution: At P15, group-II animals presented a chondrocytes hypertrophy layer, and, in some regions, an organic matrix deposit (osteoid) was seen as fine trabecules, indicating a more advanced repair phase than GI's animals.⁽¹¹⁾ (Figures 1 and 2)

At P30, the fracture cores on GI's animals showed cartilaginous cells hyperplasia, while GII's animals showed maturation of the gaps and the beginning of lamellar organization of the secondary bone.

At P45 while there were few evidences of primary bone in GII, group I was shown to be at the beginning of endochondral ossification process. After 60 days, bone tissue in group I, although filling fracture site, was not organized in terms of a mature lamellar structure (Figure 3); in GII, signs of bone remodeling can be seen (Figure 4).

At P75 a prevalence of lamellar bone was

	Periosteal Reaction	Bone Bridge Formation	Fracture Line	Bone Callus Formation
15 days GI	75% (+); 25% (++)	12,5%	100% wide	-
15 days GII	60% (+); 40% (++)	50%	90% wide	-
30 days GI	50% (+); 50% (++)	83..3%	16.6% reduced	-
30 days GII	50% (+); 37.5% (++) ; 12.5% (+++)	100%	87.5% reduced	12.5%
45 days GI	100% (+)	Formed	100% reduced	-
45 days GII	16.6% (+)	100%	50% disappearing	66.6%
60 days GI	50% (+); 50% (++)	Formed	50% disappearing	25%
60 days GII	25% (++)	-	25% of fracture union	75%
75 days GI	-	-	50% disappearing	50%
75 days GII	-	-	100% of fracture union	100%

Table 1 - Table showing radiographic occurrences at P¹; P²; P³; P⁴; P⁵.

seen with a small cartilage layer in group II, while in GI, the animals exhibited a reasonable amount of immature bone tissue (Figures 5 and 6).

DISCUSSION

The search for materials whose components could function as bone substitutes has emerged in the 1970 decade. Since then, the number of researches and studies in this field has substantially increased.

In this study, the radiographic follow-up showed that, after 15 days, bone repair process had already been started; this finding is in accordance to Piermattei and Flo⁽¹²⁾ when referring to bone grafts as a way to stimulate a fast beginning and formation of a bone bridge. However, we can see that a higher number of animals in GII presented a faster beginning of bone bridge formation; this fact can be justified by the use of a synthetic chemical substance, which, according to Franco⁽⁵⁾ allows for a fast osteogenesis and osteoconduction. Pettis et al.⁽¹³⁾, in studies on periodontal defects in humans, have found, after 30 days, results similar to those reported in this

The chart below exemplifies the radiographic evolution of the groups.

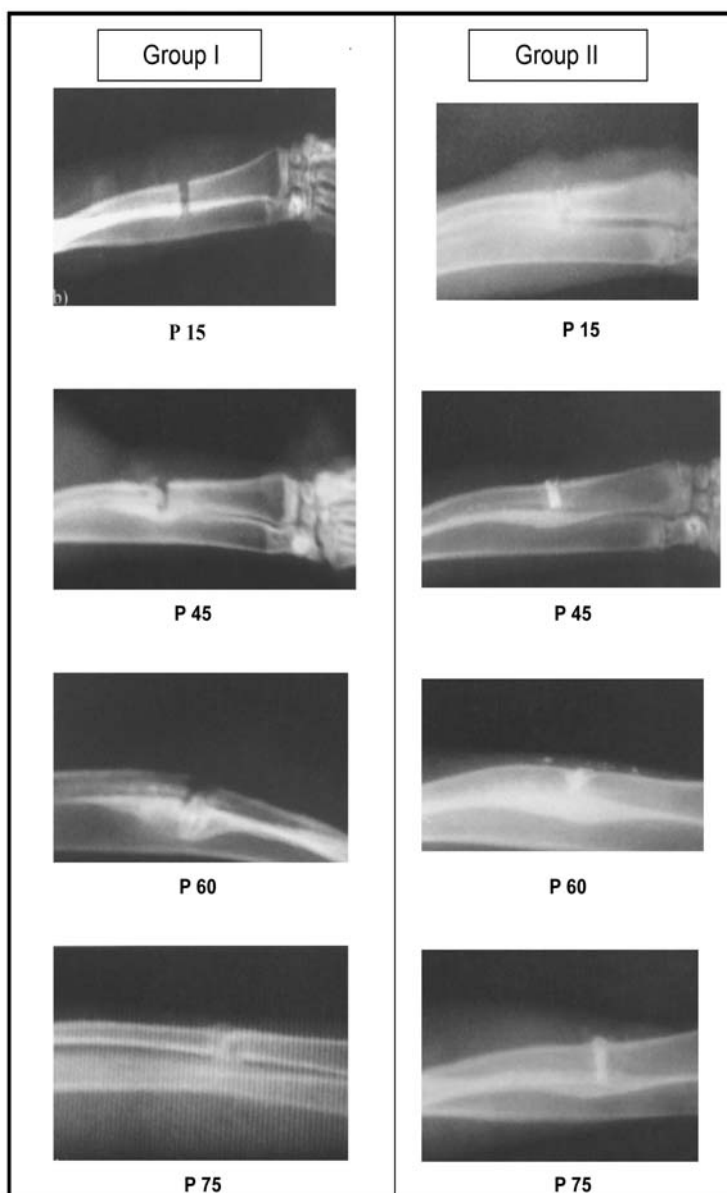


Chart 1 - Radiographic evolution between the groups. Medium-lateral X-Ray of the anterior right limb.

study, with the presence of bone bridge formation in all patients with inorganic graft.

The evolution of bone callus formation happens in the following periods: P45, P60 and P75, with a better performance at fracture cores in GII, when compared to GI. This finding is in accordance to those reported by Borges⁽¹⁴⁾ when studying the effects of hydroxyapatite in the bone repair of tibial provoked defects in dogs.

The histological events seen for GII at subsequent periods showed a better development of callus formation, and also the presence of bone remodeling process; those findings have not been evidenced in GI. This outcome seen in GII can be a result of the behavior of the chemical material used in the study, which means, according to Chang⁽¹⁵⁾, that bone formation depends on the contact of the materials with the periosteum, endosteum, and medullary cavity. The inorganic grafts showed a marked bone growth in the process of fracture repair presenting bone tissue loss. However, it is important to emphasize that osteoprogenitor cells and inductive factors are essentially responsible for a good bone repair process course.

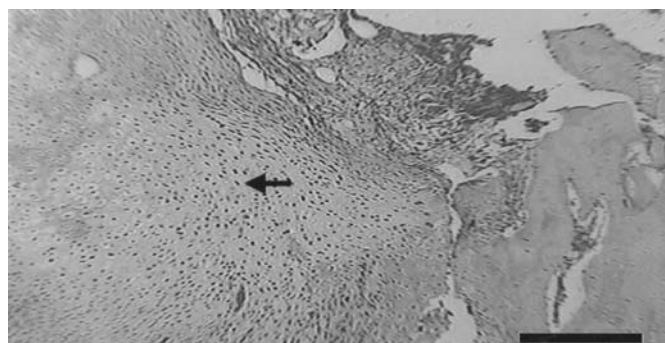


Figure 1 - Photomicrography of the fracture site, animal from group I (15 days). Cartilaginous tissue formation (arrow) is evidenced with absence of chondrocytes hypertrophy. Hematoxilín- Eosin (20 Mm)

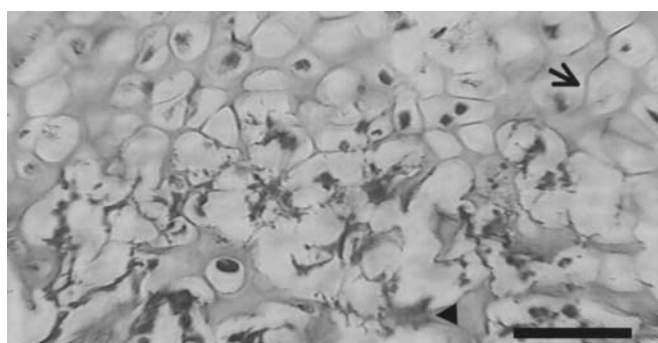


Figure 2 - Photomicrography of the fracture site, animal from group II, chondrocytes hypertrophy (arrow) and osteoid deposit (arrow end). Hematoxilín- Eosin (20 Mm)

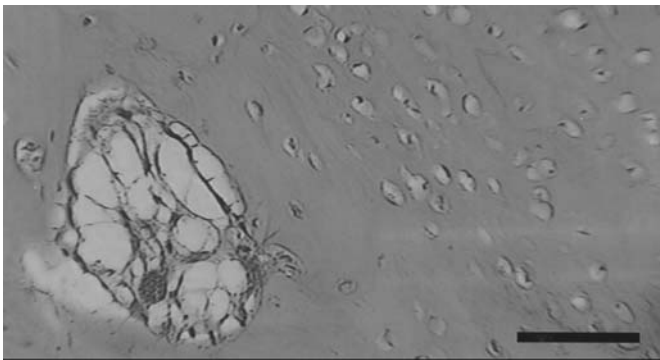


Figure 3 - Photomicrography of the fracture site, animal from group I (60 days), prevalence of primary bone. Hematoxilín- Eosín (5 Mm).

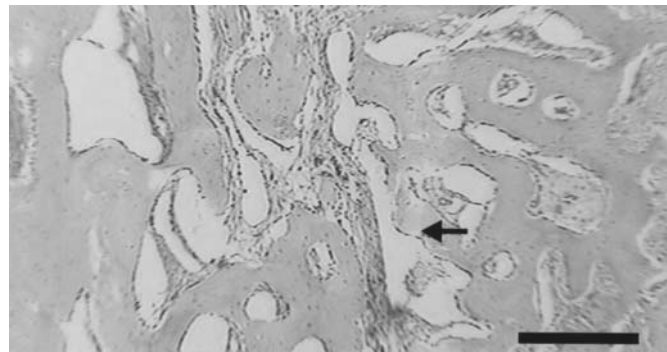


Figure 4 - Photomicrography of the fracture site, animal from group I (60 days): fracture union, lamellar spongy bone (arrow). Hematoxilín- Eosín (5 Mm)

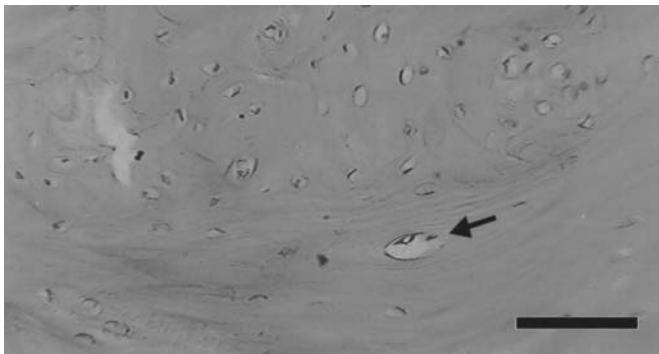


Figure 5 - Photomicrography of the fracture site, animal from group I (75 days), prevalence of primary bone at central region. Peripherally, osteon formation is seen (arrow). Hematoxilín- Eosín (5 Mm).




Figure 6 - Photomicrography of the fracture site, animal from group II (75 days), lamellar bone formation, with evident cementation lines (arrow). Hematoxilín- Eosín (5 Mm).

CONCLUSIONS

By the present study, we can conclude that the inorganic graft stimulates the early beginning of bone repair process in rabbits when compared to the organic graft, and the radiographic and

histological findings show a better evolution of the bone callus formation with the use of an inorganic graft.

The human application of the inorganic graft in the orthopaedic practice for repairing fractures needs to be further studied, but this can be a feasible alternative in the future.

REFERENCES

1. Mclain DL, Brown SG. Fixation of radius and ulna fractures in the immature dog and cats. Review of popular techniques and a report of eight case using plate fixation. *Vet Surg* 1982; 11:140-5.
2. Remedios A. Bone and bone healing. *Vet Clin North Am Small Anim Pract* 1999; 29:1029-44.
3. Hebert S. Exame Musculoesquelético. In: Hebert S, Xavier R. *Ortopedia e traumatologia: princípios e prática*. 3a ed. Porto Alegre: Sarvier; 2003. p. 26
4. A. H. Crenshaw. *Técnicas cirúrgicas*. In: A. H. Crenshaw. *Cirurgia ortopédica de Campbell*. 8a. ed. Sao Paulo: Manole, 1996. p.13-17.
5. Franco KL, Borges APB, Vilorio MIV et al. Pure synthetic hydroxyapatite: transmitted light microscopy osteointegration aspects. *Arq Bras Med Vet Zootec* 2001; 53:1-7.
6. Arakakim M, Yamashita S, Mutaf, M. et al. Onlay silisicone and hydroxyapatite-tricalciumphosphate composite blocks interfere with nasal bone growth in rabbits. *Cleft Palate-Craniof J* 1985; 32:282-9.
7. Geesink RGT, Hoefnagels NHM. Six-year results of hydroxyapatite-coated total hip replacement. *J. Bone Joint Surg Br* 1995; 77:534-47.
8. Kveton JF, Friedman CD, Costantino PD. Indications for hydroxyapatite cement reconstruction in lateral skull base surgery. *Am J Ontol* 1995; 16:465-9.
9. Yamaguchi K, Hirano T, Yoshida G, Iwasaki K. Degradation-resistant character of synthetic hydroxyapatite blocks filled in bone defects. *Biomaterials* 1995; 16:983-5.
10. Bojrab MJ. Enxertamento osseo. In: *Técnicas atuais em cirurgia de pequenos animais*. 3a. ed. Sao Paulo: Roca, 1996. p.786-93.
11. Junqueira LC, Carneiro J. *Histologia básica: Texto/Atlas*. 10a ed. Rio de Janeiro: Guanabara, 2004. p. 185
12. Piermattei DL, Gretchen L. Enxertos osseos. In: *Manual de ortopedia e tratamento das fraturas dos pequenos animais*. 3a. ed. Sao Paulo: Manole, 1999. p.139-45.
13. Pettis GY, Kaban LB, Glowacki J. Tissue response to composite ceramic hydroxyapatite/desmineralized bone implants. *J Oral Maxillofac Surg* 1990; 48:1068-74.
14. Borges APB. O efeito da hidroxiapatita sintética na regeneração óssea do defeito provocado experimentalmente no terço proximal da tibia de caes. *Estudo clínico-cirúrgico, radiológico e histológico por microscopia de luz e microscopia eletrônica de retrodispersão [tese]*. Belo Horizonte: Escola de Veterinária da UFMG, 1998.
15. Chang YS, Oka M, Nakamura T, Gu HO. Bone remodeling around implantes ceramics. *J Biomed. Mater Res* 1996; 30:117-24.