

Experimental hip arthroscopy model in newborn cadavers

RONALDO SILVA DE OLIVEIRA¹, JOSÉ ALBERTO DIAS LEITE², RÉGIA MARIA DO SOCORRO VIDAL PATROCÍNIO³,
JUVÊNCIO OLIVEIRA ARAÚJO DE CASTRO⁴, MARIANA GONÇALVES DE SANTANA⁵

SUMMARY

The hip presents a complex topography and anatomy. Diagnostic procedures are generally not very helpful. However, direct access to the joint was made possible by the use of arthroscopy. Surgical indications for its use are becoming more frequent year after year. Usage in children is still not very common. This paper is aimed at developing an experimental model of hip arthroscopy. Damages resulting from its use in structures subjected to traction were evaluated.

Twenty newborn cadavers were used to test the feasibility of the procedure. Six fetuses were used during the pilot project for the development of a research model. The remainder fourteen

fetuses were used during the main study. Antero lateral and lateral ports were used for surgical access to the hip. Histomorphological studies of the hip structures were carried out in each case.

Lateral and antero-lateral ports offered safe access and adequate viewing of most intra-articular anatomical structures through arthroscopy. It was not possible to see all structures through just one port. Hip arthroscopy is not an easy procedure although feasible in newborn cadavers weighing more than 1700 g. No macroscopic or histological lesions were identified in fetuses submitted to traction of up to 88 N.

Keywords: Arthroscopy; Hip; Cadaver; Newborn

INTRODUCTION

The development of the arthroscope has allowed the arousal of techniques for orthopaedic surgeons to have direct access to various joints. However, concerning the hip, this is a new concept for health care providers⁽¹⁾. The hip remained as a barrier for arthroscopists, because although this is a major joint of the body, the depth of its location makes arthroscopic surgical instruments access difficult and, once inserted at the joint, they are difficult to handle, requiring an extensive learning curve⁽²⁾.

Due to the complex anatomy and topography of the hip, diagnostic procedures usually are not so helpful, even with the use of ultramodern methods. Those are not always able to identify specific pathological changes of the hips, or to give accurate information about the extension and stage of the disease. In these cases, the importance of the arthroscopic method is recognized, because it provides more detailed information about the pathology for the great majority of those cases⁽³⁾.

In teenagers, the importance of the arthroscopic method has already been recognized by some people. Some say that, through arthroscopy, much more information could be achieved than

through open surgery^(4,5). In school children, literature presents some articles mentioning this possibility, stating that arthroscopy has some advantages when compared to arthrotomies in such population, because it is a less invasive and more attractive method in modern surgery⁽⁶⁾. In pre-school children and infants, this is promising. Regarding studies on this matter, although we know that there already are attempts to create routines and specific equipment for this age group, there are no references in literature worldwide.

By seeing the hip as a feasible joint for direct visualization through arthroscopy, by allowing the documentation of the procedure through photographs or tape recording, by considering the possibility of performing procedures with therapeutic purposes, by recognizing the difficulties in ruling routines and indications for arthroscopy in infants' or pre-school children's hips, it was decided to use stillborn cadavers' hips and to perform a study on a hip arthroscopic method, addressing its effects and feasibility. The idea is to directly view the joint, making hip arthroscopy a valuable technique that could fill a huge gap in clarifying the diagnosis of this joint's lesions and to allow the treatment of pathologies preventing femoral head dislocation or mus-

Study conducted at the Orthopaedics and Traumatology Service of the Surgery Department, Federal University of Ceará.

Correspondences to: Rua Cel. Jucá 1275 ap 601, Meireles, Fortaleza – CE - CEP 60.170-320. E-mail ronkar@matrix.com.br

- 1- Substitute Professor of Orthopaedics and Traumatology of the Federal University of Ceará, member of the SBOT – Brazilian Society of Orthopaedics and Traumatology.
- 2- Associate Professor, Full Professor, Head of the Orthopaedics and Traumatology Service of the Federal University of Ceará, member of the SBOT – Brazilian Society of Orthopaedics and Traumatology.
- 3- Pathologist of the Pathology Department, Federal University of Ceará.
- 4- Doctor resident at the Orthopaedics and Traumatology Service, Federal University of Ceará.
- 5- Student at the Medical School, Federal University of Ceará, and holder of a scholarship by CNPq

Received in: 08/26/04; approved in: 12/01/04

cles and tendons sectioning, minimizing surgical injuries and allowing a faster recovery for patients, as well as counting on the esthetic advantage of not having a surgical scar. The purpose of this study was, thus, to create an experimental model for training the arthroscopic method in newborns' hips and to evaluate axial traction damages on children's hip structures during arthroscopy.

MATERIALS AND METHODS

The experimental study was performed on 20 newborn (NB) cadavers, non-formalinized, presenting morphological changes, in whom hip joint had not suffered changes by use. All cadavers came from the Maternity-School Assis Chateaubriand (MEAC), after screening made by that entity's social service, obtaining written authorization from parents for fetuses to be submitted to the study. This study was conducted in compliance with the same rules regulating research in human beings from the National Health Council – Ministry of Health and approved by the Committee on Ethics of the Medical School, Federal University of Ceará Of # 121/02 , protocol 92/02.

Fetuses were frozen and defrosted to room temperature on the day of the procedures. After defrost, the fetuses were sent to an adjacent room, outside the operating room of the University Hospital Walter Cantídio, on Saturdays or Sundays, in moments when no other surgical procedures were being performed, and, complying with those conditions, arthroscopies were performed.

The first six fetuses (A1 to A6) represented the pilot project for developing the research model, finding parameters for the execution of arthroscopic procedures. After those results, we started to conduct the main study, complying with criteria established on the pilot project, being performed a total number of fourteen procedures (B1 to B14).

In the main study, fourteen specimens were studied, being four males (28.5%) and ten females (71.5%), four caucasians (28.5%) and ten non-caucasians (71.5%). The specimen with the lightest weight was the one with 1720 g (B11) and the heaviest one with 2860 g (B14). (Table 1).

One of the hips was randomly selected for the procedure. Fetuses were positioned in dorsal decubitus on the orthopaedic table, properly adjusted to their sizes (Figure 1). A soft pad was placed to protect the perineal region. Fetuses' feet and legs were wrapped in cotton and crape up to the knee and fixed to the foot support designed to adjust NB's feet. This system was fixed to a dynamometer and the latter to the traction component. Both lower limbs (LLLL) were kept in a parallel position to the ground, abducted approximately 30° and free for rotation movements (Figure 2).

Images intensifier, GE® brand, Steno V model, was positioned so that its arm was maintained in a 'c' position, perpendi-

cularly to the ground. The surgeon and all surgical team present in the operating room wore plumb aprons and plumbed collar for protecting the thyroid before any activation of the images intensifier.

When activated, the intensifier apparatus was centralized on the hip joint and on proximal femur. A narrow needle for rachianesthesia 25Gx3^{1/2} (0.53x88mm) was introduced approximately 2 to 5 mm above trochanter major end, and guided by fluoroscopy up to the joint. 1 to 2 ml of contrast stain Telebrix® (meglumine ioxitalamate) was injected, and the arthrography was performed so that the femoral head could be viewed. By that moment, the surgeon memorized the space between femoral head and the acetabulum. Traction was initiated by turning the traction knob clockwise. The surgeon, who had the intensifier footswitch by his foot, activated the radioscope and checked if an increase in the joint space occurred. If not, traction was a little stronger, until an opening of approximately 2 mm could be achieved. At that moment, a 25G1(2.5x0.7 mm) needle was inserted, and distilled water was injected through it (2 ml) to distract the capsule. Traction was raised until an opening of approximately 6 mm could be seen.

Skin was prepared with an 11 knife blade in a location immediately above the sooner introduced needle, above and medially to the trochanter major end, installing the anterolateral port (Figure 3). Guided by fluoroscopy, the trochateter and the arthroscope jacket were introduced until the joint opening site. We tried to feel a slight, almost unnoticeable compliance, which determined the capsule advancement. Being the trochateter positioning correct under images intensifier, an optical device STORZ® 2.2-mm thick, 10 mm long, 30° angulated was introduced. The arthroscopic view of the joint was confirmed. Being correct at the arthroscope jacket cock, the infusion pump line was connected (pressure 90 mmHg and flow 70 ml/h).

Under image intensifier's view, and confirmed by arthroscopic view, the joint inventory was initiated, promoting careful maneuvers of the arthroscope and examined limb handling (inward and outward rotation), viewing hip anatomy through this port.

The same previously described steps were performed for preparing the second port. The previous port matches with the intersection of a line distally traced from the anterosuperior iliac spine and a transverse line traversing the upper edge of the trochanter major. The instrument travel in this port was directed approximately 45° cephalically and 30° to the mean line. The procedures were repeated in order to see visible anatomic structures through the port. With a rachianesthesia needle, a metallic marker was introduced (a small 2-mm fragment of other needle's chuck with the same gauge) in pulvinar, labrum and round ligament.

During the procedure, the arthroscope position was viewed by radioscope whenever new instruments were inserted in the joint.

FETUS	FW	H	PT	TT
B1	1840 g	R	88 N	68 min
B2	2070 g	L	68 N	78 min
B3	2460 g	R	68 N	87 min
B4	2020 g	R	68 N	57 min
B5	1730 g	R	88 N	59 min
B6	1810 g	L	88 N	71 min
B7	2180 g	R	78 N	55 min
B8	2140 g	L	68 N	77 min
B9	1820 g	L	78 N	81 min
B10	2330 g	L	68 N	62 min
B11	1720 g	L	78 N	79 min
B12	1960 g	R	68 N	69 min
B13.	2210 g	R	68 N	72 min
B14	2860 g	R	68 N	72 min

FW=Fetus Weight H= Hip side studied PT= traction in Newtons TT= Traction time.

Table 1 - Distribution by fetus weight, examined side, applied traction, and traction time of NBs.



Figure 1- Radiotransparent adaptor on the Orthopaedic table



Figure 2- Fetus positioned on adapted Orthopaedic table.

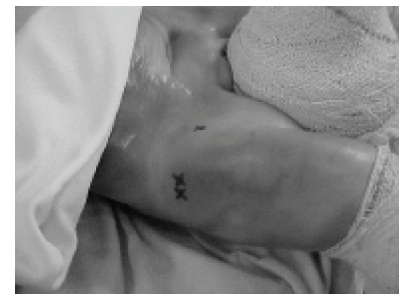

Figure 3- Fetus positioned on the Orthopaedic table, showing ports.

After the end of the procedure, by anterior incision on the hip, an arthrotomy was performed. Femoral trigone integrity was viewed. Capsule was opened and the labrum, round ligament and pulvinar were seen, and metallic markers positions match has been confirmed. Femoral head and acetabular joint were checked for macroscopic lesions identification. One fragment of each marked structure was removed and sent to pathology test. Slides with hematoxylin-eosin stain were prepared, and were analyzed by a pathologist.

After the end of the procedure, holes and incisions were sutured with cotton thread and the specimen was returned to MEAC for burial. Adjacent room and all equipment were thoroughly cleaned and sterilized.

RESULTS

It was concluded, with the pilot study, that the procedure could only be performed in bigger fetuses, because procedure was technically impossible in four fetuses weighting less than 1500 g. The use of fetuses above 1700 g was established as a standard due to the fact that in one fetus weighting 1680 g and in another, weighting 2180 g, the procedure was possible. In those specimens it was possible to identify anatomic structures through arthroscopy. It was also concluded that the procedure should be performed unilaterally. A similar traction in both LLLL was needed for the fetus to remain balanced on the orthopaedic table. In cases when the procedure was performed bilaterally, the last hip operated was submitted to a much longer traction time. For the study, it was decided that arthroscopy should only be done in one of the hips randomly selected in order to avoid lesions to the model.

In arthroscopy, femoral head presents with a hyaline cartilage covering the head, providing it with a white and bright appearance. The majority of the head is viewed, except for the inferomedial margin (Figure 4). The acetabular fossa occupies an inferomedial area of the acetabulum and is covered by fibrous-connective tissue coated by synovial tissue. Two thirds are covered with a vascularized adipose tissue with a pedunculated appearance. In the lower portion of the acetabular fossa, region seen only in two specimens, a dense coating synovial tissue covering, invading and passing behind the transverse ligament was found. The transverse ligament traverses the acetabular notch, and, in these cases, it was possible to traverse the probe behind the transverse ligament, on the lower recess of the acetabulum. Labrum presented a triangled and strong appearance at the upper margin and a thin appearance at the lower region and, in

many cases, movable at the synovial membrane limit. The labrum forms the perilabral sulcus around its margin (Figure 5). The joint capsule is covered by a bright synovial tissue, sometimes with a pink appearance. A bright hyaline cartilage extends from acetabulum periphery. The round ligament starts at the posteroinferior margin of the acetabular fossa and is inserted on the femoral head (Figure 6).

Table 1 shows the axial traction to which each fetus was submitted with corresponding time and hip side submitted to procedure. When, by the end of the arthroscopy, the arthrotomy was performed, no macroscopic lesions were found on the labrum, round ligament and pulvinar structures in none of the fetuses studied. However, lesions were seen both in arthroscopy and open view in fetuses B2 and B8. Fetus B2 presented with a iatrogenic lesion on the acetabulum as a result of instruments manipulation. In fetus B8 a lesion was found both on the acetabulum and on the femoral head.

It was verified that, through only one access, the thorough visualization of the joint was not possible, but the use of two accesses allowed the visualization of the majority of structures. In all fetuses, the round ligament, the pulvinar and labrum have been viewed and marked. The lower part of the acetabulum, where the transverse ligament is situated, was only identified in two specimens (B7 and B10). However, it was technically impossible to mark them.

All slides prepared with sections of round ligament fragments showed the presence of a dense modeled connective tissue (fibrous-connective), with fibroblasts arranged in bands (aligned with collagen fibers). No changes were found in examined slides (Figure 7). Slides prepared with labrum fragments showed the presence of cartilaginous tissue with a high number of chondrocytes in the center and the absence of vessels was noticed. In the periphery, around the cartilaginous tissue, the presence of a dense modeled connective tissue was found. All examined slides presented healthy tissue. Regarding fragments taken from pulvinar, the slides presented tissue with adipose cells nucleus with sections of dense modeled connective tissue and synovia at the periphery. All examined slides did not present changes (Figure 8).

DISCUSSION

Hip arthroscopy is becoming increasingly recognized as a valuable procedure on the treatment of hip disorders. A better understanding of the anatomy and the enhancement of surgical abilities allowed a safe performance of arthroscopic procedures in the hip⁽¹⁰⁾.

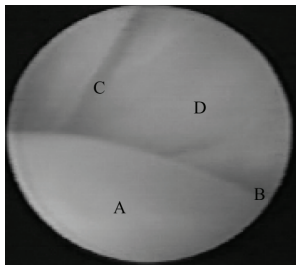


Figure 4- (A) Femoral Head (B) Round ligament (C) Acetabular labrum (D) Acetabulum

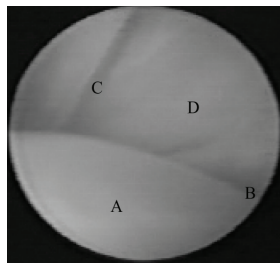


Figure 5 - (A) Joint capsule (B) Perilabral sulcus (C) Acetabular labrum

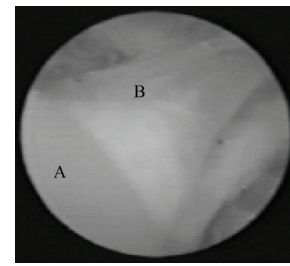


Figure 6- (A) Femoral Head (B) round ligament

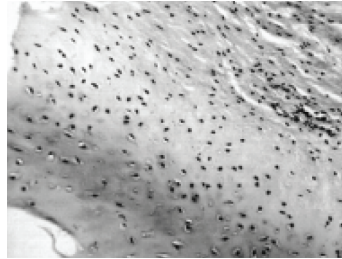


Figure 7- Figure of a labrum fragment slide

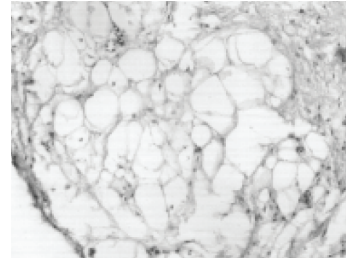


Figure 8 - Figure of a pulvinar fat slide

Hip anatomy under arthroscopic view is magnified and more extensive than that described in traditional anatomy texts. Surgeons must be familiar to the anatomy before performing procedures⁽¹³⁾. The conduction of a pilot project served to provide surgeons with the familiarity to the method and arthroscopic anatomy of the fetal hip, because no studies on the matter were found in researched literature. In children, its indication is restricted to a few diseases, but minimally invasive surgeries are growing, and even pelvic osteotomies are being performed with the aid of a video monitor, reducing the incidence of surgical injuries⁽⁹⁾. Once the pilot project was completed, it could be concluded that a minimum sample size for performing the procedures was required. Arthroscopy and convincing arthroscopic images were only possible when performed in a fetus with 1680g. Another conclusion is that the initial traction of 117.6 N could be lower. At that moment, we made the mistake of performing an extremely strong traction. This is because, at the early phase of the study, fetuses studied were too small, below 1000 g, in which cases a high traction was required to open an enough space in the joint for the arthroscopic instrument to be inserted. A minimum weight of 1700 g was established. Another conclusion drawn by the pilot project was the decision to perform procedures unilaterally. For the fetus to be balanced on the orthopaedic table, it was required to impose traction to both lower limbs of the fetuses, which led one of the hips to be submitted to stress even when it was not being operated. When further traction had to be imposed again, with more time to perform arthroscopy, such procedure could lead to undesirable lesions in the model and suggest inappropriate conclusions about the traction effect on tissues.

In the study, we concluded that, in order to view the structures, it was necessary to perform traction. Traction performed was strong, considering fetuses' weights. Byrd⁽⁹⁾, in a study evalua-

ting traction and distraction in adult hips does not provide information about patients' weights, but obtained a traction of 225 N as a standard and a distraction of 40-ml saline solution. Villar⁽³⁾, in his publication, tells the use of a traction of 245 N. Erickson⁽⁷⁾ performed a traction with 400 N and Funke⁽¹⁰⁾; states that only a traction of 725 N for a period longer than one hour leads to sciatic or pudendal nerve palsies. The performance of a higher or lower traction is ruled by the need to open an enough joint space to insert intra-articular arthroscopic instruments. No standards correlating fetus's weight to the need of a higher or lower traction were found. It is known that, for the fact that this is a cadaver-based study, the compliance status of soft tissues in each of the specimens can be changed. Thus, this compromises an accurate interpretation of the relationship between soft tissues and traction⁽¹¹⁾.

The post-delivery development of proximal femur is complex and presents biomechanical changes increasing the vulnerability to traumatic lesions or repeated stresses⁽⁴⁾. Although it is not recognized that the traction to which fetuses were submitted is proportionally above that one usually used in adults, lesions that could relate a cause to traction have not been found, either macroscopic or histological. A conclusion drawn is the well-known higher plasticity of the pelvic skeleton of children providing a better ability to stand higher axial tractions, if compared to adults'. It is believed that when performing procedures in living human beings, such high traction will not be necessary, because there will be bigger fetuses. It is worthy to highlight that in case of hips with DCDD, dislocated hips make the procedure feasible with no traction required⁽⁶⁾.

Procedure duration varied depending on how easy it was to perform the proposed methodology, presenting no significant variance. The ease to perform an arthroscopic procedure depends essentially on a perfect positioning of the patient and a perfect knowledge of the topographic anatomy of the hip. This

could only happen by increasing the casuistic, and being aware that the learning curve is long⁽¹²⁾.

Regarding the accuracy in identifying structures in arthroscopy, obstacles were directed towards the reduction on DCDD: round ligament, labrum, pulvinar and transverse ligament⁽⁶⁾. In all cases, the identification of three out of four structures investigated was achieved: the round ligament, the pulvinar, and the acetabular labrum. Regarding the transverse ligament^(4,8,13), this was seen in only two specimens. In one case, it was only seen through the lateral port, and in two cases, through the anterolateral port. The study could not reproduce other studies where transverse ligament view was possible. However, Byrd⁽⁹⁾, in his study evaluating hip arthroscopy in a supine position of the acetabulum, joint capsule and transverse ligament could not be viewed. The possibility of a greater tissue laxity has been noted in some cases is assigned to the strong traction to which the model was submitted and to the option of, during the procedure, rotating the limb (inward and outward), a factor that might have contributed to enhance visualization. This differs from the routine usually employed, which is to keep the inward rotation in 20°.

In all specimens, the marks made with the aid of a metallic marker on the three structures – round ligament, pulvinar and acetabular labrum – were confirmed by the histological description of such structures. Images also match those available in books addressing the subject⁽¹⁴⁾. It was not possible to submit the transverse ligament to the same routine, because it was technically impossible to make the marks. However, both description and arthroscopic images available in books addressing the subject matched those obtained in the study.

It was not possible to thoroughly view joint through only one port. This is also the conclusion of authors who attempted to study arthroscopic ports on hips. In all procedures, lateral and

anterolateral ports provide a good safety profile for performing the procedures, because when specimens were submitted to arthroscopy by the end of arthroscopy, no macroscopic lesions were found on neurovascular structures. This is consistent to the findings by Byrd⁽¹¹⁾, in his cadaver-based study. Most of the complications associated to arthroscopy target damages to neurovascular structures in general, due to damages caused by instruments insertion and to a bad positioning of patients. These findings do not prevent the potential of neurological lesions, especially transient palsies of the pudendal and sciatic nerves, since this is a cadaver-based study. In the studied literature, complications vary, but the average is 1.5%⁽¹⁵⁾. An important risk of a stronger traction in children is that, in the event of an excessive dislocation of the femoral head, the possibility of osteonecrosis⁽⁴⁾ is higher, a fact which was impossible to evaluate in this study.

In this study, the greatest difficulties resulted from an improper relationship between the magnitude of the material and of the specimens. Another difficulty was not having optics with 70° of inclination, being only available in bigger sizes, which made the visualization of some structures difficult.

Further studies are required in order to enlarge the knowledge about the matter, especially regarding potential neurovascular complications.

CONCLUSIONS

It can be concluded that hip arthroscopy is feasible in newborn cadavers. Appropriate fetuses for this experimental model would be those weighting more than 1700 g, and no macroscopic or histological changes were found in fetuses submitted to a traction of up to 88 N.

REFERENCES

1. Lage LA, Cavalieri RC. Artroscopia do quadril: indicações e técnicas. Rev Bras Ortop 1995; 30:555-558.
2. Dvorak M, Dunkan CP, Day B. Arthroscopic anatomy of the hip. Arthroscopy 1990; 6:264-273.
3. Villar R, Edwards D, Lomas D. Comparison of MRI and hip arthroscopy in diagnosis of disorders of the hip joint. J Bone Joint Surg Br 1994; 76 (Supplement 1):52.
4. De Angelis NA, Busconi BD. Hip arthroscopy in the pediatric population. Clin Orthop 2003; 406:60-63, 2003.
5. Holgersson S, Brattstrom H, Mogensen B, Lidgren L. Arthroscopy of the hip in juvenile chronic arthritis. J Pediatr Orthop 1981; 1:273-278, 1981.
6. Schindler A, Lechevallier JI, Rao NS, Bowen JR. Diagnostic and therapeutic arthroscopy of the hip in children and adolescents: evaluation of results. J Pediatr Orthop 1995; 15:317-321.
7. Ericksson E, Avidsson I, Avidsson H. Diagnostic and operative arthroscopy of the hip. Orthopedics 1986; 9:169-176.
8. Godoy Junior RM, Albuquerque RFM, Montenegro NB, Luzo CA, Guarniero R. Artroscopia no tratamento da displasia do desenvolvimento do quadril. Folha Ortop Traumatol 2003; 12:8-9.
9. Byrd JW. Hip Arthroscopy the supine position. Clin Sports Med 2001; 20:703-731.
10. Funke EL, Munzinger U. Complications in hip arthroscopy. Arthroscopy 1996; 12:156-159.
11. Byrd JW, Papas JN, Pedley MJ. Hip arthroscopy: an anatomic study of portal placement and relationship to the extra-articular structures. Arthroscopy 1995; 11:418-423.
12. Glick JM. Hip Arthroscopy. The lateral approach. Clin Sports Med 2001; 20: 733-747.
13. Keene GS, Villar RN. Arthroscopy anatomy of the hip: an in vivo study. Arthroscopy 1994; 10:392-399.
14. Vegue JB. Atlas de histología y organografía microscópica. Madrid: Panamericana; 1998. p.24-39
15. Griffin DR, Villar RN. Complications of arthroscopy of the hip. J Bone Joint Surgery Br 1999; 81:604-606.